

# Onyx Embolization in IA Endoleak to Prevent Rupture After Aortic Repair With the Nellix System

Tal M Hörer MD PhD

*Department of Cardiothoracic and Vascular Surgery, Life Science Faculty, Örebro University Hospital and Örebro University, Sweden*

---

An endoleak after endovascular aorta repair with the Nellix® system is potentially at high risk of rupture. As Nellix is a relatively new system with two parallel grafts, there are very few options for proximal extension of the graft as an endoleak treatment.

We describe in these photos the use of the Onyx® liquid embolization agent for treatment of a type IA endoleak in two elective Nellix cases in our institute, preventing rupture and following instructions for use, with good results at 30 days and 1 year follow up. The endoleak was treated directly peri-operatively in one case and after 30-days control in the other case.

The Onyx embolization agent can be used for other bleeders and has the advantage of being independent of the coagulation status as well as being used downstream in the vascular tree. Figure 1 shows a proximal (IA) endoleak (endoleak, black arrow; left renal artery, red arrow). Figure 2 shows a Bernstein 4Fr catheter (red arrow) in the aneurysm and Onyx embolization of the endoleak (white arrow) (usually via a micro-catheter). Figure 3 shows the completion angiography with no endoleak (red arrow) with the Bernstein catheter in place (white arrow). Figure 4 shows 1-year control after embolization with Onyx (black arrow) and no endoleak on computed tomography or contrast-enhanced ultrasound.

**Keywords:** *Embolization; Onyx; Nellix; Endovascular Aorta Repair; Endoleak*

Received: 21 October 2017; Accepted: 22 December 2017

---

---

**Corresponding author:**

Tal M Hörer MD PhD, Department of Cardiothoracic and Vascular Surgery, Life Science Faculty, Örebro University Hospital and Örebro University, Sweden.

Email: tal.horer@regionorebrolan.se

© 2018 CC BY 4.0 – in cooperation with Depts. of Cardiothoracic/ Vascular Surgery, General Surgery and Anesthesia, Örebro University Hospital and Örebro University, Sweden

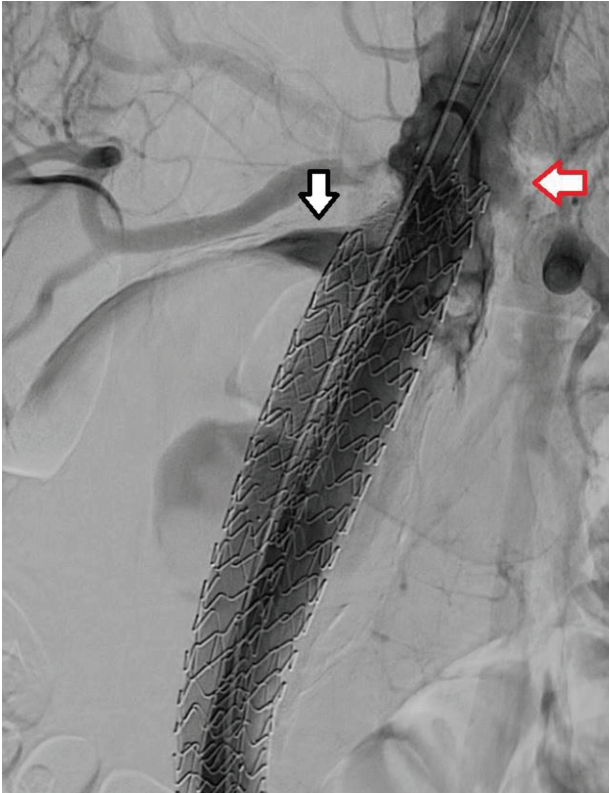


Figure 1

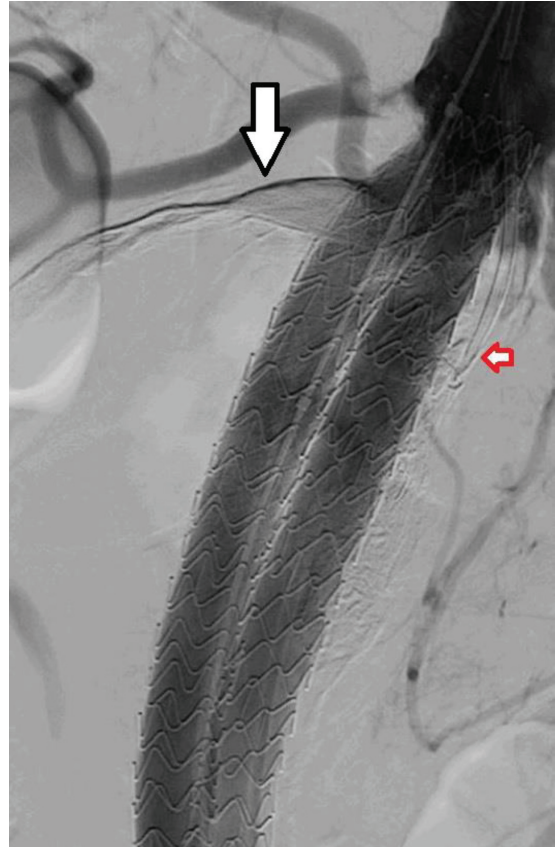


Figure 3

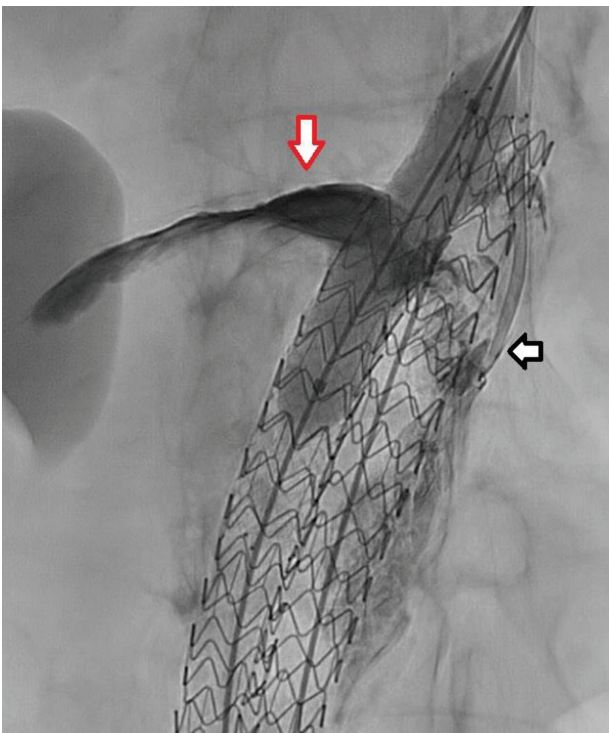


Figure 2

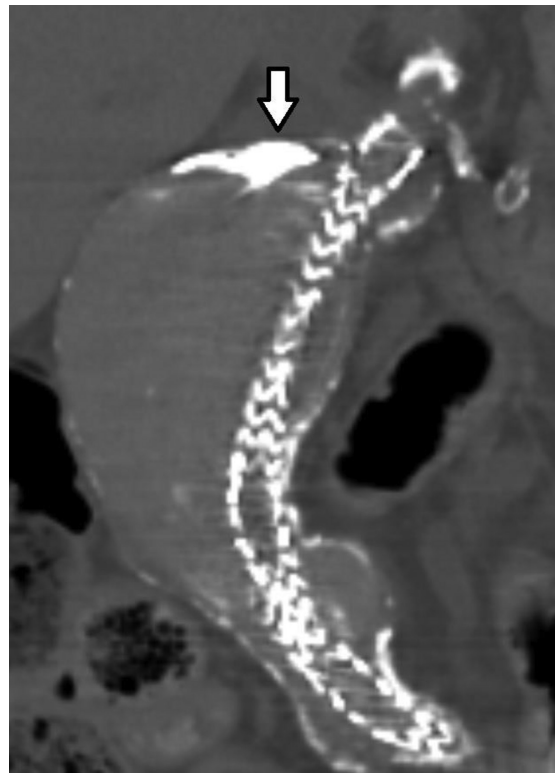


Figure 4