

# Endovascular Snaring of a Foreign Body

Daniel Mauritzson

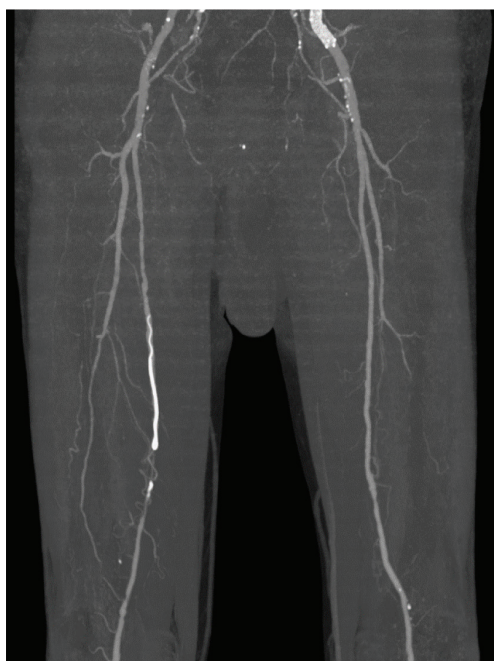Department of Cardiothoracic and Vascular Surgery, Örebro University Hospital, Sweden

**Keyword:** Endovascular Techniques

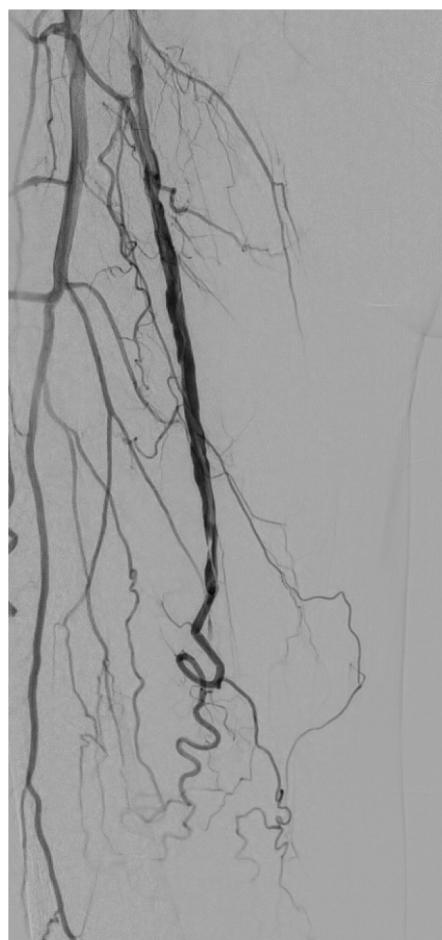Received: 24 January 2024; Accepted: 31 January 2024

We present the case of a 79-year-old patient with critical ischemia who underwent percutaneous transluminal angioplasty (PTA) in his left external iliac artery with stent placement, as well as PTA in the superficial femoral artery (SFA) using crossover access through a retrograde puncture in his right femoral artery. At postoperative follow-up the patient complained of exertion-induced pain in his right lower leg and was referred for a computer

tomography angiography (CTA). CTA revealed a foreign body resembling the remnant of a guide wire in the mid-section of the SFA (Figure 1). To retrieve the foreign body we used an endovascular approach with a snare (AndraTec Exeter Snare ES-25) to catch the foreign body, which was then easily extracted through the 6 French introducer used for access via an antegrade puncture in the patient's right femoral artery (Figures 2–6).



**Figure 1** CTA showing the foreign body in the midsection of the SFA.



**Figure 2** Angiography of the SFA with the foreign body.

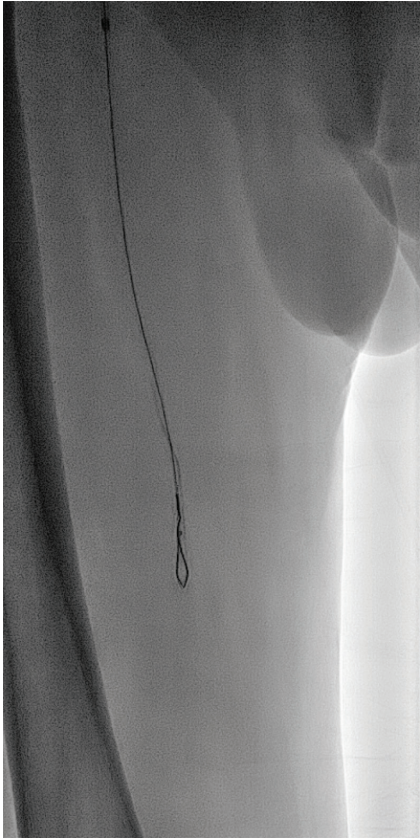
**Corresponding author:**

Daniel Mauritzson, Department of Surgery, Örebro University Hospital, Sweden.

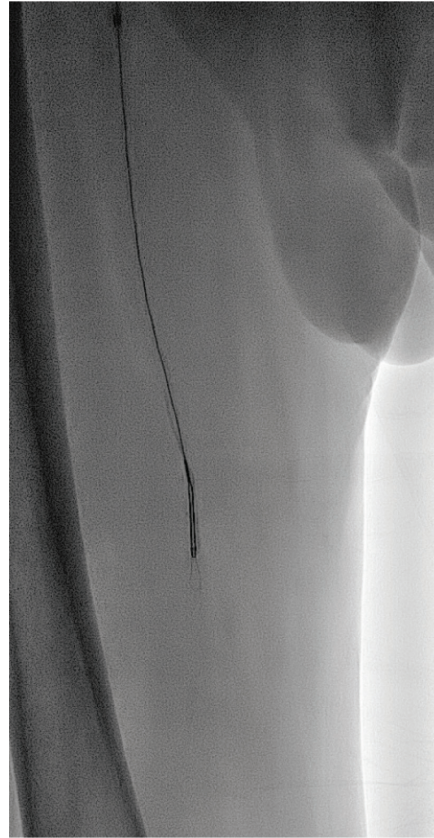
Email: [daniel.mauritzson@regionorebrolan.se](mailto:daniel.mauritzson@regionorebrolan.se)

© 2024 The Author(s)

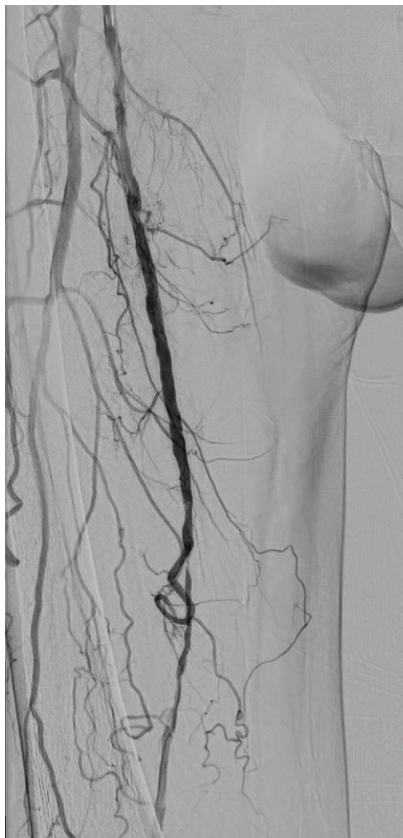This is an open access article published under the terms of the Creative Commons Attribution License (CC BY 4.0), which permits use, distribution and reproduction in any medium, provided the original work is properly cited.



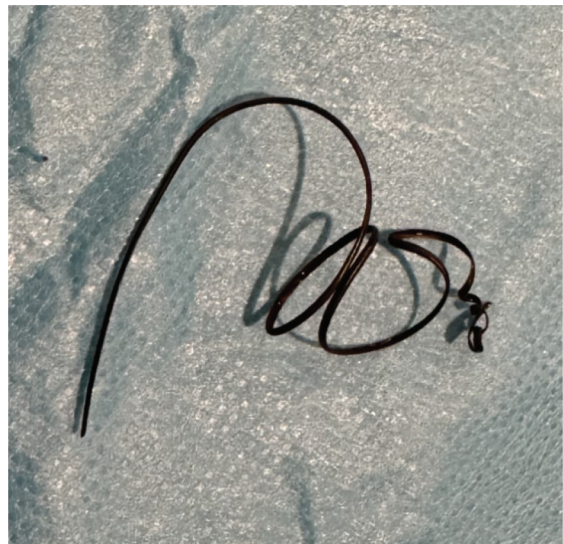*Figure 3* The snare advanced distal of the foreign body.



*Figure 4* Snaring of the foreign body.



*Figure 5* Final angiography after extraction of the foreign body.



*Figure 6* The extracted foreign body.

#### **Ethics Statement**

- (1) All the authors mentioned in the manuscript have agreed to authorship, read and approved the manuscript, and given consent for submission and subsequent publication of the manuscript.

(2) The authors declare that they have read and abided by the JEVTM statement of ethical standards including rules of informed consent and ethical committee approval as stated in the article.

**Conflicts of Interest**

The author declares that they have no conflicts of interest.

**Funding**

The author received no financial support for the research, authorship, and/or publication of this article.