

SVENSKA INSTITUTEN I ATHEN OCH ROM  
INSTITUTUM ATHENIENSE ATQUE INSTITUTUM ROMANUM REGNI SUECIAE

---

# Opuscula

Annual of the Swedish Institutes at Athens and Rome

12  
2019

STOCKHOLM

#### EDITORIAL COMMITTEE

Prof. Gunnel Ekroth, Uppsala, Chairman  
Prof. Arne Jönsson, Lund, Vice-chairman  
Mrs Kristina Björkstén Jersenius, Stockholm, Treasurer  
Dr Susanne Berndt, Stockholm, Secretary  
Dr David Westberg, Uppsala  
Dr Sabrina Norlander-Eliasson, Stockholm  
Prof. Peter M. Fischer, Göteborg  
Prof. Anne-Marie Leander Touati, Lund  
Dr Lena Sjögren, Stockholm  
Dr Lewis Webb, Göteborg  
Dr Jenny Wallensten, Athens  
Dr Ulf R. Hansson, Rome

#### EDITOR

Dr Julia Habetzeder  
Department of Archaeology and Classical Studies  
Stockholm University  
SE-106 91 Stockholm  
editor@ecsi.se

#### SECRETARY'S ADDRESS

Department of Archaeology and Classical Studies  
Stockholm University  
SE-106 91 Stockholm  
secretary@ecsi.se

#### DISTRIBUTOR

eddy.se ab  
Box 1310  
SE-621 24 Visby

For general information, see [www.ecsi.se](http://www.ecsi.se)  
For subscriptions, prices and delivery, see <http://ecsi.bokorder.se>  
Published with the aid of a grant from The Swedish Research Council (2017-01912)  
The English text was revised by Rebecca Montague, Hindon, Salisbury, UK

*Opuscula* is a peer reviewed journal. Contributions to *Opuscula* should be sent to the Secretary of the Editorial Committee before 1 November every year. Contributors are requested to include an abstract summarizing the main points and principal conclusions of their article. For style of references to be adopted, see [www.ecsi.se](http://www.ecsi.se). Books for review should be sent to the Secretary of the Editorial Committee.

ISSN 2000-0898  
ISBN 978-91-977799-1-3  
© Svenska Institutet i Athen and Svenska Institutet i Rom  
Printed by TMG STHLM, Sweden 2019  
Cover illustrations from Ingvarsson *et al.* in this volume, p. 23.

# Bioarchaeological field analysis of human remains from the mass graves at Phaleron, Greece

With an introduction by Stella Chryssoulaki and an appendix by Anna Linderholm, Anna Kjellström, Vendela Kempe Lagerholm, and Maja Krzewińska

## Abstract

In 2016, archaeological excavations undertaken by the Ephorate of Antiquities of West Attica, Piraeus and Islands 3.8 km south-west of Athens, Greece, revealed mass burials of 79 skeletons in three rows. The burials are dated to the 7th century BC. The anthropological field documentation was undertaken by The Swedish Institute of Athens, and followed established bioarchaeological protocols regarding taphonomic processes, age, sex, injuries, and pathological changes. The descriptions and interpretations should be regarded as preliminary field observations. A majority of the individuals were young adult or juvenile males, most of them without signs of active disease and with a generally good oral health status, but with corroded iron shackles around their wrists. Cause of death could not be determined although extensive and likely *perimortem* fractures were observed. The only object related to injury and/or possible cause of death was an arrowhead found in the chest of one of the skeletons. Why and where the individuals were killed is a matter of conjecture; the observations from the field documentation neither validate, nor disprove the hypothesis that these individuals were captives and victims of the so-called “Cylonian conspiracy” in the 7th century BC.\*

---

\* *Acknowledgements:* We are grateful to Dr Stella Chryssoulaki, ephor at the Ephorate of Antiquities of West Attica, Piraeus and Islands for inviting the Swedish Institute at Athens (SIA) to conduct a field documentation of the skeletons in the mass graves at Phaleron. Two Swedish foundations provided the necessary funding for the anthropological field documentation: the Swedish Foundation for Humanities and Social Sciences (Riksbankens Jubileumsfond, project no. INT16-1143:1) and the Royal Swedish Academy of Letters (Kungl. Vitterhetsakademien); SIA provided additional funding for the field documentation and Gustavianum—Uppsala University Museum provided additional funding for the report. Sincere thanks to Dr Arto Penttinen, former director at SIA for inviting us, swiftly arranging the necessary funding needed for this work and for his immense support during the whole project. Many thanks to Dr Jenny Wallensten, current director at SIA for her commitment and support during the implementation and completion of the project. Research engineer Stefan Lindgren and Victor Lundström, Humanities Laboratory, Lund University made the 3D model with additional funding from SIA. Dr Anna Kjellström and Dr Maja Krzewińska, Stockholm University, were responsible for the sampling (aDNA, strontium, and 14C) funded by the Atlas Project (through Prof. Mattias Jakobsson) which will be shared with the Center for Bioarchaeo-

*Keywords:* Phaleron, Greece, Archaic, mass graves, osteology

<https://doi.org/10.30549/opathrom-12-02>

## Introduction

By Stella Chryssoulaki, ephor at the Ephorate of Antiquities of West Attica, Piraeus and Islands

Death marks the final change in a person's condition, since it interrupts the thread of life and stops time and its flow for the family. Thus, death affects the society in which he/she was integrated. The burial process is a social act of the living members of a society undertaken to overthrow the idea of death and to deal with the fear that it causes. The Phaleron cemetery does not deviate from typical Archaic cemeteries, but it could be characterized as a more thorough image of Attic society in

---

logical Research at the School of Human Evolution and Social Change of Arizona State University and the Malcolm H. Wiener Laboratory for Archaeological Science at the American School of Classical Studies in Athens. We thank the team of the Phaleron Bioarchaeological Project, especially Prof. Jane Buikstra, Center for Bioarchaeological Research, Arizona State University and Dr Panagiotis Karkanas, director of the Wiener Laboratory, for their excellent collaboration and advice. We are particularly grateful for the assistance given by the archaeologists Sevos Agouras, Ioannis Pappas, and Nikos Tsanteikidis, and the conservators Panayota Gioni, Tatiana Panagopoulou, Paraskevi Peteinatu, and Panagiotis Simotas. Thanks to the illustrator Konstantina Deli for all the plans, and to Ioannis Asvestas for the photographs. Thanks to the workers at the Phaleron excavation for sharing their expertise and for the stimulating discussions during coffee breaks. For discussions and valuable comments on the text, special thanks to Dr Erika Weiberg, Dr Anna Kjellström, Dr Lars Sundström, Hans Liss, Dr Brita Alroth, and Dr Anders Sundström. We also thank the reviewers for their helpful comments and suggestions that greatly improved the manuscript. Many thanks to the editor Julia Habetzeder, and to Rebecca Montague for all their efforts in a thorough and professional proofreading and their constructive comments on the final draft.

Table 1. The percentage of burial types in relation to total number of burials excavated.

Type	Number	Percentage
Pit graves	961 (778 single graves, 183 individuals in mass graves)	53.43% (43.82% in single graves, 10.17% in mass graves)
Pot burials	612	34.02%
Cist graves	63	3.50%
Funeral pyres	119	6.61%
<i>Larnakes</i>	17	0.94%
Animal burials	18	1.00%
Tile-graves	3	0.16%
Secondary cremations	3	0.16%
Wooden coffin	1	0.05%

the Archaic era. The Phaleron cemetery includes all kinds of burials: individual burials, as well as mass burials with traces of violence. The excavation of a considerable number of deviant burials at Phaleron will fill a gap in archaeological research into the issue of Archaic society's behaviour towards burials that diverge from the norm.

## RESEARCH HISTORY

The history of the discovery of the Phaleron cemetery begins in the late 19th century, when a number of recently found vases from the area were sold to the British Museum.<sup>1</sup> In 1911, a research excavation was carried out by the Archaeological Service under the direction of Konstantinos Kourouniotis.<sup>2</sup> A few years later, in 1915, as a result of the Phaleron Delta area redevelopment project, rescue excavations had to be carried out, directed by Stratis Pelekidis.<sup>3</sup> The construction of the racetrack in 1925 formed a way of protecting the rest of the cemetery since the area around the cemetery was declared public land and thus became shielded from any construction work until 2012, when the building of the Stavros Niarchos Foundation Cultural Centre (SNFCC) began. In this context, the Ephorate of Antiquities of West Attica, Piraeus and Islands started conducting rescue excavations, which were carried on until 2016. Since then, the excavations have been funded by the Ministry of Culture.

## LOCATION

It is commonly known that during the period of the 8th to the 6th century BC the greater area of Phaleron Bay lay outside of the boundaries and the walls of Athens. Phaleron Bay was one

of the major naturally formed seaports in Attica, a fact that can be deduced by the construction of the Phaleric Wall in 459–456 BC by Kimon.<sup>4</sup>

The cemetery occupies a large part of the coastal zone of the ancient Phaleron Bay and its use extended from the 8th to 4th century BC. It has not been yet ascertained whether it was used by residents of Athens or residents of settlements from the Phaleron district itself. Nevertheless, the lack of residential remains in the surrounding Phaleron area in combination with the gradual establishment of Athenian cemeteries outside the city boundaries at the end of the 8th–beginning of the 7th century BC<sup>5</sup> strongly suggests that it was used by the inhabitants of Athens who, having frequent and easy access, could choose the southern extremity of Attic territory as a cemetery.

Today, the cemetery is located in the eastern part of the Kallithea Municipal Sports and Leisure Park and extends across a sandy strip heading south-eastward and north-westward up to at least the western boundary of the modern Syngrou Avenue (*Fig. 1*). The cemetery's width is estimated to 200 m. Recently, during the excavations for the construction of the underground coastal boulevard, a pit burial was found just 317 metres south-east of the discovered easternmost part of the cemetery. The identification of this individual pit burial may indicate the continuation of the cemetery, but its limits are not securely documented. If more burials were discovered during the construction work, then the spatial extent of the cemetery could occupy the entire eastern part of the ancient Phaleron Bay.

## THE CEMETERY

The excavated part of the cemetery yielded 1,797 burials,<sup>6</sup> spanning over a period of four centuries (8th–4th century BC), but it was in use mainly during the Archaic period (*Table 1*). Pit graves represent the most common type of burials, then follow pot burials, funeral pyres, cist graves, *larnakes*, animal burials, secondary cremations, tile graves, and one burial in a wooden coffin (*Fig. 2*). All burials were found below the same layer which is located at the current sea level and reaches up to 1.20 mbsl in depth.

The burials do not follow a particular orientation. No roads arriving to or paths crossing the cemetery were identified, while overlapping burials were a recurrent occurrence. The bigger part of the excavated cemetery was dug in sandy layers (on the sandy coast) which make the traces of the pit cuts very difficult to detect.

<sup>1</sup> Smith 1884, 176; Boehlau 1887, 47.

<sup>2</sup> Kourouniotis 1911, 246–251.

<sup>3</sup> Pelekidis 1916, 13–64.

<sup>4</sup> Philippson & Kirsten 1952, 881.

<sup>5</sup> Morris 1989, 317; Dimitriadou 2012, 354.

<sup>6</sup> The number concerns the finds up to November 2017, since the excavation is still ongoing.



Fig. 1. An aerial view of the site with the ongoing excavation. The mass grave of the captives is roofed by the white shelter. Photograph: G. Asvestas/Ephorate of Antiquities of West Attica, Piraeus and Islands.

## BURIALS

The pit graves are devoid of grave goods as a rule, and mostly used for adults. In contrast, later burials (5th–4th centuries BC) usually contain vessels as offerings. There is great diversity in the positions of the dead; from various forms of supine (lying on their back)<sup>7</sup> to lateral (lying on their side) and prone (lying on their front, ie face down). Apart from the single burials, double burials are also found in supine position.

The second most common kind of burial is the pot burials. They were usually intended for the burial of newborns and small children. In many cases these burial pots consist of parts of different vessels since quite a few of them indicate the “recycling” of the materials, meaning the reuse of the broken parts of vessels that obviously would be scattered throughout the

area or vases broken for this purpose. Inside most pot burials, the offerings are usually miniature vessels and tableware vessels, *alabastra*, *pyxides*, figurines, jewellery, and amulets. On several occasions other vessels used for ritual libations during the burial can be detected outside the burial pot. A second type of child burials is the *larnax* (clay tub). In some cases big clay *louteria* are also used.

Two other common burial types are the funeral pyres and the cist graves. The pyres are classified into three categories: simple pits dug into the surrounding sand, pits formed by clay tiles or flat stones, and funeral pyres constructed by tile bricks. The cist graves consist of flat stones from the regional sedimentary rock which usually formed the four sides of the grave and in some cases were used as cover stones as well. The variety in width of these graves varies depending either on the position of the dead or on the different burial customs.

<sup>7</sup> With folded feet, hands straight down or folded on chest, etc.



*Fig. 2. Different types of burials in the same area: three pot burials, three cist-graves and one pyre (above) and a typical sector of the Phaleron cemetery (below): several pot-burials, two pit-graves and traces of one cist grave next to a pit grave. Photographs: G. Asvestas/Ephorate of Antiquities of West Attica, Piraeus and Islands.*

At the Phaleron cemetery animal burials, usually of horses, are common. One of them is a well-prepared burial of a horse buried in a pit. Remarkable examples include those of a pit grave containing an adult accompanied by a horse head, and a pit grave with an adult accompanied by a small domestic animal (piglet).

The discovery of numerous adult burials that bore traces of violent treatment sets the Phaleron cemetery apart from most known cemeteries of Archaic Greece. These deviant burials can be classified into two categories: the individual burials and the mass burials. The first category consists of burials with their arms tied behind the back with iron bonds or bonds of other perishable material as rope or leather. Several of them were in prone position, face-down in the earth and with all limbs tied, an indirect indication of torture and violent death. In some cases it was noticed that the feet of some burials were cut off from the lower limbs, maybe as a mutilation punishment before death or as a *postmortem* injury caused by sorcery practices. Many of these individuals had a stone slab as a marker, *sema*, of the burial. Such indicators were located exclusively at burials where the buried person had suffered a violent death and may have been considered as *biaiothanatoi*—i.e., a violent death.

The first case of a mass burial of *biaiothanatoi* at Phaleron was identified in 1915 when a mass grave of 18 bound convicts were found tied with iron bonds to a wooden plank, a so-called *tympanon*, i.e., they had suffered the punishment of *apotympanismos*, i.e., beating to death with cudgels.<sup>8</sup>

During the recent excavations 2015–2016 further mass burials of captives or people who suffered violent death have been identified. A typical example is the mass grave located 56.6 m west of the grave treated in the article where 16 captives, with their arms tied behind their back were buried, apparently thrown into a trench without special care.

But the most remarkable example so far is however the mass grave, found in 2016, of 79 captives buried in three trenches at the south–south-eastern part of the cemetery. They were found in the same layer which is located at the current sea level, at a depth of 0.15 masl to 1.15 mbsl.

The western row, Row 1, consists of two groups of bound individuals, 47 individuals in total. The main group includes 40 individuals in a row, most of them manacled at the wrist.<sup>9</sup> They have been laid very carefully one after the other. The second group of the row consists of eight skeletons with their

arms tied behind their backs, but without metal shackles, most of them in a lateral position with their lower limbs bent at right angles.

The middle row, Row 2, involves 16 skeletons with their arms tied behind their backs though no traces of metal bounds were found. The eastern row, Row 3, consists of 16 skeletons buried in a simple pit, with their arms tied with iron bonds around their wrists. According to their body position they were thrown in and executed on-site. A limestone slab found placed on these burials could be characterized as a *sema*.

As far as the taphonomy can offer information about the identity of the captives, we can note that they seem to have been given some rites to ease the passage to the Underworld as two libation vases were found on the corpse of the west row, Row 1. These were two *oinochoai* dated between the second third and the end of the 7th century BC.<sup>10</sup>

Furthermore, the buried men had participated in actions that can be interpreted as of violent or warlike character. In the east row, Row 3, lies a man who was wounded in his thorax by an arrowhead, not far from an armed individual with a dagger hidden against his leg. The find of the dagger seems to indicate that they were buried dressed and the knife hidden in a boot, otherwise it would certainly have been taken from its convicted owner.

The dating of this mass burial to the second half of the 7th century BC points to Athens in the beginning of an intense and at times violent political, social, and economic disorder, which affected its further development. The city became the scene of continuous civil conflicts and unrest, as the noble families fought to come to power. The lower social classes—in search of a better lot—also participated in these conflicts.<sup>11</sup> Possibly, the mass burials in Phaleron, described in the following, bear witness to these troubled times.

<sup>8</sup> Pelekidis 1916, 13–64; Keramopoulos 1923.

<sup>9</sup> During the excavation of the mass grave, a skull was found (no. 1247), which was given a temporary burial number (see *Appendix 1*). However, we cannot be sure that it belongs to the mass grave or to an earlier individual pit burial that was disturbed, because of the digging of the mass grave pit (see *Table 2* in the osteological field documentation).

<sup>10</sup> The study of pottery is conducted by Dr Anna Alexandropoulou.

<sup>11</sup> Valavanis 2010, 43; Morris 1992, 24–25; Parker 1983, 16–17.

## Introduction to the osteological field documentation

In 2016, mass burials arranged in three separate rows were revealed at the Phaleron Delta, 3.8 km south-west of Athens, Greece. The Ephorate of Piraeus, under the direction of Dr Stella Chryssoulaki uncovered the skeletons between February and mid-July 2016. The material consists of 79 skeletons; the individuals were deposited in three rows in the periphery of the large Archaic cemetery at Phaleron, in a coastal marshland/salty water context.<sup>12</sup> Most of the skeletons were laid out in Row 1 (n = 47) in the west, with 16 skeletons in Row 2 (middle row) and 16 skeletons in Row 3 (east row) (Figs. 3–7). The presence of two *oinochoi* found among the skeletons in Row 1 (the west row) dates the burials to the 7th century BC. It has been discussed whether the mass burials could be connected with the execution of the participants in a late 7th-century coup, the so-called “Cylonian conspiracy”, briefly mentioned by Herodotus, Thucydides, and Plutarch (Hdt. 5.71–5.72; Thuc. 1.126.2–1.126.12; Plut. *Sol.* 12.1–12.14).

In May, as well as a few weeks in June and July 2016, an anthropological field documentation of the skeletons was completed by Dr Anne Ingvarsson and Ylva Bäckström. The excavation is yet unpublished, although important data were available at the time of documentation: plans, photographs, notes from field diaries, and oral communication with the archaeologists, conservators, and workers provided us with background and details.

At the time of field documentation, all individuals except three skeletons in the southernmost part of the east row (Row 3) had been partially exposed through the pedestal method, i.e., the soil had been removed around the skeletons leaving the bones on soil pedestals for maximum visibility because the skeletons were not, at the time, allowed to be lifted for osteological analysis. Solid soil incrustations on excavated parts of the skeletons were common. Therefore, observations regarding age, sex, oral status, trauma, and pathologies are limited to what was possible to observe in the field. Complete examination and subsequent cleaning of the bones will be necessary before a full osteological analysis of age, sex, oral status, fractures, and pathologies can be made. The descriptions and interpretations of the findings presented in this report are limited to what was observed in the field and should thus be regarded as preliminary field observations.

Three additional skeletons were excavated between Rows 1 and 2 (nos. 1274, 1345 and 1403). According to the archaeologist, these skeletons derive from another context, and were already excavated and lifted at the time of field documenta-

tion.<sup>13</sup> They were not examined and are not included in this report.

It is unlikely that the individuals in the mass graves died from natural causes; there was little evidence of disease and a majority of the individuals were young–middle-aged males, many of them with evidence of trauma to the skull that may have been fatal. A majority of individuals had been shackled, metal clamps remaining on their wrists; some were probably bound with perishable material, according to their arm position.

## METHODS

The osteological field documentation followed established bioarchaeological protocols in order to document and preliminarily analyse the skeletons *in situ*. Observations regarding taphonomic processes, age, sex, injuries, and pathological changes were documented (see *Appendix 1*).<sup>14</sup>

Estimation of sex, age, and stature was made using standard osteological methods recommended by Jane E. Buikstra, Douglas H. Ubelaker and Don Brothwell.<sup>15</sup> Although metrics that would aid estimation of sex or stature were taken when possible, conditions in the field prevented, in most cases, precise measurements from being taken.

The anthropological field observations were registered on paper, using parts of the form developed by INFORCE, the International Forensic Centre of Excellence, and California State University, Chico: “Anthropology recording form, individual adult skeleton”.<sup>16</sup> In addition, observations on archaeo- thanatology were registered on a separate form. We used the recording form for “*anthropologie de terrain*” developed by the Villa Magna Project.<sup>17</sup>

Quantitative and qualitative observations regarding the state of preservation were made according to the three stages described in the manual on human osteological methods from ADBOU—Unit of Anthropology at the Department of Forensic Medicine, University of Southern Denmark in Odense.<sup>18</sup>

<sup>13</sup> Sevos Agouras, pers. comm. 2016.

<sup>14</sup> Following completion of the osteological field analysis, the Cultural Ministry granted permission for removal of some individuals from the site for the purpose of detailed osteological analyses under laboratory conditions. The Ephorate removed ten skeletons, which were transferred to the Wiener Laboratory in Athens for analyses by scholars at the American School at Athens (ASCSA). Skeletons removed for analysis: Row 1, nos. 1253, 1296, 1365, 1281, 1383, 1356, and 1359; Row 2, nos. 1228, and 1267; Row 3, no. 1344. Conservators from the Ephorate of Antiquities of Piraeus conserved the skeletons.

<sup>15</sup> Buikstra & Ubelaker 1994; Brothwell 1972.

<sup>16</sup> [http://www.fossilized.org/instruction/Forensic%20osteology/content/main\\_skeletal\\_recording\\_form.pdf](http://www.fossilized.org/instruction/Forensic%20osteology/content/main_skeletal_recording_form.pdf)

<sup>17</sup> Dufton & Fenwick 2012, fig. 7.

<sup>18</sup> <http://www.adbou.dk/fileadmin/adbou/manualer/humostman2015.pdf>

<sup>12</sup> Chryssoulaki forthcoming.

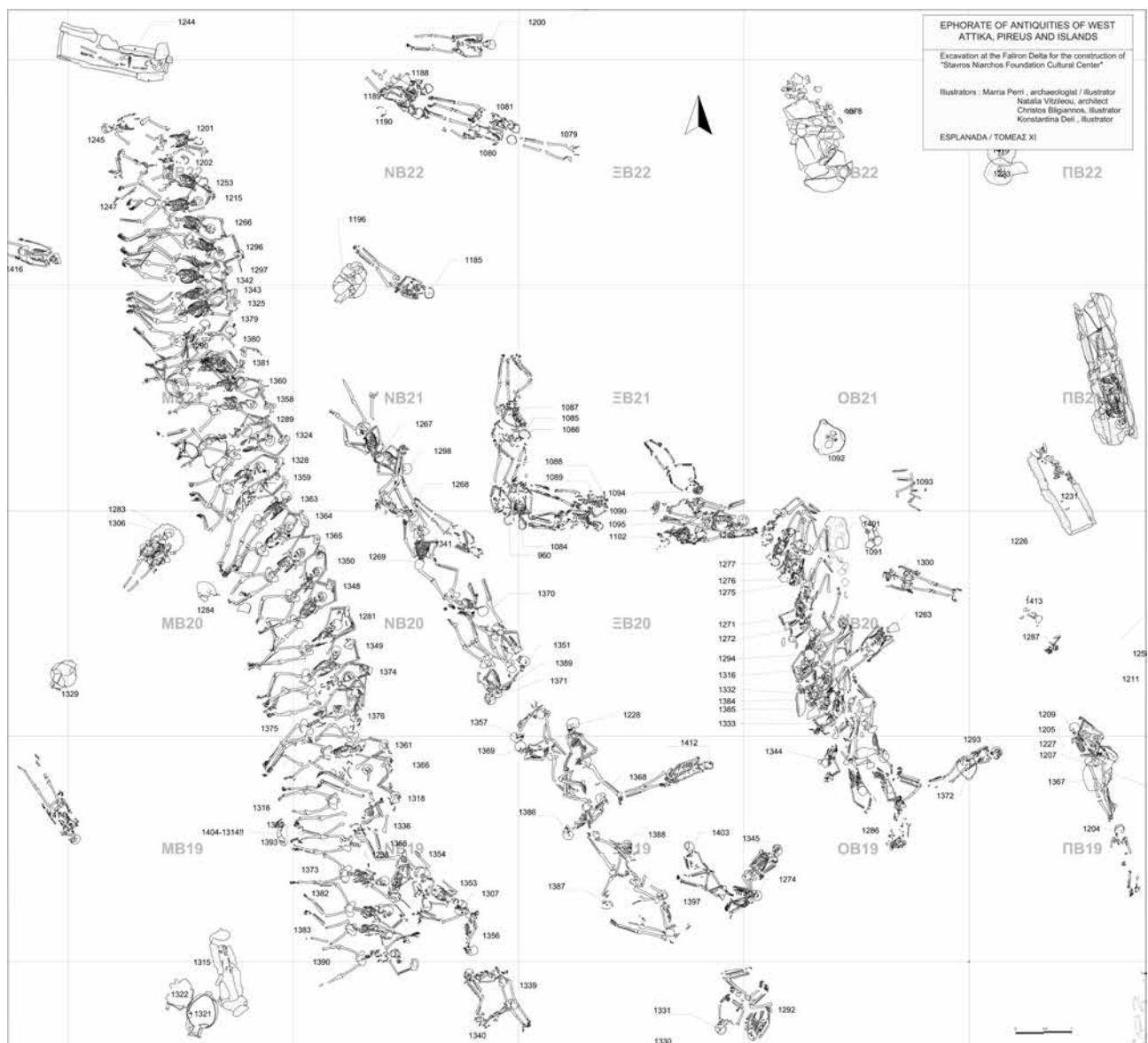


Fig 3. Overview of the area of the mass graves. The drawing includes skeletons that are not considered to be related to the mass burials presented here.

All skeletons were photographed (e.g. overviews, close-ups of teeth, injuries, and pathological changes), and loose and fragmented bones were sampled for chemical analyses.<sup>19</sup>

Further sampling for DNA analyses took place during the spring of 2017 in co-operation with two researchers from

Stockholm University (Fig. 8). Analyses of these samples are undertaken by the Archaeological Research Laboratory at Stockholm University (AFL), the Evolutionary Biology Centre at Uppsala University, and the Center for Bioarchaeological Research (CBR) of Arizona State University, and will be published as separate papers.

The AFL undertook the DNA analysis on teeth from 63 individuals, aiming at whole genome sequencing. Unfortunately, the DNA preservation was too poor to allow for DNA analyses, and not even sex determinations were possible to accomplish (Appendix 2).

<sup>19</sup> Most of the photographs were taken by Ingvarsson and Bäckström; those in Figs. 16–17, 19–22, 25, 153, and 161 were taken by Gianni Asvestas. The plans, Figs. 3–6 were made by Konstantina Deli; Stefan Lindgren and Victor Lundström made the 3D model, Fig. 10. Fig. 11 was made by the Hellenic Ministry of Culture/Ephorate of Antiquities of West Attica, Piraeus and Islands.



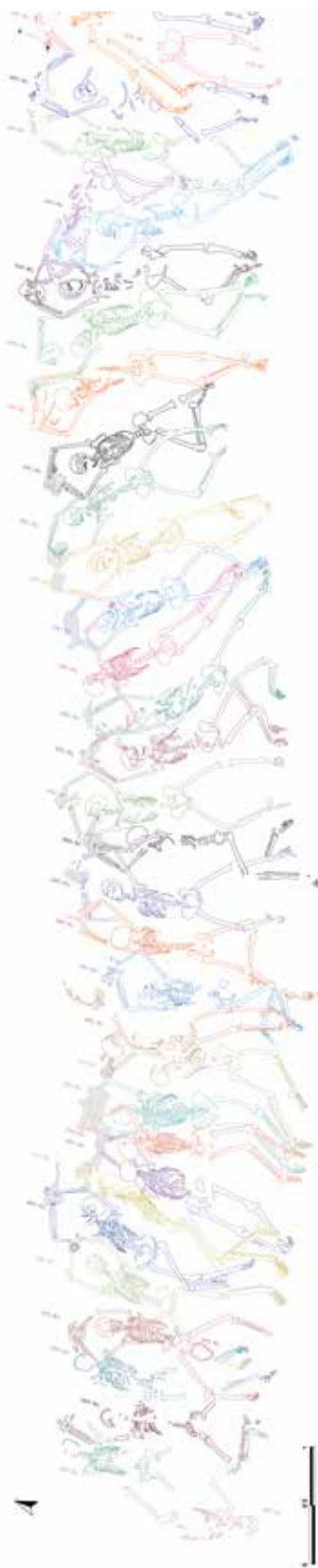

Fig. 5. Detailed overview of Row 1, the west row.

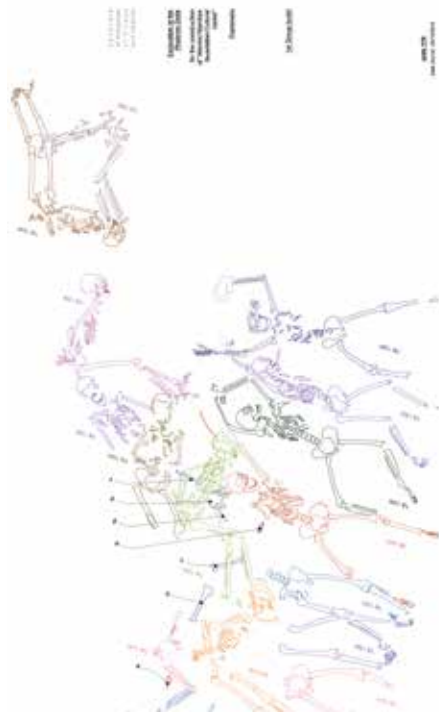


Fig. 5 continued.

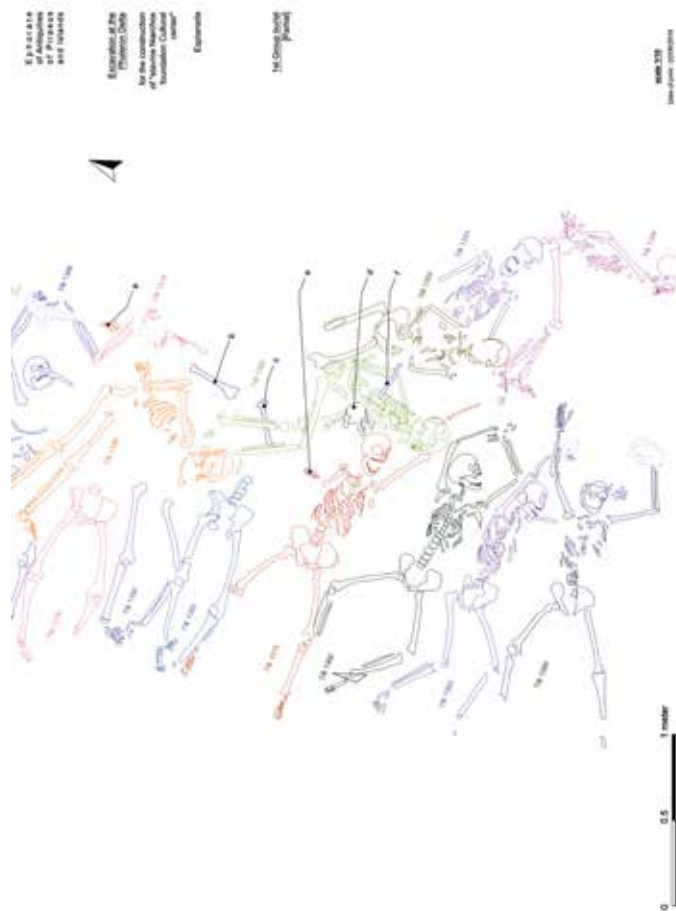


Fig. 6. Overview of the south part of Row 1.



Fig. 7. Overview of the graves at Phaleron.

A 3D-scanning of the skeletons was carried out in June 2016, by two researchers from the Humanities Laboratory at Lund University, Sweden (Figs. 9–10). The 3D model will be accessible on-line in the near future.

## Results

### TAPHONOMY AND PRESERVATION

Taphonomy is a term used to describe the natural or cultural processes affecting a once-living organism, transforming it from the biosphere to the lithosphere.<sup>20</sup> Within the field of bioarchaeology, observation of *perimortem* and *postmortem* events and processes are made to understand the socio-cultural aspects of the burial (e.g. signs of violence or of mortuary rituals) as well as how the depositional environment acted on the remains and affected assemblage patterning.<sup>21</sup>

### Spatial arrangement: position and deposition of the individuals<sup>22</sup>

All individuals were buried at a depth of *c.* -3.70 m from the modern ground surface and *c.* -0.70–1.05 m from the surface of the ancient sandy layer (Fig. 11).

#### Row 1

In Row 1, the west row, the 47 individuals were arranged side by side in a *c.* 16-m-long row aligned in a north–north-west/south–south-east direction in the western part of the cemetery. Forty of the 47 individuals in Row 1 were placed in a more or less extended position, usually supine (lying on their back) or in a lateral position (on their side); seven individuals lay in a prone position (face down). All individuals were deposited in close connection to each other, often with limbs of nearby individuals situated below or over each other with limbs intertwined.

Six individuals in the northern part of the row and six individuals in the southern part of the row were missing parts of their skeletons (Table 2, Appendix 1, Figs. 12–14).

<sup>20</sup> Lyman 2010; Knüsel & Robb 2016.

<sup>21</sup> Buikstra & Ubelaker 1994, 95, 105; Knüsel & Robb 2016.

<sup>22</sup> The skeletons were not numbered sequentially in the rows, and therefore lists of numbers in the text and in the tables that are not sequential represent the order of the skeletons as excavated.



Fig. 8. Sampling at Phaleron, Dr Anna Kjellström, Stockholm University.



Fig. 9. Work for the 3D digital model, by research engineer Stefan Lindgren and Victor Lundström, Humanities Laboratory, Lund University.




Fig. 10. Part of the 3D digital model, Humanities Laboratory, Lund University.

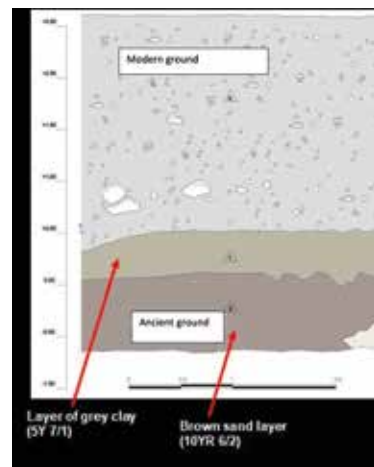


Fig. 11. The stratigraphy of the excavation at the Phaleron Delta.

Observations of a burial trench for the deceased individuals were not recorded in the excavation diaries. Hence, at the end of the osteological field documentation it was decided to make a small additional trial trench to elucidate if signs of a grave cut could be observed (Fig. 15). No clear demarcation indicating a cut could be noticed; although streaks of darker areas were noted, these were present everywhere in the sand and could not be defined as visual indications of a trench for the burials.

A majority of the skeletons in Row 1 had their arms positioned over their heads or behind their backs. Shackles were found on the wrists of 32 individuals, and for no. 1253 there were also traces of iron under the right knee (Table 3). Three individuals lying in a prone position in the northern part could have been tied together; the clamps found on the wrists of these skeletons seemed to have been interlocked at the time

of deposition.<sup>23</sup> The connection between the clamps could not be observed at the time of the field documentation since the clamps were severely corroded and partly covered in lumps of soil.

The presence of shackles could not be confirmed for 15 individuals: seven individuals were either too poorly preserved or were missing one or both limbs. The arm positions of eight individuals without observable shackles indicate that these individuals were perhaps not shackled but tied at the time of burial. In all but one case, the arms of these individuals were folded behind the back (Table 3 and figures in Appendix 1).

A majority of the individuals were oriented east–west, with the head to the east. There are however some exceptions:

<sup>23</sup> Information from the notebooks, translated to English by Sevos Agouras, pers. comm.

Table 2. Missing skeletal parts in Row 1.

Skel. no.	Missing skeletal parts	Fig. no.
1245	Left part of the postcranial skeleton, parts of the right lower arm, right lower leg and foot as well as lumbar vertebrae.	
1201	Larger part of the right arm/hand (except the proximal humerus), lower left arm (including the distal part of humerus). C. 1/3 femur diaphyses (cut?) as well as most parts of the lower legs.	
1202	Facial bones, mandible, left arm and hand, lower left leg and foot.	
1253	Facial bones and parts of the cranium, mandible, left arm and hand, right arm (except upper part of humerus) and hand, left and right femur (i.e., middle diaphysis–distal epiphyses), left tibia and fibula (proximal part–middle diaphysis).	
1247	The postcranial skeleton. There is only a partial cranium, resting on top of the forehead (foramen magnum facing up).	
1215	Right foot and lower tibia.	
1366	Mandible and left humerus.	
1318	A majority of the skeleton except parts of the lower arms, parts of left hand (two metacarpals and five phalanges partly visible) as well as the lower part of the body including legs and feet. The left foot and distal part of tibia were displaced and positioned lateral to the left tibia diaphysis, with toes pointing east.	12, 13
1392	A majority of the skeleton except legs and feet (a small bag from the excavations contained some rib fragments, possibly belonging to this individual?).	
1393	A majority of the skeleton except the lower part of a body (including legs and feet). The left foot was articulated but displaced, found between the lower legs, medial to the left tibia. The superior/medial side of metatarsals nos. 1–4 facing up and pointing east. No phalanges were present/observable.	14
1373	Proximal 1/3 of right humerus, the lower arms and hand (parts of lower scapular body displaced?).	
1354	Right lower leg and left foot.	



Fig. 12. No. 1318, southern part of Row 1. The left foot and distal part of the left tibia displaced and positioned lateral to the left tibia diaphysis.



Fig. 13. Detail of the left foot of no. 1318, positioned between the left tibia and the right tibia of no. 1392.



Fig. 14. No. 1393: left foot articulated but displaced, found between the lower legs of the individual.

Nine individuals in Row 1 (nos. 1245, 1247, 1353, 1354, 1355, 1356, 1339, 1340, and 1376) were placed in a different orientation and their positions, when observable, were usually more flexed compared with the majority of the individuals in this row. Of these, two individuals in the northern part of the trench were oriented with their heads towards the west (no.

1245 and no. 1247—only a cranium). Four individuals in the southernmost part had their heads oriented towards the south or south-east (nos. 1355, 1354, 1353, and 1356), one individual had the head oriented towards the west (no. 1399), and two individuals had their heads oriented towards the north-east (nos. 1340 and 1376).

The individuals in the northern part with missing skeletal parts were poorly preserved and fragmented, with possible animal scavenging noted on one individual (no. 1296). In the field notebooks, it is mentioned that the burials nos. 1245, 1201, 1202, 1253, and 1247 were disturbed by a pit created for the use of a modern hippodrome that was in use from 1925–2003. Thus, the fragmentation and missing skeletal parts of these individuals can probably be explained by this disturbance.

The skeletons in the southern part of the row were quite well preserved and there were no visible cut marks, gnawing, or other *postmortem* destruction observable on the bones. However, there were also some isolated bones as well as parts of an articulated hand found in the same area (southern part of Row 1). These bones were found under, or in between the individuals nos. 1318, 1336, 1355, and 1373 (on the plan, these bones were given the preliminary identifiers A–F, *Table 4*, *Fig. 6*, see also *Appendix 1*, Row 1, after no. 1297).

Although these bones and articulated elements such the hand (ID letter A) cannot be securely attributed to any of the individuals, it is likely that they belong to the some of the incomplete individuals in the same area already mentioned.

Why five individuals in the southern part of Row 1 were missing significant parts of their skeletons is more difficult to clarify. It is however likely that the burial of no. 1336 and no. 1355, that were found lying in different positions on top of, and across some of the individuals with missing skeletal parts (nos. 1318, 1392, 1393, and 1373), could have disturbed these earlier burials.

The deviant positions of skeletons nos. 1339, 1340, 1353, 1354, and 1356 as well as nos. 1336 and 1355 makes it likely that these individuals are all later depositions. The deposition of no. 1376, however, must have been made earlier than no. 1375 since the skull of this individual was situated under the arms of no. 1375; it is thus likely that a short time passed between the different depositions.

Furthermore, the deviant orientation of two individuals in the northern part of the row makes it plausible that these individuals are also later or earlier depositions. A right hand, probably belonging to the most northerly placed individual (no. 1245) was located on top of the proximal femur of no. 1202 indicating that no. 1245 was deposited later. Whether the fragmentary and isolated cranium no. 1247 (found between the legs of no. 1215) belongs to an earlier, or later deposition of a complete body that was later disturbed, or whether only a cranium was deposited, is unclear.

## Row 2

Row 2, the middle row of skeletons ( $n = 16$ ), was located *c.* 0.8–2 m east of Row 1, the west row. Eight of the individuals in the northern to middle part of the row were deposited in a more or less extended position in a north-west/south-east direction with skulls oriented towards the south/south-east.



*Fig. 15. Profile of the trial trench, north-west of Row 1.*

The other eight individuals in the middle to southern part of the row were deposited in different orientations except in one case (no. 1387), where the skull was also oriented to the south (this individual is included in *Fig. 3* but not in *Fig. 4*). Most of the other skeletons were oriented to the west, with skulls oriented towards north (no. 1386 to the west). Two individuals had been uncovered and excavated *c.* 1–2 m east of no. 1397 (nos. 1403 and 1345); these individuals had already been lifted at the time of field examination since they were regarded as unconnected to the ones deposited in the rows (*Fig. 3*).<sup>24</sup>

Nine individuals were placed in a lateral position, four individuals in a prone position, and three individuals in a supine position. Shackles were not observed, but traces of rust were found on the wrists of no. 1267. The positions of arms and wrists indicate that at least twelve individuals were tied at the wrists at the time of deposition, probably with a rope of perishable organic material. No. 1267 was missing parts of the lower legs, probably resulting from *postmortem* destruction, but the right middle diaphyses of tibiae and fibulae were quite well preserved as well as both feet.

The orientation of nos. 1267, 1298, 1268, 1269, 1370, 1351, 1389, and 1371, thus differ from nos. 1357, 1369, 1228, 1368, 1386, 1388, 1387, and 1397, which makes it possible that the individuals in the two groups were deposited at different occasions. There is also an empty space of *c.* 0.4–0.5 m between these two groups. Since the deposition of all skeletons in this row is similar in the same layer, it seems likely that the depositions were made close in time, although the length of the interval between the depositions cannot be determined.

## Row 3

Row 3, the east row of skeletons ( $n = 16$ ), was located *c.* 3.4 m east of the middle row, Row 2. A majority of the individu-

<sup>24</sup> Sevos Agouras, pers. comm. 2016.

Table 3. Individuals with shackles and associated finds. (Y = yes; N = no.)

Skel. no.	Row	Shackles	Posture	Associated finds	Remarks
1201	1	N	Supine		
1202	1	Y	Supine (inclined on the left side)		
1215	1	Y	Prone		
1245	1	N	Supine		
1247	1	N	Prone		
1253	1	N	Supine		Traces of metal under right knee.
1266	1	Y	Supine	<i>Oinochoe</i>	
1281	1	Y	Supine (skull resting on right side)		
1289	1	Y	Lateral (on right side)		Marked discolouration on the parietals near the lambdoid suture. A dark demarcated area, possibly with some iron attached on the left and right parietal, adjacent to the lambdoid suture.
1296	1	Y	Supine (skull resting on right side)		
1297	1	Y	Lateral (on right side)		
1318	1	Y	Supine		
1324	1	Y	Supine (skull resting on right side)		
1325	1	Y	Prone		
1328	1	Y	Supine (slightly on the left side)		
1336	1	N	Lateral (on left side)		
1339	1	N	Lateral (on right side)		
1340	1	N	Lateral (on right side)		
1342	1	Y	Prone		
1343	1	Y	Lateral (on left side, face almost prone)		
1348	1	Y	Supine		
1349	1	Y	Supine		
1350	1	Y	Supine (skull inclined on the right side)		
1353	1	N	Supine		
1354	1	N	Supine		
1355	1	N	Lateral (on left side)		
1356	1	N	Lateral (on left side)		
1358	1	Y	Supine		
1359	1	Y	Supine-lateral on left side (skull resting on left side)		
1360	1	Y	Prone		Marked discolouration on the right parietal, posterior.
1361	1	Y	Supine (skull resting on left side)		
1363	1	Y	Prone		
1364	1	Y	Supine		
1365	1	Y	Supine		
1366	1	Y	Supine		
1373	1	N	Supine		
1374	1	Y	Supine		
1375	1	Y	Supine (skull resting on the right side)		
1376	1	Y	Supine (skull and upper body) lateral on right lower body		
1379	1	Y	Lateral (on left side)		A dark demarcated area with reddish-brown discolouration on the left parietal.
1380	1	Y	Lateral (on left side)		A dark demarcated area on the frontal, possibly with some iron attached.
1381	1	Y	Supine (skull resting on left side)		
1382	1	N	Supine (skull inclined to the left side)		
1383	1	Y	Supine (skull resting on the left side)		
1390	1	Y	Supine		

Table 3, continued.

Skel. no.	Row	Shackles	Posture	Associated finds	Remarks
1392	1	N	Supine	<i>Oinochoe</i>	
1393	1	N	Supine		
1228	2	N	Lateral (on right side)	Ring, left IV finger.	
1267	2	?	Supine	Ring, left IV finger.	Traces of metal under the wrists.
1268	2	N	Lateral (on right side)		
1269	2	N	Supine		
1298	2	N	Supine (skull resting on left side)		
1351	2	N	Prone (skull slightly on the left)		
1357	2	N	Lateral (on right side)		
1368	2	N	Lateral (on left side)		
1369	2	N	Prone (skull slightly on the right)		
1370	2	N	Prone (skull slightly on the right)		Marked discolouration on right and left parietals.
1371	2	N	Supine (slight on left side)		
1386	2	N	Lateral (on left side)		Demarcated staining on right parietal, possibly from iron?
1387	2	N	Lateral (on left side)		
1388	2	N	Lateral (on left side)		
1389	2	N	Lateral (on left side)		
1397	2	N	Lateral (on right side)		
1271	3	Y	Supine (postcranial skeleton on the left)		
1272	3	Y	Supine (skull on left side)	Arrowhead, left thorax, near to the shoulder.	
1275	3	N	Supine (skull slightly on left side)		
1276	3	N	Lateral (on left side)		
1277	3	N	Lateral (on left side)		
1285	3	N	Lateral (on left side)		
1294	3	Y	Prone		
1316	3	Y	Lateral (on right side)		A piece of limestone directly to the S of the hands.
1332	3	Y	Supine (skull on left side)		A piece of limestone directly to the SW of the skull
1333	3	Y	Supine (skull slightly on left side)		
1344	3	Y	Prone (skull slightly on the right)	Knife, medial to the left tibia	
1384	3	Y	Supine (skull on left side)		Ceramics under the right knee.
1385	3	Y	Lateral (on right side)		A limestone slab on the lower arms.
1398	3	Y	Lateral (on right side)		A limestone slab on top of the knees.
1399	3	Y	Lateral (on left side)		
1400	3	Y	Prone		A white and weathered humerus was found c. 30 cm above the thorax

Table 4. Associated skeletal elements in Row 1.

Preliminary ID letters	Skeletal elements
A	North of/partly on top of the right ulna of no. 1318: parts of a right hand; articulated carpals (not clearly distinguishable, but their position indicate capitate, hamate, lunate, triquetrum, and pisiform), right metacarpals MCII-V (palmar side facing up) and two first phalanges possibly parts of the right hand of no. 1318?
B	East of no. 1336: a right humerus with a transverse <i>postmortem</i> crack on middle diaphysis. Distal part oriented towards north.
C	A left humerus with proximal epiphysis situated under the right lower leg of no. 1355. Epicondylar breadth 65 mm = male?
D	Between the right humerus of no. 1355 and the cranium of no. 1373, partly under the left lower leg of no. 1353 a right coxa, fragmented but complete, pubis was not observable, greater sciatic notch = 4 (male?).
E	North of the right scapula of no. 1373: a left, partly articulated hand with metacarpal II-V? and some carpals and phalanges, palmar side facing up, fingers pointing towards no. 1373 right scapula. Carpals and phalanges show transverse fractures.
F	Positioned across the left arm of no. 1355: a right radius not belonging to this individual.

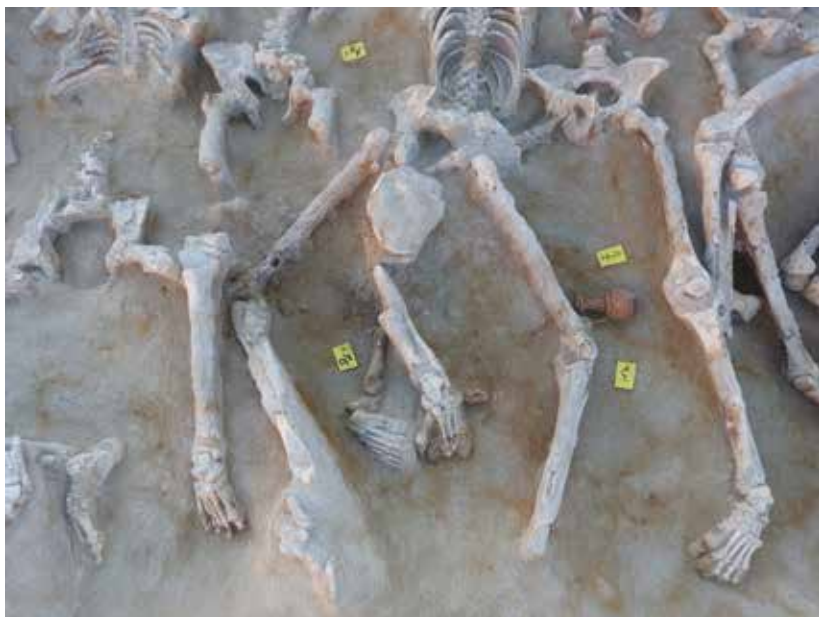

Fig. 16. No 1266, Oinochoe.

als were aligned in a south-westerly/north-easterly direction with heads to the south-west; four individuals were aligned in a north-south direction with heads to the south. Seven individuals were deposited in a lateral position, six individuals in supine position, and three individuals lay in prone positions. Shackles were observed on the wrists of twelve individuals, while the wrists of the remaining four individuals were either missing or unobservable.

The four most northerly-located individuals, nos. 1285, 1277, 1276, and 1275, have had their arms cut *postmortem*, according to the field notebooks. The reason could have been to access metal.<sup>25</sup> At the time of the osteological documentation, no. 1285 was found missing both arms and the other three individuals had only parts of one or both humeri (upper arms) preserved. The humeri of these individuals were very fragmented and no cut marks could be noticed. Therefore, it was not possible to distinguish when, or whether their arms were intentionally cut; it may be a result of post-depositional disturbance. The position of these individuals, lateral and close to each other with legs bent at the knees suggest that they fell together on the spot, as did perhaps also nos. 1271 and 1272.

#### The relation between the rows and the skeletons

The relation and period between the depositions in three rows could not be determined since there was no stratigraphic information available. Nor could it be determined how long the

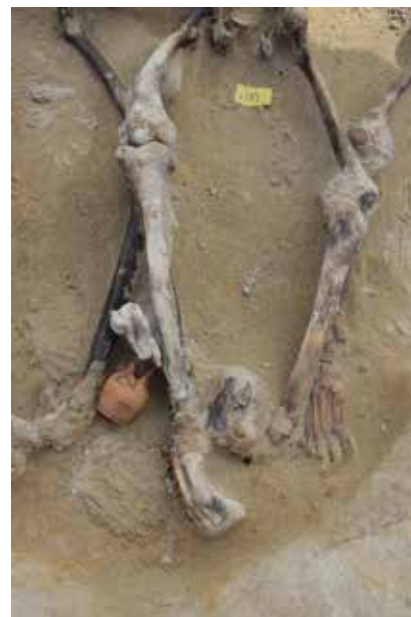

Fig. 17. Nos. 1392 and 1393, Oinochoe.

individuals were exposed between depositions. The deviant position of no. 1376 (Row 1) found partly under no. 1375 deposited according to the scheme in Row 1 (i.e., extended on the back with hands above the head) indicates that no. 1376 was deposited earlier; that there was little or almost no soil between these individuals indicates that only a short time elapsed between the depositions.

In Row 2, unlike in Row 1, none of the skeletons was found with their arms extended above their heads and shackles were not observed (only traces of metal in the wrist of one individual, no. 1267). The position of their arms and wrists indicate that their arms were nevertheless constrained; they were probably tied rather than shackled.

The positions of the individuals in Row 3 indicate that at least the four northerly individuals fell instantaneously (probably from standing position), as did probably some of the other individuals in this row. A possible scenario is that the individuals were tied to a high frame, with arms above their head and executed at the spot; how this was done is unclear.

#### Objects

Few objects were found among the skeletons in the three rows apart from the earlier-mentioned two *oinochoai* that were found in the northern and southern part of Row 1 (Figs. 16–17). However, two finger rings were found on the left fourth finger on two individuals (nos. 1228 and 1267) in Row 2 (Figs. 18–19). Furthermore, a knife was found alongside the lower left leg, medial to the left tibia on an individual (no. 1344) in Row 3 (Fig. 20); it seems likely that the knife had

<sup>25</sup> Sevos Agouras, pers. comm.



*Fig. 18. No. 1267, finger ring.*



*Fig. 19. No. 1228, finger ring.*



*Fig. 20. No. 1344, knife found medial to the left tibia.*



*Fig. 21. No. 1272, arrowhead.*



*Fig. 22. No. 1272, arrowhead after conservation.*

been attached to the leg of this individual (perhaps it could have been hidden under clothing?).

The only object related to injury and/or possible cause of death was an arrowhead found in the chest of no. 1272, in Row 3 (Figs. 21–22). The arrowhead had been removed before the osteological field observation and the rib cage of this individual was at the time severely fragmented; it could not be determined if the arrow caused, or contributed to the death of the individual. It is interesting, however, that the arrowhead was found in the chest of an individual in Row 3, who amongst other individuals in the northern part of row, may have been executed in standing position at the site (see above).

### Bone modification and surface changes

Bone colour, weathering, fragmentation, and the presence of gnawing are important clues aiding interpretations of the mortuary treatment and other taphonomic processes. In life, the skeleton is plastic and prone to changes depending on factors such as lifestyle, cultural modifications, and disease. After death, however, the skeleton continues to change due to cultural or natural processes following *postmortem* handling of the body and the burial environment.<sup>26</sup>

Since the skeletons were successively revealed between February and July 2016, the majority was exposed for a long time before the field documentation was initiated. Unfortunately, the information in the field notebooks is brief; comments on colour and state of preservation were rarely noted at the time of excavation. Furthermore, there are few photographs from the excavation of the remains, probably partly because the archaeological work was terminated on short notice.<sup>27</sup>

The field observations on taphonomic changes (recorded on paper on the form from INFORCE and California State University, Chico, “12 Postmortem trauma”) is summarized in *Table 5*.

At the time of field documentation, the colour of the skeletons ranged from white to dark brown-almost black. Although the results from soil chemistry are not yet available, it seems likely that the black patina on some of the skeletons derives from a soil rich in humic substances, roots, and decomposing plant material, and the presence of minerals (e.g. manganese), which are known to produce dark brown or black discolouration on bone.<sup>28</sup> Algae from a salt-water context may also result in dark brown or almost black patina on bone.<sup>29</sup> Bleaching of the bone surface most likely resulted from a combination of salt water (calcium carbonates) and prolonged sun exposure.<sup>30</sup>

Post-depositional staining was found on a majority of the skeletons; spotty reddish, purple, or brown-black discolourations were observed, probably resulting from minerals, plants, and fungal material in the sandy soil; streaks of reddish inclusions were found everywhere in soil. It is possible that the purple staining could derive from high levels of purple acid phosphatase (PAP) enzyme known to produce this kind of discolouration on bone<sup>31</sup> as well as staining from manganese (II) carbonate (MnCO<sub>3</sub>).<sup>32</sup> It is likely that the staining observed resulted from natural components of the soil.

Reddish staining from the corroded iron shackles was also observed on the skeletons, particularly in the area of the wrists and hands.

A majority of the skeletons were covered with a solid crust/soil matrix adhering to the bones, probably calcium carbonate concretion.<sup>33</sup> At the time of examination, the matrix was in most cases impossible to remove without damaging the bones; this made the anthropological field observations challenging.

The following changes, presented below by row, were noted (see also *Table 5*).

### Row 1

The entries in the field notebooks, as already mentioned, indicate post-depositional disturbances in the northern part of row 1. Modern excavations for a hippodrome seem to have disturbed the depositions of nos. 1245, 1201, 1202, 1253, and 1247. The observations in the notebooks were supported by observations made during the anthropological field documentation. However, no. 1215 was also found in a similarly poor condition as the skeletons already mentioned, but the field notebooks do not mention any evidence of disturbance in relation to this individual. Since all the aforementioned skeletons were uncovered first (revealed and cleaned during February–March 2016), they were exposed to changing environmental conditions for a longer period of time than those in the southern part of the row.

In general, bleaching and erosion were most commonly found in the northern part (skeleton nos. 1245–1297). Bleaching, with variable erosion, was also found on nos. 1342–1349 in the northern–middle part of the row (uncovered late March–early April 2016).

The skeletons in the southern part of the row, nos. 1361–1390 (excluding nos. 1354, 1353, 1356, 1339, and 1340 which were bleached and eroded) were largely brown/black in colour; only slight erosion and bleaching were noted on parts of these skeletons. The brownish-black discolouration was not always limited to the cortices, in some cases it seems to have penetrated into parts of cancellous tissue of the limb bones following *post-*

<sup>26</sup> Lyman 2010; Symes *et al.* 2014.

<sup>27</sup> Sevos Agouras pers. comm. 2016.

<sup>28</sup> Dupras & Schultz 2013; Borrini *et al.* 2012.

<sup>29</sup> Nawrocki *et al.* 1997, 540.

<sup>30</sup> Dupras & Schultz 2013, 336.

<sup>31</sup> Cole & Waldron 2016.

<sup>32</sup> Dupras & Schultz 2013, 325.

<sup>33</sup> Dupras & Schultz 2013, 333–334.

Table 5. Observations on taphonomy (Y = yes; N = no).

Skel. no.	Row	Animal scavenging	Bleaching	Erosion	Postmortem break	Root etching	Staining	Excavation damage
1201	1	N	Y	Y	Y	N	Y	Y
1202	1	N	Y	Y	Y	N	Y	Y
1215	1	N	Y	Y	Y	N	Y	Y
1245	1	N	Y	Y	Y	N	Y	Y
1247	1	N	Y	Y	Y	N	Y	Y
1253	1	N	Y	Y	Y	N	Y	Y
1266	1	N	Y	Y	Y	N	Y	Y
1281	1	N	Y	N	Y	N	Y	N
1289	1	N	Y	N	Y	N	Y	Y
1296	1	Y	Y	Y	Y	N	Y	Y
1297	1	N	Y	Y	Y	N	Y	Y
1318	1	N	N	N	Y	N	Y	Y
1324	1	N	Y	N	Y	N	Y	Y
1325	1	N	Y	N	Y	N	Y	Y
1328	1	N	Y	N	Y	N	Y	Y
1336	1	N	N	N	Y	N	Y	N
1339	1	N	Y	Y	Y	N	Y	Y
1340	1	N	Y	Y	Y	N	Y	Y
1342	1	N	Y	N	Y	N	Y	Y
1343	1	N	Y	N	Y	N	Y	Y
1348	1	N	Y	N	Y	N	Y	Y
1349	1	N	Y	N	Y	N	Y	Y
1350	1	N	Y	N	N	N	Y	N
1353	1	N	Y	Y	Y	N	Y	Y
1354	1	N	Y	Y	Y	N	Y	Y
1355	1	N	Y	Y	Y	N	Y	Y
1356	1	N	Y	N	Y	N	Y	Y
1358	1	N	Y	N	Y	N	Y	Y
1359	1	N	Y	N	Y	N	Y	Y
1360	1	N	Y	N	Y	N	Y	Y
1361	1	N	N	N	N	N	Y	N
1363	1	N	Y	N	Y	N	Y	N
1364	1	N	Y	Y	N	N	Y	Y
1365	1	N	Y	N	N	N	Y	Y
1366	1	N	N	N	Y	N	Y	N
1373	1	N	N	N	Y	N	Y	Y
1374	1	N	N	N	Y	N	N	N
1375	1	N	Y	N	Y	N	Y	Y
1376	1	N	N	N	Y	N	Y	N
1379	1	N	Y	N	Y	N	Y	Y

Table 5 continued.

Skel. no.	Row	Animal scavenging	Bleaching	Erosion	Postmortem break	Root etching	Staining	Excavation damage
1380	1	N	Y	Y	Y	N	Y	Y
1381	1	N	Y	Y	Y	N	Y	Y
1382	1	N	Y	N	Y	N	Y	Y
1383	1	N	N	N	Y	N	Y	Y
1390	1	N	N	N	Y	N	Y	Y
1392	1	N	N	N	N	N	Y	N
1393	1	N	N	N	Y	N	Y	Y
1228	2	N	Y	Y	Y	N	Y	Y
1267	2	N	Y	Y	Y	N	Y	Y
1268	2	N	Y	N	Y	N	Y	Y
1269	2	N	Y	Y	Y	N	Y	Y
1298	2	N	Y	Y	Y	N	Y	N
1351	2	N	Y	Y	Y	N	Y	Y
1357	2	N	Y	Y	Y	N	Y	Y
1368	2	N	Y	N	Y	N	Y	Y
1369	2	N	Y	Y	Y	N	Y	Y
1370	2	N	Y	Y	Y	N	Y	Y
1371	2	N	Y	N	Y	N	Y	Y
1386	2	N	Y	Y	Y	N	Y	Y
1387	2	N	Y	N	Y	N	Y	Y
1388	2	N	Y	N	Y	N	Y	N
1389	2	N	Y	N	Y	N	Y	Y
1397	2	N	Y	Y	Y	N	Y	N
1271	3	N	Y	Y	Y	N	Y	Y
1272	3	N	Y	Y	Y	N	Y	Y
1275	3	N	Y	Y	Y	N	Y	Y
1276	3	N	Y	Y	Y	N	Y	Y
1277	3	N	Y	Y	Y	N	Y	Y
1285	3	N	Y	Y	Y	N	Y	Y
1294	3	N	Y	Y	Y	N	Y	N
1316	3	N	Y	Y	Y	N	N	Y
1332	3	N	Y	N	Y	N	Y	N
1333	3	N	Y	Y	Y	N	Y	Y
1344	3	N	Y	Y	Y	N	Y	Y
1384	3	N	N	Y	Y	N	Y	N
1385	3	N	Y	N	Y	N	Y	Y
1398	3	N	N	N	Y	N	Y	Y
1399	3	N	N	N	Y	N	Y	Y
1400	3	N	N	N	Y	N	Y	Y



Fig. 23. No. 1392, right femur, postmortem breakage with brownish-black discoloration.



Fig. 24. No. 1296, left tibia with possible animal gnawing, puncturing, and postmortem destruction.



Fig. 25. Colour differences on skeletons in Row 3.

*mortem* breakage (Fig. 23). Furthermore, *postmortem* breaks, staining, and excavation damage were noted on the majority of these skeletons (all of them uncovered in late March 2016).

Indications of animal scavenging were rarely observed; only one skeleton in the northern part of the row shows evidence of animal gnawing and puncturing (no. 1296): left tibia (anterio-lateral distal part of diaphysis): a puncture mark and shallow surface damage on cortical bone, possibly consistent with gnawing adjacent to an area of *postmortem* destruction (Fig. 24).

## Row 2

The skeletons in Row 2, the middle row, were quite well preserved with a variable amount of staining and some bleaching especially on the skulls. All skeletons were excavated during March 2016. In the northern part of the row, the skeletons were largely brown-black in colour. No animal scavenging was noted, while erosion and excavation damage were found on a majority of the skeletons. Staining was noticed on all skeletons and *postmortem* breaks were noticed on the majority.

Table 6. Puncture marks (YA = young adult; MA = Middle adult).

Skel. no.	Row	Sex	Age	Puncture marks	Posture
1343	1	Undetermined	Adult	(1) Right parietal, lateral part, a few cm anterior of the temporal squama: a small depression with smooth to sharp margins penetrating the outer table. The inclination of the depression indicates a penetration from the inferior right side by a sharp object. Two faint concentric fracture lines are found superior to the puncture, probably not associated with it. Excavation damage (e.g. from a pointed trowel) while the skull was still relatively damp cannot be excluded since the outer margin of the depression was light in colour. (2) Right temporal, posterior to the mastoid process: a shallow minor surface damage to the outer table, in the middle was found a 3 mm-wide oval-shaped puncture penetrating the bone. No evidence of tooth marks was noticed, and the defect shows light fracture margins—so likely excavation damage.	Lateral, on left side (face almost prone)
1349	1	Male	MA	(1) Right mandible, ramus: a puncture to the right mandibular ramus, a few mm superior of gonion. A small pushed-in bone flake is visible inside the puncture. Two slightly ragged fracture lines are radiating posterior and inferior from the puncture mark.	Supine
1269	2	Male	YA	(1) Left temporal, squama: a square/slightly elliptical puncture to the left temporal squama with two fine radiating fracture lines on squama. There is no evidence of tooth marks from animal scavenging.	Supine

### Row 3

The vast majority of the skeletons in Row 3, the east row, were more poorly preserved than the other skeletons in Rows 1–2, though being excavated at the same time (early April 2016) and thus equally exposed before documentation. No animal scavenging was noticed, although bleaching, erosion, and excavation damage were noticed on the majority of the skeletons; extensive *postmortem* breaks were found on all, and staining was noted, in slight amount, on the majority.

The upper part of the skeletons of nos. 1285, 1277, 1276, and 1275 were severely fragmented and totally bleached. The thoraces of nos. 1271 and 1272 were also in a poor state of preservation. Nos. 1294 and 1316 were somewhat better preserved, although with a hard crust of soil adhering to the crania. Nos. 1332, 1384, and 1385 were fairly well preserved and not much bleached, probably because large parts of the skeletons were still covered with soil. Nos. 1339 and 1344 were well preserved; their colour was brown with a dark patina on the lower parts of the skeletons.

Nos. 1398, 1400, and 1399 were excavated in July 2016, at the time of the field documentation. These skeletons were very well preserved and all had, at the time, the same dark brown-black colour, although the upper limbs were slightly lighter in colour. The same colour differences were noted also on the other skeletons in Row 3: the colour differences may indicate that the deposition was made in a shallow trench, or on the contemporary soil surface where some parts had not been properly covered, i.e. longer exposed to the elements (Fig. 25).

### Puncture marks

Two individuals in Row 1, nos. 1343 and 1349, and one individual in Row 2, no. 1269, exhibit puncture marks to the cranium or to the mandible (Table 6, Figs. 26–31). These defects/puncturing are not associated with evidence of gnawing.

A tentative interpretation is that they result from *postmortem* damage, possibly caused during excavation while bones were still damp. However, sharp force *perimortem* trauma cannot be totally excluded in all cases. Informed interpretation can only be made following a full anthropological analysis, with observation of fracture margins under laboratory conditions.

### Archaeoethanatology

The bodily changes a corpse undergoes after death as a consequence of biological and cultural processes (e.g. treatment of the corpse) are essential information for interpretations of the burial context.<sup>34</sup> When human skeletal remains are uncovered, the state of articulation between skeletal elements is important for understanding the processes related to decomposition; for example if a body was decomposing in full space (covered), in empty space (exposed), or if parts of the body had been disturbed or displaced after burial.

The observations regarding archaeoethanatology are summarized in Tables 7 and 8.

The articulation between skeletal elements as well as the position of limbs indicate that the bodies were all rapidly covered after deposition. However, some parts of the bodies were probably only partially covered, as evidenced by occasional signs of animal scavenging, weathering, and displaced but articulated body parts. Occasionally missing and dispersed skeletal elements may be due to later disturbances, but a time-frame could not be determined; it could have happened soon after deposition, or much later. Postdepositional disturbances were noted in the northern and southern part of Row 1.

<sup>34</sup> Knüsel 2014; Duday 2009.



*Fig. 26. No. 1343, puncture mark, right parietal.*



*Fig. 27. No. 1343, puncture mark, right temporal.*



*Fig. 28. No. 1349, puncture mark, right mandible.*



*Fig. 29. No. 1349, close up of puncture mark, right mandible.*



*Fig. 30. No. 1269, puncture mark, left temporal.*



*Fig. 31. No. 1269, close up of puncture mark, the left temporal.*

### **PALAEODEMOGRAPHY**

Osteological estimations of biological age, sex, and stature of ancient populations often rely on evaluation of macroscopic criteria in the skeleton. These estimations, however, rest on data derived from studies of modern populations.

Thus, skeletal development, and characteristics regarding biological age and sex are often complicated and imprecise regarding analyses of earlier populations. In this case, the data are even more uncertain because of the field situation earlier mentioned.

Table 7. State of articulation: skull, upper thorax, and general observation on body decomposition (C = connected; D = disconnected; A = absent; U = unobservable; ND = not determined; X = present).

Table 7 continued.

Skel. no.	Row	Ligaments					Full space	Empty space
		temporo-mand		cranio-atlanto	atlanto-axial	axial-C3		
		left	right					
1201	1	A	A	U	U	U	X	X
1202	1	A	A	C	C	C	X	
1215	1	C	C	D	C	C	X	
1245	1	A	C	C	C	C	X	X
1247	1	A	A	A	A	A	?	?
1253	1	A	A	U	U	U	X	
1266	1	C	C	C	D	C	X	
1281	1	C	C	U	U	U	X	
1289	1	U	U	U	U	U	X	
1296	1	C	C	U	U	U	X	
1297	1	C	C	U	U	C	X	
1318	1	U	U	U	U	U	X	X
1324	1	C	C	D	C	C	X	
1325	1	U	C	C	C	C	X	
1328	1	D	D	U	U	U	X	X
1336	1	C	C	U	U	U	X	
1339	1	C	C	U	U	U	X	
1340	1	C	C	U	U	U	X	
1342	1	U	C	D	C	C	X	
1343	1	U	U	U	U	U	X	
1348	1	D	D	U	U	U	X	
1349	1	C	U	U	U	U	X	
1350	1	C	C	U	U	U	X	
1353	1	C	C	U	U	U	X	
1354	1	C	C	U	U	C	X	
1355	1	C	C	U	U	U	X	
1356	1	C	C	D	C	C	X	
1358	1	C	C	U	U	U	X	
1359	1	D	D	C	D	C	X	
1360	1	U	D	D	D	D	X	
1361	1	C	C	U	U	C	X	
1363	1	C	C	D	D	C	X	
1364	1	U	U	U	U	U	X	
1365	1	U	U	U	U	U	X	
1366	1	A	A	A	A	A	X	X
1373	1	U	U	U	U	U	X	
1374	1	U	U	U	U	U	X	
1375	1	C	U	U	U	U	X	
1376	1	C	C	U	U	U	X	
1379	1	C	C	U	U	U	X	

Skel. no.	Row	Ligaments					Full space	Empty space
		temporo-mand		cranio-atlanto	atlanto-axial	axial-C3		
		left	right					
1380	1	C	C	C	C	C	X	
1381	1	C	C	U	D	D	X	
1382	1	C	C	U	U	U	X	
1383	1	C	C	U	U	C	X	
1390	1	C	C	U	U	U	X	
1392	1	U	U	U	U	U	X	X
1393	1	A	A	A	A	A	X	X
1228	2	C	C	U	U	?	X	
1267	2	C	C	U	U	U	X	
1268	2	C	C	C	C	C	X	
1269	2	C	C	U	U	U	X	
1298	2	C	C	U	U	U	X	
1351	2	C	C	D	U	C	X	
1357	2	C	C	U	U	U	X	
1368	2	C	C	C	C	C	X	
1369	2	C	C	C	C	?	X	
1370	2	C	C	U	U	C	X	
1371	2	C	C	U	C	C	X	
1386	2	C	C	U	U	U	X	
1387	2	C	C	U	U	U	X	
1388	2	C	C	U	U	U	X	
1389	2	C	C	U	C	U	X	
1397	2	U	U	U	U	U	X	
1271	3	C	C	U	C	D	ND	
1272	3	U	U	U	U	U	X	
1275	3	C	C	U	U	U	ND	
1276	3	U	U	U	U	U	ND	
1277	3	U	U	U	U	U	ND	
1285	3	U	U	A/U	A/U	A/U	X	
1294	3	U	C	U	U	U	ND	
1316	3	ND	ND	ND	ND	ND	ND	
1332	3	ND	ND	ND	ND	ND	ND	
1333	3	C	C	U	U	U	X	
1344	3	U	U	U	U	U	ND	
1384	3	ND	ND	ND	ND	ND	ND	
1385	3	D	D	U	U	U	ND	
1398	3	C	U	ND	ND	ND	ND	
1399	3	C	C	C	U	U	X	
1400	3	U	U	U	U	U	ND	

Table 8. State of articulation, postcranial elements (C = connected; D = disconnected; A = absent; U = unobservable; ND = not determined; sin = left; dx = right).

Skel. no.	Row	State of articulation																			
		Cervical column		Distal part of the hand		Distal part of the foot		Scapula-humerus joint		Atlanto-occipital	Lumbar column	Lumbar-sacrum	Sacrum-iliac		Knee-cap		Ankle bones—tibia, fibula-tarsals		Tarsals—meta-tarsals		
			sin	dx	sin	dx	sin	dx				sin	dx	sin	dx	sin	dx	sin	dx	sin	dx
1201	1	C3–C7 C	D	A	A	U	C	A	U	C	D	D	D	A	A	C	C	C	C	C	C
1202	1	C	A	A	A	C	A	C	C	C	C	C	C	A	A	A	C	A	A	C	C
1215	1	C	C	C	U	A	C	C	D	C	C	C	C	U	D	C (fibula)	A	U	A	A	A
1245	1	C	D	C	A	A	A	C	C	A	A	A	C	A	C	A	A	A	A	A	A
1247	1	A	A	A	A	A	A	A	A	A	A	A	A	A	A	A	A	A	A	A	A
1253	1	C	A	A	C	C	A	D	U	C	C	C	C	A	A	C	C	C	C	C	C
1266	1	C	U	U	C	C	D	C	C	C	D	C	D	C	U	C	D	C	C	C	C
1281	1	C3–C7 C	C	C	C	C	U	D	U	C	C	D	D	C	C	C	C	C	C	C	C
1289	1	C	U	U	U	C	C	U	U	C	U	C	U	U	U	U	C	U	C	U	C
1296	1	C	D	U	U	U	C	C	C	C	C	C	C	C	A	C	A	C	C	C	C
1297	1	C	U	U	C	C	C	U	U	C	C	C	C	A	A	C	C	C	C	C	C
1318	1	A	U	U	C	A	A	A	A	A	C	C	C	C	C	C	C	C	C	C	C
1324	1	C	C	C	C	C	C	C	D	C	C	C	C	A	D (collapsed, probably C)	C	C	C	C	C	C
1325	1	C	C	D	C	U	C	C	C	C	C	C	C	C	C	C	C	C	C	C	C
1328	1	C3–C7 C	U	C	C	C	U	D	U	C	D	C	D	U	U	U	C	C	C	C	C
1336	1	U	C	C	U	C	U	D	D	U	U	C	C	D	D	C	C	C	C	C	C
1339	1	U	A	C	U	U	D	U	U	U	U	U	U	C	C	C	C	C	C	C	C
1340	1	C	U	U	U	U	U	C	U	C	U	U	U	U	U	U	C	U	C	U	C
1342	1	C	U	U	U	U	C	U	D	C	C	C	C	U	U	U	U	U	U	U	U
1343	1	U	U	U	A	A	U	A	U	D (L3–L4)	C	C	C	C	C	C	C	C	C	C	C
1348	1	C	U	U	U	U	D	D	U	C	C	C	C	A	C	C	C	C	C	C	C
1349	1	U	U	U	U	U	C	D	U	C	C	C	C	U	C	C	C	C	C	C	C
1350	1	C6–C7 C	C	U	C	U	C	C	U	C	C	D	C	C	C	C	C	C	C	C	C
1353	1	U	U	U	C	C	A	C	U	C	D	C	C	C	C	U	U	C	U	C	U
1354	1	C	U	U	U	U	C	C	U	C	C	D	C	C	A	U	U	C	U	C	U
1355	1	C	U	U	U	U	U	C	U	U	U	U	U	U	U	C	U	C	U	C	U
1356	1	C	U	U	C	U	U	C	U	C	U	U	U	C	C	C	C	C	C	C	C
1358	1	C	U	U	C	C	D	C	U	C	U	C	C	U	A	C	C	C	C	C	C
1359	1	C	U	C	C	C	C	D	C	C	D	C	C	C	C	C	C	C	C	C	C
1360	1	U	C	U	D	U	D	C	D	C	C	C	C	U	U	C	C	C	C	C	C
1361	1	C	U	U	U	C	U	D	U	U	D	D	D	U	C	C	U	C	U	C	U
1363	1	C2–C7 C	C	C	C	C	C	C	D	C	C	C	C	C	C	C	C	C	C	C	C
1364	1	C	U	U	C	C	C	C	U	C	D	D	C	C	C	C	C	C	C	C	C
1365	1	U	U	U	U	U	D	C	U	C	C	C	C	C	C	D	D	C	C	C	C
1366	1	A	U	U	C	C	A	D	A	C	C	U	C	C	U	C	C	C	C	C	C
1373	1	C	U	A	U	C	C	U	U	C	C	C	C	C	C	U	C	U	C	C	C
1374	1	C	C	C	U	C	C	D	U	C	D	D	D	A	A	C	C	C	C	C	C
1375	1	C3–C7 C	U	C	C	C	D	D	U	C	C	U	D	C	C	C	C	C	C	C	C
1376	1	U	U	C	U	U	D	U	U	C	C	D	D	U	U	C	C	C	C	C	C

Table 8 continued.

Skel. no.	Row	State of articulation																	
		Cervical column	Distal part of the hand		Distal part of the foot		Scapula-humerus joint		Atlanto-occipital	Lumbar column	Lumbar-sacrum	Sacrum-iliac		Knee-cap		Ankle bones—tibia, fibula-tarsals		Tarsals—meta-tarsals	
			sin	dx	sin	dx	sin	dx				sin	dx	sin	dx	sin	dx	sin	dx
1379	1	C	A	C	C	C	A	C	U	C	C	C	U	U	C	C	C	C	
1380	1	C	U	U	C	C	U	U	C	C	D	Y	C	D	C	C	C	C	
1381	1	C	U	C	C	C	C	C	U	C	C	U	U	U	U	C	U	C	
1382	1	C	C	D	C	U	C	C	U	C	C	D	D	C	C	C	C	C	
1383	1	C	C	U	U	C	C	C	U	C	D	C	C	C	A	C	C	C	
1390	1	C	U	C	U	U	C	C	U	C	U	C	C	A	C	U	U	U	
1392	1	A	A	A	U	U	A	A	A	A	A	A	A	C	C	C	C	C	
1393	1	A	A	A	A	C	A	A	A	D	C	C	C	C	D (collapsed, probably C)	D	C	C	
1228	2	C	C	C	C	C	C	U	U	U	U	C	U	C	?	C	C	C	
1267	2	C	C	C	A	A	C	C	U	U	C	U	C	A	A	A	A	A	
1268	2	C	C	C	U	U	U	C	C	D	C	C	C	C	A	C	C	?	
1269	2	C	A	C	U	U	C	C	U	C	D	C	C	C	C	C	C	C	
1298	2	U	U	U	U	U	C	U	U	D	U	U	U	C	U	U	U	U	
1351	2	U	C	C	C	C	C	C	D	C	U	U	U	U	U	C	U	C	
1357	2	U	C	U	U	U	U	U	U	U	U	C	U	U	U	U	U	U	
1368	2	?	C	U	C	U	U	C	C	U	U	U	U	C	U	U	U	U	
1369	2	C	U	C	U	C	U	U	C	U	U	U	U	U	U	U	C	U	
1370	2	C	C	U	U	U	C	U	C	C	U	U	U	U	U	C	U	C	
1371	2	C	U	U	C	C	C	C	U	C	D	C	C	C	C	C	C	C	
1386	2	U	C	U	U	U	U	D	U	C	U	U	U	U	U	U	C	U	
1387	2	U	U	U	U	U	U	C	U	U	U	U	U	U	U	U	U	U	
1388	2	U	U	U	C	C	U	U	U	D	C	U	C	A	A	C	C	C	
1389	2	U	C	C	U	U	U	D	U	U	U	U	U	U	U	C	C	C	
1397	2	U	C	U	C	U	U	U	U	U	U	U	U	A	D	C	U	C	
1271	3	C	U	C	U/A	U/A	C	C	U	C	C	C	C	U	D	U	U	U	
1272	3	C	U	U	U	U	U	U	U	U	U	C	C	U	U	U	U	U	
1275	3	C	A	A	U	C	U	C	U	U	U	C	C	C	C	U	C	U	
1276	3	U	A	A	U	U	C	D	U	U	U	C	C	U	D	U	U	U	
1277	3	U	U	U	U	U	U	U	D	C	D	D	C	U	C	U	U	U	
1285	3	U	A	A	A	A	A	A	A	C	C	D	C	A	A	A	C	A	
1294	3	U	U	U	U	U	D	C	U	C	D	C	C	C	U	C	U	U	
1316	3	ND	ND	ND	ND	ND	ND	ND	ND	ND	ND	ND	ND	ND	ND	ND	ND	ND	
1332	3	ND	ND	ND	ND	ND	ND	ND	ND	ND	ND	ND	ND	ND	ND	ND	ND	ND	
1333	3	C	C	C	U	U	U	C	U	C	C	C	C	U	C	U	U	U	
1344	3	C	U	U	U	U	C	U	U	U	U	U	U	U	U	?	?	?	
1384	3	ND	ND	ND	ND	ND	ND	ND	ND	ND	ND	ND	ND	ND	ND	ND	ND	ND	
1385	3	U	U	U	C	U	D	U	U	U	U	U	U	U	U	C	U	C	
1398	3	U	U	C	U	U	U	C	U	U	U	C	U	U	U	U	U	U	
1399	3	C	C	U	C	C	U	C	C	U	U	U	U	U	U	U	C	U	
1400	3	U	U	U	U	U	C	U	U	U	U	C	C	U	U	C	C	U	

The estimation of age and sex was made through observations of observable morphological criteria on the skeleton.

### Sex

The morphological criteria of the hip bone (*os coxae*) (grade 1–5: greater sciatic notch; Y/N—preauricular sulcus; grade 1–3: the rest) and the cranium (grade 1–3: grade 1–5: nuchal crest, mastoid process, supraorbital margin, glabella, mental eminence), presented by Buikstra and Ubelaker were prioritized for sex determinations.<sup>35</sup> Since the most reliable indicators of sex are found on the *os coxae*, these features were given priority. If only one male or female feature alone could be observed, it was considered insufficient evidence for sex estimation (Table 9). Measurements of the postcranial skeleton have also been used to aid sex determinations. In general, males are larger and more robust and have larger dimensions for example articular surface dimension.

Apart from the evaluation of the dimorphic features of the *os coxae* and the skull recommended by Buikstra and Ubelaker *Pelvis* (grade 1–5: greater sciatic notch; Y/N—preauricular sulcus; grade 1–3: the rest), the following features were also recorded and considered for sex determination:<sup>36</sup>

#### *Os coxae*

—Subpubic angle (narrow—male, wide—female, ambiguous—undetermined)

#### Skull

—Angle of the frontal (sloped—male, straight—female, ambiguous—undetermined)

—Presence of frontal and parietal eminences (absent—male, present—female, slight—undetermined)

—Orbital outline (square—male, rounded—female, ambiguous—undetermined)

—Gonial flare of the mandible (flared—male, no flare—female, ambiguous—undetermined)

#### Other—postcranial

—Vertical diameter of humeral head

—Maximum diameter of femoral head

—Epicondylar breadth of femur

A majority of the individuals demonstrated predominantly male characteristics although 24 individuals (30%) could not be determined to sex since criteria were either unobservable or inconclusive (Table 10).

Seventy-one of 79 individuals had at least one criterion for sex determination observable on the cranium, whereas 62 in-

dividuals had at least one criterion observable on the *os coxae* (pelvis). Three individuals had no criteria for sex estimation observable (no. 1247 and no. 1392 in Row 1, and no. 1277 in the Row 3).

The individuals generally display more gracile features on their skulls than on the *os coxae*: 34 of 71 (48%) observable skulls showed at least one female feature, while only 6% of the 62 individuals exhibited at least one female feature on the *os coxae*. This is likely a consequence of the generally young mean age at death; a majority of the individuals estimated to an age group were young (juvenile or young adults). Since many individuals were missing observable diagnostic criteria for sex determination, it cannot be ruled out conclusively that this sample also contains female individuals. The age of the individual can affect dimorphic features in the skeleton; adolescent males may show gracile features on the cranium and old females may display more robust masculine characteristics on the cranium.<sup>37</sup>

At least one post-cranial measurement indicative of sex could be taken on 24 individuals, a majority of these measurements indicated “Male” or “Male?” (54%). In total, 26 measurements indicative of sex were taken, a majority of these indicate “Male” (Table 11 and Appendix 1).

### Age

Estimation of age-at-death was based on observations of the following criteria: epiphyseal union,<sup>38</sup> morphological changes of the pubic symphysis,<sup>39</sup> tooth eruption,<sup>40</sup> and dental wear.<sup>41</sup> General observations on suture closure were documented, although the composite ectocranial scores recommended by Buikstra and Ubelaker were not applicable since not all required sites on the crania could be observed.<sup>42</sup> The degree of suture closure was however used to corroborate other criteria, or used as guidance when epiphyseal union was complete and no other criteria were observable.

The following age groups were employed: Juvenile 12–19 years; Young adult (YA) 20–34 years; Middle adult (MA) 35–49 years; Old adult (OA) 50+ years; Adult ≥20 years.<sup>43</sup> The term “Adult” was used when complete union of epiphyses was noted in addition with observation on tooth eruption and/or suture closure (Tables 12–13).

The observable criteria provided a general indication for age group; more precise age estimations were rarely possible.

<sup>37</sup> Walker 1995.

<sup>38</sup> Buikstra & Ubelaker 1994.

<sup>39</sup> The Suchey-Brooks system in Buikstra & Ubelaker 1994.

<sup>40</sup> Ubelaker 1989, fig. 71.

<sup>41</sup> Brothwell 1972, 69, fig. 30.

<sup>42</sup> Buikstra & Ubelaker 1994.

<sup>43</sup> Buikstra & Ubelaker 1994; Scheuer & Black 2000.

<sup>35</sup> Buikstra & Ubelaker 1994.

<sup>36</sup> White 1991; Krogman 1978; Stewart 1979; Spradley & Jantz 2011.

Table 9. Observable criteria for sex estimation.

Skel. no.	Row	Total no. criteria, skull—female	Total no. criteria, skull—male	Total no. criteria, skull—ambiguous	All criteria, skull	Sex—cranium	Total no. criteria, coxae—male	Total no. criteria, coxae—female	Total no. criteria, coxae—ambiguous	All criteria coxae	Sex—coxae	Sex from measurements (Stewart 1979)	Final sex
1201	1	0	1	0	1	Undetermined	0	0	0	0	Undetermined	Male?	Undetermined
1202	1	0	0	0	0	Undetermined	1	0	0	1	Male?		Undetermined
1215	1	0	2	1	3	Male?	0	0	0	0	Undetermined		Male?
1245	1	0	0	3	3	Undetermined	1	0	0	1	Male?	Female?	Undetermined
1247	1	0	0	0	0	Undetermined	0	0	0	0	Undetermined		Undetermined
1253	1	0	0	0	0	Undetermined	1	0	0	1	Male?		Undetermined
1266	1	0	6	1	7	Male	0	0	0	0	Undetermined	Male	Male?
1281	1	3	3	1	7	Undetermined	4	0	0	4	Male	Undetermined	Male
1289	1	0	5	0	5	Male	1	0	0	1	Male?		Male
1296	1	3	3	2	8	Undetermined	0	0	0	0	Undetermined	Female?	Undetermined
1297	1	0	2	0	2	Male?	0	0	0	0	Undetermined		Undetermined
1318	1	0	0	0	0	Undetermined	4	1	0	5	Male?		Male
1324	1	0	8	1	9	Male	3	1	0	4	Male?	Undetermined	Male
1325	1	0	1	0	1	Undetermined	1	0	0	1	Male?		Male?
1328	1	0	4	3	7	Male?	4	0	0	4	Male	Male	Male
1336	1	2	3	0	5	Undetermined	1	0	0	1	Male?		Undetermined
1339	1	1	7	0	8	Male	1	0	0	1	Male?		Male
1340	1	0	7	0	7	Male	1	0	0	1	Male?		Male
1342	1	4	2	1	7	Undetermined	1	0	0	1	Male?		Undetermined
1343	1	1	1	1	3	Undetermined	0	0	1	1	Undetermined		Undetermined
1348	1	1	3	4	8	Undetermined	2	0	0	2	Male	Male	Male?
1349	1	0	5	2	7	Male	1	0	0	1	Male?	Male	Male
1350	1	0	4	4	8	Undetermined	4	0	0	4	Male	Female?	Male
1353	1	2	5	1	8	Male?	0	0	1	1	Undetermined		Undetermined
1354	1	0	4	2	6	Male?	0	0	1	1	Undetermined		Undetermined
1355	1	0	7	1	8	Male	1	0	0	1	Male?		Male
1356	1	2	3	3	8	Undetermined	1	0	0	1	Male?		Male?
1358	1	0	4	3	7	Male?	2	0	0	2	Male		Male
1359	1	1	4	3	8	Male?	3	0	0	3	Male	Undetermined	Male
1360	1	0	4	1	5	Male?	1	0	0	1	Male?		Male?
1361	1	1	3	3	7	Undetermined	4	1	0	5	Male	Undetermined	Male?
1363	1	1	2	5	8	Undetermined	0	0	1	1	Male?		Undetermined
1364	1	2	2	3	7	Undetermined	5	0	0	5	Male		Male
1365	1	1	0	4	5	Undetermined	2	0	0	2	Male		Male?
1366	1	1	6	1	8	Male?	0	0	0	0	Undetermined	Undetermined	Male?
1373	1	2	5	1	8	Male?	1	0	3	4	Male	Male	Male?
1374	1	1	6	0	7	Male	4	0	0	4	Male	Male?	Male

Table 9 continued.

Skel. no.	Row	Total no. criteria, skull—female	Total no. criteria, skull—male	Total no. criteria, skull—ambiguous	All criteria, skull	Sex—cranium	Total no. criteria, coxae—male	Total no. criteria, coxae—female	Total no. criteria, coxae—ambiguous	All criteria coxae	Sex—coxae	Sex from measurements (Stewart 1979)	Final sex
1375	1	1	4	3	8	Undetermined	2	1	0	3	Male?		Male?
1376	1	1	0	0	1	Undetermined	4	0	0	4	Male		Male
1379	1	0	5	1	6	Male	1	0	0	1	Male?		Male
1380	1	1	5	2	8	Male	0	0	0	0	Undetermined		Male?
1381	1	2	5	1	8	Undetermined	2	0	1	3	Male?		Male?
1382	1	0	6	2	8	Male	3	0	0	3	Male		Male
1383	1	1	3	2	6	Undetermined	4	0	0	4	Male	Male	Male
1390	1	0	5	2	7	Male?	1	0	0	1	Male?		Male?
1392	1	0	0	0	0	Undetermined	0	0	0	0	Undetermined	Male?	Undetermined
1393	1	0	0	0	0	Undetermined	5	0	0	5	Male	Male	Male
1228	2	0	2	1	3	Male?	1	0	0	1	Male?		Male?
1267	2	2	4	2	8	Undetermined	1	0	1	2	Undetermined	Male	Male?
1268	2	1	5	1	7	Male?	1	0	0	1	Male?		Male?
1269	2	0	4	4	8	Male?	5	0	0	5	Male	Male	Male
1298	2	0	4	2	6	Male?	0	0	0	0	Undetermined		Male?
1351	2	0	2	1	3	Male?	1	0	0	1	Male?		Male
1357	2	2	2	2	6	Undetermined	2	0	0	2	Male		Male?
1368	2	1	6	2	9	Male	1	0	0	1	Male?		Male?
1369	2	1	6	0	7	Male	1	0	0	1	Male?	Male?	Male
1370	2	2	3	1	6	Undetermined	1	0	0	1	Male?	Undetermined	Male?
1371	2	2	3	4	9	Undetermined	2	0	0	2	Male		Male?
1386	2	0	6	3	9	Male?	1	0	0	1	Male?		Male?
1387	2	0	1	2	3	Undetermined	1	0	0	1	Male?		Male?
1388	2	0	4	1	5	Male	3	0	0	3	Male	Undetermined	Male
1389	2	0	1	1	2	Undetermined	1	0	0	1	Male?		Male?
1397	2	0	0	1	1	Undetermined	1	0	0	1	Male?		Undetermined
1271	3	0	3	3	6	Undetermined	0	0	0	0	Undetermined		Undetermined
1272	3	0	1	0	1	Undetermined	1	0	0	1	Male?		Male?
1275	3	0	1	3	4	Undetermined	0	0	0	0	Undetermined		Undetermined
1276	3	0	0	0	0	Undetermined	2	0	1	3	Male?		Male?
1277	3	0	0	0	0	Undetermined	0	0	0	0	Undetermined		Undetermined
1285	3	0	1	0	1	Undetermined	0	0	0	0	Undetermined		Undetermined
1294	3	1	0	3	4	Undetermined	0	0	1	1	Undetermined		Undetermined
1316	3	0	1	0	1	Undetermined	0	0	0	0	Undetermined		Undetermined
1332	3	0	1	2	3	Undetermined	0	0	0	0	Undetermined		Undetermined
1333	3	1	2	2	5	Undetermined	1	0	0	1	Male?		Male?
1344	3	0	2	0	2	Undetermined	1	0	0	1	Male?		Male?

Table 9 continued.

Skel. no.	Row	Total no. criteria, skull—female	Total no. criteria, skull—male	Total no. criteria, skull—ambiguous	All criteria, skull	Sex—cranium	Total no. criteria, coxae—male	Total no. criteria, coxae—female	Total no. criteria, coxae—ambiguous	All criteria coxae	Sex—coxae	Sex from measurements (Stewart 1979)	Final sex
1384	3	0	3	0	3	Male	1	0	0	1	Male?		Male?
1385	3	1	1	0	2	Undetermined	0	0	0	0	Undetermined		Undetermined
1398	3	3	3	2	8	Undetermined	0	0	1	1	Undetermined		Undetermined
1399	3	2	5	0	7	Male?	1	0	0	1	Male?	Undetermined	Male
1400	3	0	1	0	1	Undetermined	1	0	0	1	Male?		Male?

Table 10. Sex distribution (n = individuals).

Sex	n	%
Male	24	30.4
Male?	31	39.2
Undetermined	24	30.4
Female	0	0
Female?	0	0
<b>Total</b>	<b>79</b>	<b>100</b>

Table 11. Post-cranial measurements indicative of sex (mm).

Skel. no.	Row	Femur, left, maximum head diameter	Femur, right, maximum head diameter	Femur, right, epicondylar breadth	Humerus, right, vertical head diameter	Humerus, left epicondylar breadth	Humerus, right, epicondylar breadth
1201	1		47				
1245	1		43				
1266	1	48.1					
1281	1		44.1				
1296	1	43					
1324	1		46.3				
1328	1	48					
1348	1		47.7				
1349	1		48				
1350	1		43.4				
1359	1	44.9					
1361	1		46		44		
1366	1		46				
1373	1	51					
1374	1		47.5				
1383	1	48					
1392	1	47					
1393	1		48				
1267	2					70	
1269	2					67	
1369	2	47					
1370	2			78			
1388	2						55
1399	3				47		63

Table 12 (below). Observable criteria for age estimation (n = individuals).

Row	Epiphyseal union (n)	Tooth eruption (n)	Tooth wear (n)	Pubic symphysis (n)	Suture closure (n)
1	45	30	24	20	40
2	16	10	6	2	15
3	14	11	4	3	10
<b>Total</b>	<b>75</b>	<b>51</b>	<b>34</b>	<b>25</b>	<b>65</b>

Table 13a. Observation of age criteria and age estimation (*U* = unobservable; *A* = absent; *L* or *sin* = left; *R* or *dx* = right; *Max* = maxilla; *Mand* = mandible; *Age* = years).

Skel. no.	Row	Epiphyseal fusion							Pubic symphysis	
		Skull (cranium + mandible)	Thorax (sternum + ribs)	Vertebral column	Shoulder girdle (clavicle + scapula)	Upper limbs	Pelvis (coxae + sacrum + coccygis)	Lower limbs	L	R
1201	1	U	A	U	U	>14	>25	>14	U	U
1202	1	U	A	U/A	U/A	>14	U/A	>16	U	U
1215	1	U	U	U	U	>17	>20	U	U	U
1245	1	U	U/A	U	U/A	>14	U/A	>12	A	A
1247	1	U	A	A	A	A	A	A	A	A
1253	1	U	U/A	U	U/A	>17	>25	>16	U/A	U/A
1266	1	U	U	U	24–29	>20	>23	>20	U	U
1281	1	U	U	U	Fusing flake? >16–21	>20	<27	>20	U	I:1 (18.5)
1289	1	U	U	U	>18	>17	U	>19	U	U
1296	1	U	U	>19	U	>17	<27	>17	U	U
1297	1	U	U	U	>29	>17	>23	>18	U	U
1318	1	U	U	U	U	>16	c. 19, <27	>17, 18–19	I:1 (18.5)	U
1324	1	U	U	U	>23	>20	>23	>20	U	IV:1 (35.2)
1325	1	U	U	U	U	>20	>23	>20	U	U
1328	1	U	U	U	>29	>20	20–24	>20	III:1 (28.7)	U
1336	1	U	U	U	U	>17	>23	c. 20?	U	U
1339	1	U	U	U	U	U	U	U	U	U
1340	1	U	U	U	>29	>17	U	>20	U	U
1342	1	U	U	U	>20	>15	>23	>18	U	U
1343	1	U	U	U	U	>17	>20	>18	U	U
1348	1	U	>25	U	24–29	>20	>23	>20	II:1 (23.4)	II:1 (23.4)
1349	1	U	U	U	>20	>20	>23	>20	U	V:1 (45.6)
1350	1	U	>25	U	>29	>20	>23	>20	IV:1 (35.2)	U
1353	1	U	U	U	U	>17	>23	>15	U	U
1354	1	U	U	U	>29	>16	>23	>20	U	U
1355	1	U	U	U	U	>20	>23	>20	U	U
1356	1	U	U	U	U	>20	>23	>20	U	U
1358	1	U	U/A	U	>29	>20	>20	>20	U	IV:1 (35.2)
1359	1	U	U	U	>20	>20	>23, <27?	>20	II:1 (23.4)	U

Table 13b. Observation of age criteria and age estimation (*U* = unobservable; *A* = absent; *L* or *sin* = left; *R* or *dx* = right; *Max* = maxilla; *Mand* = mandible; *Age* = years).

Tooth eruption, M3		Tooth wear		Suture closure (ectocranial)			Age estimation
Maxilla	Mandible	Maxilla	Mandible	Coronal	Sagittal	Lambdoid	Age group
U	U	U	U	minimal–significant	U	U	Adult
U	U	U	U	significant	U	U	Adult
U/A	U/A	U	U	U	almost obliterated	U	Adult
M3 sin erupted, M3 dx—U	M3 dx erupted, sin—U	U	35–45	significant	obliteration	significant	Middle adult
A	A	A	A	U	U	U	Adult
U/A	U/A	U/A	U/A	U	U	U	Adult
M3 erupted dx, sin—U	M3 dx—U?, M3 sin—U	17–25	17–25	U	U	U	Young adult
M3 sin—not erupted, dx—U	M3—sin not erupted, dx—U	U	17–25	U	U	open–minimal	Young adult
U	U	U	U	minimal	minimal	minimal	Adult
A	A	17–25	17–25	open	U	U	Young adult
M3 sin—U, M3 dx erupted	U	U	U	U	open	open	Young adult
U	U	U	U	U	U	U	Juvenile
M3 sin, dx erupted, M3 dx—U	M3 sin erupted, M3 dx—U	U	U	significant	U	minimal	Middle adult
U	U	U	U	U	U	minimal	Adult
M3 dx erupted, M3 sin—U	M3 sin /dx erupted	U	25–35	significant–obliteration	significant–obliteration	open	Young adult
U prob. A?	U	U	U	open	open–minimal	open	Young adult
M3 sin erupted, dx—U	M3 sin erupted, dx—U	U	U	minimal–significant	minimal	minimal	Adult
U	U	25–35	U	significant	U	significant	Young adult
U	U	U	U	open	minimal	minimal	Adult
U	U	U	U	significant	significant	significant	Adult
M3 sin erupted, M3 dx—A	A	U	17–25	minimal	U	U	Young adult
M3 sin erupting, M3 dx—U/A	M3 sin/dx erupted	U	dx 17–25, sin 25–35	significant–obliteration	obliteration	U	Middle adult
M3 sin—A, M3 dx erupted	M3—dx erupted, M3—sin erupted	U	dx 25–35, sin 17–25	significant	U	U	Middle adult
M3 sin/dx erupted	M3 sin/dx erupted	U	25–35	open–minimal	open–minimal	U	Young adult
M3 sin, present but not <i>in situ</i> , M3 dx—A	M3 sin/dx erupted	U	25–35	significant	significant	U	Middle adult
M3 dx erupted, sin—U	M3 sin/dx—U	U	U	open	minimal	open	Young adult
M3 sin—U, M3 dx—U/A	M3 sin/dx—U	U	U	significant	obliteration	significant	Adult
M3 dx/sin erupted	M3 erupted	25–35	25–35	significant	U	U	Middle adult
M3 sin/dx erupted	M3 erupted	U	U	minimal	U	minimal	Young adult

Table 13a continued.

Skel. no.	Row	Epiphyseal fusion							Pubic symphysis	
		Skull (cranium + mandible)	Thorax (sternum + ribs)	Vertebral column	Shoulder girdle (clavicle + scapula)	Upper limbs	Pelvis (coxae + sacrum + coccygis)	Lower limbs	L	R
1360	1	U	U	U	U	>17	>23	>20	U	U
1361	1	U	U	U	>29	>20	>23	>20	IV:1 (35.2)	U
1363	1	U	U	U	>20	>17	>23	>17	U	U
1364	1	U	A	U	>29	>17	c.25?	>20	II:1 (23.4)	U
1365	1	U	U	U	>18	>20	15–22, c. 19	>18–20	I (18.5)	U
1366	1	U	U	>19	>20	>17	>23	>20	U	U
1373	1	U	U	U	U	>17	>23	>20	U	IV:1 (35.2)
1374	1	U	U	U	>29	>20	>23	>20	V:1 (45.6)	U
1375	1	U	U	U	>20	>20	>23	>20	VI:1 (61.2)	VI:1 (61.2)
1376	1	U	>16	U	>29	>20	>23	>19	U	III:1 (28.7)
1379	1	A	U	U	U	>17	>23	c. 20	U	U
1380	1	U	U	U	U/A	>17	U/A	>17–20	U	U
1381	1	U	A	U	>29	>17	>23	>20	III:1 (28.7)	U
1382	1	U	U	U	>17	>20	>23	>20	III:1 (28.7)	III:1 (28.7)
1383	1	U	U	U	16–21	>20	c. 19–20	c. 18–20	I:1 (18.5)	I:1 (18.5)
1390	1	U	U	U	U	>20	>23	>17	U	U
1392	1	U	U	U	U	U	U	c. 20?	U	U
1393	1	U	U	U	U	U	<27	>20	U	III:1 (28.7)
1228	2	U	U	U	>29	>20	U	>20	U	U
1267	2	U	U	U	24–29	>20	>23	>19	U	U
1268	2	U	>20	U	16–21 (flake missing)	>20	>20	>19	U	U
1269	2	U	<20	U	<21	>20	<27	c.20	III:1 (28.7)	III:1 (28.7)
1298	2	U	U	U	>29	>17	>20	>20	U	U
1351	2	U	U	U	>20	>20	>23	>20	U	U
1357	2	U	U	U	U	>20	>23	>19	U	U
1368	2	U	U	U	U	>20	>20	>18	U	U
1369	2	U	U	U	>20	>20	U	>19	U	U

Table 13b continued.

Tooth eruption, M3		Tooth wear		Suture closure (ectocranial)			Age estimation
Maxilla	Mandible	Maxilla	Mandible	Coronal	Sagittal	Lambdoid	Age group
M3 dx erupted (only little visible), M3—U	U	U	U	minimal	minimal	minimal	Adult
M3 dx erupted, M3 sin—U	M3 sin erupted, M3 dx—U	U	dx 35–45, sin—U	U	obliteration	significant—obliteration	Middle adult
M3 dx erupted	M3 dx erupted	17–25	U	open	minimal	open—minimal	Young adult
M3 erupted	M3 dx not fully erupted	17–25	17–25	open	open	U	Young adult
A	M3—dx not pres	U	U	open	U	U	Juvenile
M3 sin/dx erupted	A	17–25/25–35	U	significant	U	U	Young adult
M3 sin/dx erupted	M3 dx erupted, M3 sin—U	U	17–25	significant	U	U	Young adult
M3 sin/dx erupted	M3 sin/dx erupted	25–35	25–35	significant	U	U	Middle adult
M3 sin erupted, dx—U	M3 sin erupted, dx—U	U	sin 25–35	significant—obliteration	U	U	Old adult
U	M3 sin erupted, dx—U	U	sin 17–25	significant	U	U	Young adult
U	U	U	U	open	minimal—significant	minimal	Young adult
M3 dx erupting, M3 sin—U	M3 dx erupting, M3 sin—U	U	U	open	open	open	Juvenile
M3 sin/dx erupted	A/U	uneven wear 17–35	uneven wear 17–35	significant	U	U	Young adult
U	M3 sin—U, M3 dx—A	U	25–35	significant	U	U	Young adult
M3 sin/dx erupted	M3 sin/dx erupted	U	17–25	open	U	U	Juvenile
M3 sin/dx erupted	M3 sin/dx erupted	U	25–35	significant	obliteration	U	Middle adult
U	U	U	U	U	U	U	Young adult
U	U	U	U	U	U	U	Young adult
M3 sin erupted, M3 dx—U	M3 sin—U, M3 dx—erupted	U	35–45	significant	minimal—significant	open—minimal	Middle adult
M3 dx erupting, M3 sin—U	M3 sin/dx erupting	U	17–25	minimal	minimal	U	Young adult
M3 sin/dx—U	M3 sin/dx—U	U	U	open—minimal	minimal	minimal	Young adult
M3 sin/dx erupted	M3 sin/dx erupted	U	U	minimal—significant	minimal—significant	minimal	Young adult
U	U	U	U	significant—obliteration	significant	minimal—significant	Adult
U	U	U	U	minimal	minimal	minimal	Adult
M3 sin erupted, dx—U	M3 sin erupted, dx—U	17–25	U	minimal	minimal	minimal	Young adult
M3 sin U, dx—erupted	M3 sin U, dx—erupted	17–25	U	significant	significant—obliteration	significant—complete	Middle adult
M3 sin erupted, M3 dx—U	M3 sin erupted, M3 dx—U	U	U	open	open	open	Young adult

Table 13a continued.

Skel. no.	Row	Epiphyseal fusion							Pubic symphysis	
		Skull (cranium + mandible)	Thorax (sternum + ribs)	Vertebral column	Shoulder girdle (clavicle + scapula)	Upper limbs	Pelvis (coxae + sacrum + coccygis)	Lower limbs	L	R
1370	2	U	U	U	>20	>20	>23	>20	U	U
1371	2	U	U	U	>29	>20	>23	>19	U	U
1386	2	U	U	U	24–29	>20	U	>19	U	U
1387	2	U	U	U	>20	>17	U	>20	U	U
1388	2	U	U	U	U	>17	>23	>20	IV:1 (35.2)	U
1389	2	U	U	U	U	>20	>23	>19	U	U
1397	2	U	U	U	U	>17	>23	>20	U	U
1271	3	U	U	U	U	>15	U	>18	U	U
1272	3	U	U	U	U	U	U	U	U	U
1275	3	U	U	U	U	U	U	U	U	U
1276	3	U	U	U	U	>20	>23	>20	III:1 (28.7)	U
1277	3	U	U	U	>18	U	U	>18	U	U
1285	3	U	U	U	U	U	>23	>18	U	U
1294	3	U	U	U	>23	>17	>23	>18	U	U
1316	3	U	U	U	U	>17	U	>18	U	U
1332	3	U	U	U	U	>15	>23	>17	II:1 (23.4)	U
1333	3	U	U	U	16–21	>17	<27	>20	U	U
1344	3	U	U	U	U	U	>20	U	U	U
1384	3	U	U	U	U	>17	>23	U	U	V:1 (45.6)
1385	3	U	U	U	U	U	U	<18	U	U
1398	3	U	U	U	16–21	>17	c. 20–23	U	U	U
1399	3	U	U	U	>20	>17	>23	>18	U	U
1400	3	U	U	U	>18	>20	>23	>20	U	U

Table 13b continued.

Tooth eruption, M3		Tooth wear		Suture closure (ectocranial)			Age estimation
Maxilla	Mandible	Maxilla	Mandible	Coronal	Sagittal	Lambdoid	Age group
M3 sin/dx—U	M3 sin/dx—U	U	U	open—minimal	open—minimal	open—minimal	Adult
M3 sin U, M3 dx—erupted	M3 sin U, M3 dx—erupted	U	25–35	minimal	minimal—significant	minimal	Young adult
M3 sin—U, M3 dx erupted	M3 sin erupted, M3 dx—U	U	U	open	minimal—significant	open—minimal	Young adult
M3 sin—U, M3 dx—U	M3 sin/dx erupted	U	U	U	U	U	Adult
M3 sin/dx erupted	M3 sin/dx erupted	U	17–25	significant	U	U	Middle adult
U	U	U	U	U	U	minimal	Adult
U	U	U	U	U	significant—complete	significant	Adult
M3 sin erupted, M3 dx—U	M3 sin—A, M3 dx—U	U	U	U	U	U	Adult
M3 sin—U, M3 dx not erupted	U	17–25	U	open	U	minimal	Juvenile
M3 sin—U, M3 dx erupted	M3 sin—U, M3 dx erupted	U	U	U	U	U	Adult
U	U	U	U	U	U	U	Young adult
U	U	U	U	U	U	U	Adult
U	M3 sin erupted, M3 dx—U	U	U	U	U	U	Adult
M3 sin—U, M3 dx erupted	M3 sin/dx—U	U	U	U	U	significant	Adult
U	U	U (M2 sin, wear noticed but age assessment not observable)	U	significant	significant	significant	Adult
M3 sin—U, M3 dx erupted	M3 sin U, M3 dx erupted	17–25	U	U	U	U	Young adult
M3 sin/dx erupted	M3 sin/dx erupted	U	U	U	minimal	U	Young adult
U	U	U	U	significant	significant	significant	Adult
M3 sin—U, M3 dx erupted	M3 sin—U, M3 dx erupted	35–45	35–45	significant	U	U	Middle adult
M3 sin not erupted, M3 dx—U	M3 sin/dx—U	U	No wear	U	U	open	Juvenile
M3 sin erupted, M3 dx—U	M3 sin erupted, M3 dx—U	U	U	open—significant	significant	significant	Young adult
M3 sin/dx—U	M3 sin—U, M3 dx erupting	U	U	open—minimal	significant	significant	Young adult
U	U	U	U	significant	significant	significant	Adult

Table 14. Age distribution.

Age group	<i>n</i>	%
Juvenile (12–19 years)	6	7.6
Young adult (20–34 years)	33	41.8
Middle adult (35–49 years)	13	16.4
Old adult (50+ years)	1	1.3
Adult (≥20 years)	26	32.9
<b>Total</b>	<b>79</b>	<b>100</b>

Yet, when incomplete epiphyseal union and tooth eruption was noted, a narrower age-range is suggested in the skeletal catalogue (*Appendix 1*).

A majority of the individuals assigned to an age group were young, i.e. young adults or juveniles (74%, *n* = 39). A substantial part of the individuals, however, could not be assigned to a specific age group. Of these, all were determined to be adults (33%, *n* = 26), but it cannot be excluded that old individuals are present within this category (*Table 14*).

Epiphyseal union was observable in 95% of the individuals (*n* = 75). Tooth eruption and tooth wear was observable in 63% and 49% of the individuals respectively, and 32% had the pubic symphysis observable. Observations on suture closure were noted in 87% of the individuals.

Only 18 (23%) of the individuals had all the aforementioned age-criteria observable, suggesting that many of these were somewhat older individuals, although their age profile does not significantly deviate from the total sample.

### Oral status

The documentation of oral status included presence or absence of visible teeth: not erupted, erupting, erupted/present, *antemortem* tooth loss (AMTL), or unobservable (*Tables 15–16*), as well as observations on pathologies and fractures (*Tables 17–18*).

The teeth and jaws of the individuals deposited in an extended position on their backs were variably exposed. Moreover, the lateral or prone position of some individuals made observations on oral status difficult or sometimes impossible; in some cases, the limbs of an adjacent individual covered the jaws of the neighbouring skeleton.

Since all teeth could not be examined in the field, frequencies of tooth pathology will not reflect the accurate individual prevalence. The documentation of teeth in Row 3 was especially difficult because of the individuals' position, so the observations on Rows 1 and 2 will only be briefly mentioned here.

In total, 66 out of 79 individuals (83%) had ≥ 1 tooth observable. Calculus, followed by linear enamel hypoplasia (LEH) and caries was most frequently observed on the individuals in Row 1 (*n* = 38) and Row 2 (*n* = 14); calculus = 34%

(Row 1) and 36% (Row 2); LEH = 32% (Row 1) and 21% (Row 2). Caries was noted in 13% and 7% of the individuals in Rows 1 and 2 respectively.

Oral status is closely connected with diet, as well as general health status and lifestyle. Calculus is mineralized bacterial plaque commonly found on the upper part of teeth. Calculus frequency has been regarded closely connected to diet, although a number of other factors such as salivary flow, oral hygiene, and cultural practices etc. are also influential and likely underestimated.<sup>44</sup> The formation of calculus and its relationship to diet is complicated: it has been associated both with a diet high in carbohydrates and with a diet rich in protein. A combination of low caries frequencies and high calculus frequencies has been regarded as indicative of a protein-rich diet.<sup>45</sup> Calculus was noted in 19 individuals.

Linear enamel hypoplasia (LEH), commonly observed as horizontal bands or pits of decreased enamel thickness on the tooth crowns, is an indicator of metabolic stress. Although there are also other causes, LEH has been found to be closely correlated with malnutrition and infectious disease.<sup>46</sup> Since these lesions do not remodel, they are permanent records of physiological stress episodes encountered during infancy and childhood when tooth crowns are forming.<sup>47</sup> LEH was noted on 15 individuals.

Caries results from acid production by bacteria and high frequencies are often associated with a diet rich in carbohydrates.<sup>48</sup> Although the dietary composition and frequency of eating/snacking are important, caries is considered a multifactorial disease; fluoride intake, salivary production and composition, general state of health, age, oral pH and hygiene as well as attrition are also important modifying factors influencing caries prevalence.<sup>49</sup> Caries was noted in seven cases.

Periodontal disease (PD) results from a chronic, often plaque-induced inflammation affecting first the soft tissues surrounding the teeth and then in advanced stages, the bone with development of periodontal pockets and resorption of the alveoli.<sup>50</sup> PD was noted on two individuals.

*Antemortem* tooth loss (AMTL) is multifactorial and related to caries and many other factors such as heavy dental wear, trauma, tooth extraction, and PD.<sup>51</sup> Caries and PD is closely linked with AMTL.<sup>52</sup> AMTL was noted on two individuals.

<sup>44</sup> Lieverse 1999.

<sup>45</sup> Lillie 1996.

<sup>46</sup> Goodman & Rose 1990; Larsen 2015, 44–48.

<sup>47</sup> Goodman *et al.* 1980.

<sup>48</sup> Hillson 1996, 269, 278.

<sup>49</sup> Hillson 1996, 283–284.

<sup>50</sup> Hillson 1996, 262.

<sup>51</sup> Lukacs 2007.

<sup>52</sup> Larsen 2015, 81.

At the end of the osteological field documentation a second, more detailed cleaning of teeth and jaws of the skeletons was commenced on the instructions of Dr Chryssoulaki; the cleaning was performed by a conservator (Panagiota Gki-oni) in order to prepare for and facilitate an additional examination of the individuals' oral status by a dentist (Maria Deligiannaki).<sup>53</sup> After the conservator's cleaning, a second anthropological/osteological inspection was made in great haste during the last days of the field documentation. As a result, details may have been missed.

### Stature

Skeletal growth and adult stature in earlier and modern populations are regarded as sensitive measurements of population health, living circumstances, and nutrition.<sup>54</sup>

Measurements of long bones *in situ* were taken wherever possible. Since the skeletons were articulated and because the bones could not be lifted and measured on an osteometric board, the measurements are approximations (Table 19). The result of the stature calculation is therefore necessarily tentative and likely an underestimation of mean height (Table 20).

For stature estimation, the formula presented by Mildred Trotter<sup>55</sup> for European and American male samples was applied, and an average of the male and female stature was calculated for individuals of undetermined sex.

The individuals determined as males were estimated to be 162–177 cm ( $n = 48$ ), and the individuals not determined to sex were estimated to be 161–164 cm ( $n = 12$ ).

### PALAEOPATHOLOGY<sup>56</sup>

Palaeopathology concerns the identification of disease in skeletal or mummified remains, human and animal.<sup>57</sup> It aims to trace what illnesses were suffered by individuals during their life course through morphological observation of skeletal remains or through chemical analyses. The evidence of acute or chronic illness and stress suffered by individuals provide a clue to the health status in populations and individuals.<sup>58</sup>

Generally, two broad categories of pathologies were noted: porotic hyperostosis (PH) and degenerative joint disease (DJD); a few cases of periostitis and enthesophytosis were also observed (Tables 21–22).

Porotic hyperostosis (PH), indicated on 15 individuals, is characterized by expansion of the diploë (a spongy tissue

between the compact layers of bones in the cranium) with bilateral porous or pinpoint lesions on the ectocranial surface of the cranial vault particularly on the frontal, parietals, and the occipital.<sup>59</sup> Similar changes may also be present on the upper roof of the orbits, so-called *cribra orbitalia* (CO).<sup>60</sup> Both lesions are regarded as an indication of anaemia in most cases.<sup>61</sup> Acquired iron deficiency anaemia was for long time the most favoured explanation for these type of lesions. However, it has recently been shown that iron deficiency anaemia does not result in these types of lesions.<sup>62</sup> In Mediterranean contexts, where malaria has been endemic, PH has been associated with genetic anaemia such as thalassaemia, which in its heterozygous form can protect the individual from malaria.<sup>63</sup> J. Lawrence Angel hypothesized that a large number of PH cases in the Eastern Mediterranean developed as a response to malaria.<sup>64</sup> Although, genetic causes may be involved in some contexts, this explanation is now considered questionable in many cases: the aetiology of PH and CO are not clear and likely differ between geographical areas and contexts. In many cases, PH seems to result from nutritional megaloblastic anaemia or haemolytic anaemia.<sup>65</sup>

Since most crania were intact at the time of the field analysis, expansion of the diploë could rarely be observed; only one case of expanded diploë was noticed on a broken cranium, no. 1355, right parietal (Fig. 32). All PH lesions observed on 15 individuals consist of pinpoint porosities noted on the ectocranial vault, often close to sutures as well as unevenly distributed on the cranial bones (Fig. 33). CO was not noted; the orbits were more or less covered with soil and therefore often unobservable.

PH was more frequently noted on individuals in Row 2 compared to Rows 1 and 3. However, a majority of the individuals in Row 1 (70%) were placed in a supine position (sometimes with the cranium slightly inclined on one side), making documentation of the crania more difficult. Fewer individuals were deposited in supine positions in Rows 2 (25%) and 3 (37%). Thus, the positions of the individuals certainly influenced the observed PH prevalence since this lesion is most commonly found on the parietal or occipital bosses which could not always be observed on individuals in a supine position.

Degenerative joint disease (DJD) and osteoarthritis (OA) is commonly found in archaeological skeletons as well as mod-

<sup>53</sup> The report from Maria Deligiannaki is unpublished.

<sup>54</sup> Larsen 2015, 14–20.

<sup>55</sup> Table 18.5 in White *et al.* 2012, 420; Trotter 1970.

<sup>56</sup> Trauma is discussed in a separate section below.

<sup>57</sup> Ortner 2003, 8.

<sup>58</sup> Larsen 2015, 7–9.

<sup>59</sup> Stuart-Macadam 1992.

<sup>60</sup> Walker *et al.* 2009.

<sup>61</sup> Larsen 2015, 39.

<sup>62</sup> Walker *et al.* 2009.

<sup>63</sup> Buikstra & Ubelaker 1994, 120.

<sup>64</sup> Angel 1975.

<sup>65</sup> Walker *et al.* 2009; Larsen 2015, 39.















Table 16b continued.

Mandible, right							
I1	I2	C	PM1	PM2	M1	M2	M3
P	P	P	P	P	A	P	A
P	P	P	P	P	P	P	P
P	P	P	P	P	P	P	P
U	U	U	U	U	U	U	U
U	U	U	U	U	U	U	U
A, PM destruction	P	P	P	P	P	P	P
P	P	P	P	P	P	P	Erupting
P	P	P	U	U	U	U	U
U	U	U	U	U	P	P	U
U	U	U	U	U	U	U	U
U	U	U	U	U	U	U	U
P	P	U	U	U	U	U	U
P	P	P	P	P	P	P	P
U	U	U	U	U	U	U	U
U	U	U	U	U	U	U	U
P	P	P	P	P	P	P	P
P	P	P	P	P	P	P	P
P	P	P	P	P	P	P	P
P	P	P	P	P	P	P	P
U	U	U	U	U	U	U	U
U	U	U	U	U	U	U	U
A/U	P	P	P	P	P	P	U
P	P	P	P	P	P	P	U
P	P	P	P	P	P	P	P
A/U	A/U	A/U	A/U	A/U	A/U	A/U	A/U
A/U	A/U	A/U	A/U	A/U	A/U	A/U	A/U
A/U	A/U	A/U	A/U	A/U	A/U	A/U	A/U
P	P	P	P	P	P	P	U
U	U	U	U	U	U	U	U
U	U	P	P	P	P	P	P
P	P	P	P	P	P	P	P
U	U	U	U	U	U	U	U
U	U	P	P	P	P	P	P
U	U	U	U	U	U	U	U
P	P	P	P	P	U	U	U
P	P	P	P	P	P	P	U
U	U	U	U	U	U	U	U

Table 17. Summary of dental pathologies, fractures, and discolouration.

	<i>n</i> individuals
Linear enamel hypoplasia (LEH)	15
Calculus	19
Caries	7
Periodontal disease (PD)	2
<i>Antemortem</i> tooth loss (AMTL)	2
Fracture	4
Discolouration	9

Table 18. Dental pathologies and discolouration (LEH = linear enamel hypoplasia; PD = periodontal disease; AMTL = antemortem tooth loss; CEJ = cemento-enamel junction).

Skel. no.	Row	LEH	Calculus	Caries	PD	AMTL	Fracture	Discolouration	Pathology and discolouration, comments
1245	1						X		Right P1, mandible: labial enamel fracture.
1201	1								
1202	1								
1253	1								
1215	1								
1247	1								
1266	1								
1296	1	X	X				X		Fracture on left I2 and C, mandible.
1297	1								
1342	1								
1343	1	X							Right C, maxilla: LEH.
1325	1								
1379	1								
1380	1			X					Right M2, mandible: possibly buccal caries—CEJ.
1381	1		X	X					Left M1, mandible: deep wear and caries (+ fracture?) buccal/mesial; right M1, mandible: almost no wear; right M2, mandible: deep wear occlusal/distal; Slight to medium calculus on right mandibular incisors and C.
1360	1								
1358	1	X		X					Left PM2, M1, mandible: caries; left and right C, mandible: LEH; right I, mandible: extensive wear.
1289	1								
1324	1								
1328	1		X						Incisors, mandible: slight calculus.
1359	1	X						X	Right C, PM1, PM2, maxilla: LEH, two lines; blue discolouration especially on teeth in mandible.
1363	1				X				Right M1, maxilla: large abscess and periodontitis.
1364	1			X					Left PM2, maxilla: root <i>in situ</i> , caries, and possibly some caries on left M1 maxilla, as well?
1365	1	X			X				Left C, mandible: periodontitis; Left and right C and PMs, mandible: LEH.
1350	1	X				X			Mandibular teeth: medium LEH on all teeth, two lines; left M1, maxilla: AMTL.
1348	1	X							Left and right incisors and C, mandible: LEH—slight; congenital absence of right M3, mandible and maxilla.
1281	1								
1349	1						X		Right I1, maxilla: chipped <i>antemortem</i> .
1374	1	X	X						Left and right incisors and premolars in mandible, and left and right maxilla: medium LEH, two lines on incisors and C; slight calculus.
1376	1								
1375	1	X	X	X			X		Left I–C, mandible: medium calculus; left M3, mandible: caries, buccal; LEH, slight; P1 left mandible, P2 left maxilla: slight chipped fracture anterior/buccal; LEH on C–PM2, left maxilla.
1361	1		X						Left and right I1–I2: calculus labial.
1366	1							X	Mandible missing, marked reddish-brown-orange staining on all teeth in maxilla, esp. incisors.







Table 20. Mean stature ( $n = \text{individuals}$ ).

Mean stature	Femur ( $n$ )	Fibula ( $n$ )	Humerus ( $n$ )	Radius ( $n$ )	Ulna ( $n$ )	Total nos. $n \geq 1$ measurements available
Undetermined sex	160.6 (10)		163.8 (6)			12
Male–Male?	161.9 (41)	165.6 (1)	167.4 (28)	168.4 (5)	176.7 (2)	48

Table 21. Paleopathology ( $U = \text{unobservable}$ ).

Skel. no.	Row	Porotic hyperostosis	Periostitis	Degenerative joint disease (incl. osteophytosis)	Enthesophytes
1245	1	U	U	U	U
1201	1	U	U	U	U
1202	1	U	U	U	U
1253	1	U	U	U	U
1215	1	U	U	U	U
1247	1	U	U	U	U
1266	1	U	U	Clavicle, left: porosity and osteophytes on the medial epiphysis. Osteoarthritis.	U
1296	1	U	U	U	U
1297	1	U	U	U	U
1342	1	U	U	U	U
1343	1	U	U	U	U
1325	1	U	U	U	U
1379	1	U	U	U	U
1380	1	Parietal, right: indistinct porosity—true porosity on the right parietal.	U	U	U
1381	1	U	U	U	U
1360	1	U	U	U	U
1358	1	U	U	U	U
1289	1	Occipital: indistinct porosity.	U	U	U
1324	1	U	U	U	U
1328	1	U	U	U	U
1359	1	U	U	U	U
1363	1	U	U	U	U
1364	1	U	U	U	U
1365	1	U	U	U	U
1350	1	U	U	U	U
1348	1	U	U	U	U
1281	1	U	U	U	U
1349	1	U	U	U	U
1374	1	U	U	U	U
1376	1	U	U	Vertebral column: slight lipping anterior on thoracic vertebrae nos. 1–4.	U
1375	1	U	U	U	U
1361	1	U	U	Vertebral column: medium lipping on thoracic vertebral bodies, lumbar vertebra no. 5 and on sacrum-promotorium.	U
1366	1	U	Tibia, right: healed periostitis on the distal diaphysis, medial border.	U	U

Table 21 continued.

Skel. no.	Row	Porotic hyperostosis	Periostitis	Degenerative joint disease (incl. osteophytosis)	Enthesophytes
1318	1	U	U	U	U
1336	1	Parietal: pinpoint porosity—healed; Occipital: pinpoint porosity—healed.	U	U	U
1392	1	U	U	U	U
1393	1	U	Tibia, left: healed periostitis on the proximal–middle diaphysis, medial border.	U	
1355	1	Parietal, right: pinpoint porosity on dorsal part on the parietal, hypertrophy of the diploë.	U	U	Fibula, left: entesophyte on the distal diaphysis.
1373	1	U	U	Vertebral column: medium lipping on two thoracic bodies; Lower limbs, left patella: slight lipping.	U
1354	1	U	U	Vertebral column: medium lipping on cervical vertebrae nos. 3–7.	U
1353	1	U	U	U	U
1382	1	U	U	U	U
1383	1	U	U	U	U
1356	1	Parietal, right: indistinct—true porosity near the saggital suture; Frontal: very indistinct porosity close to the coronal suture. Occipital: indistinct—true porosity close to the saggital suture.	U	U	U
1390	1	U	U	Vertebral column: significant osteophytosis on three lower thoracic vertebral bodies—beginning to form a block; significant osteophytosis on lumbar vertebra no. 5.	U
1339	1	U	U	U	U
1340	1	Parietal, left: true porosity on posterior parietal, close to the lambdoid suture; Occipital, left: indistinct porosity on part of the occipital, close to the lambdoid suture.	U	U	U
1267	2	U	U	U	U
1298	2	U	U	U	U
1268	2	U	U	U	U
1269	2	Parietals: very indistinct porosity on the posterior part, more pronounced on the right parietal, close to the saggital suture.	U	U	U
1370	2	Parietals: indistinct porosity—true porosity on posterior parts; Occipital: indistinct porosity near the lambdoid suture; Frontal: indistinct porosity; Temporal, left: indistinct porosity above the meatus.	U	U	U

Table 21 continued.

Skel. no.	Row	Porotic hyperostosis	Periostitis	Degenerative joint disease (incl. osteophytosis)	Enthesophytes
1351	2	U	U	U	U
1389	2	Parietal, right: indistinct porosity close to the lambdoid suture; Occipital: indistinct porosity close to the lambdoid suture.	U	U	U
1371	2	Parietal, right: indistinct porosity close to the lambdoid suture.	U	U	U
1357	2	Parietals: true porosity close to the sagittal suture; Occipital: true porosity—coalescing pores on the left occipital, close to the lambdoid suture.	U	U	U
1369	2	Parietals: indistinct porosity on the posterior parietals close to the lambdoid suture; Occipital: indistinct porosity close to the lambdoid suture.	U	U	Humerus, right: enthesophytes on the distal diaphysis.
1228	2	U	U	U	U
1386	2	Parietals: indistinct porosity on the left parietal, close to the sagittal suture, true porosity on the right parietal, close to the sagittal suture; Frontal: indistinct porosity on the posterior frontal close to the coronal suture; Occipital: indistinct porosity close to the lambdoid suture.	U	U	U
1368	2	U	U	Vertebral column—lumbar vertebral bodies: L1—body destroyed, not observable; L2 (inferior) medium osteophytes; L3 (superior) large osteophytes almost fused with L2; L4—largely destroyed; L5—superior medium—large osteophytes, inferior—minimal osteophytes.	U
1388	2	U	U	U	U
1387	2	U	U	U	U
1397	2	U	U	U	U
1285	3	U	U	U	U
1277	3	U	U	U	U
1276	3	U	U	U	U
1275	3	U	U	U	U
1271	3	U	U	U	U
1272	3	U	U	U	U
1294	3	U	U	U	U
1316	3	U	U	U	U
1332	3	U	U	U	U
1384	3	U	U	U	U
1385	3	U	U	U	U
1333	3	Parietals: indistinct porosity close to the sagittal suture only.	U	U	U

Table 21 continued.

Skel. no.	Row	Porotic hyperostosis	Periostitis	Degenerative joint disease (incl. osteophytosis)	Enthesophytes
1344	3	Parietals: indistinct porosity—true porosity.	U	U	U
1398	3	U	U	U	U
1400	3	U	U	U	U
1399	3	U	U	U	U

Table 22. Paleopathology (n = number of individuals; OA = osteoarthritis).

Row	PH (n)	%	Periostitis (n)	%	Osteophytes (n)	%	OA (n)	%	Enthesophytes (n)	%
1	6/47	12.8	2/47	4.2	6/47	13	1/47	2.1	1	2
2	7/16	48	0	0	1/16	6	0/16	0	1	6
3	2/16	12.5	0	0	0/16	0	0/16	0	0	0
<b>Total</b>	<b>15/79</b>	<b>19</b>	<b>2/79</b>	<b>2.5</b>	<b>7/79</b>	<b>8.9</b>	<b>1/79</b>	<b>1.3</b>	<b>2/79</b>	<b>2.5</b>



Fig. 32. No. 1355, expanded diploë, right parietal.



Fig. 33. No. 1340, porosities, left parietal, left occipital.

ern populations. In this material, signs of DJD and OA was identified in seven individuals (9%).

Osteoarthritis (OA) shows as lipping/bony spurs or osteophytosis at the margins of joints in connection with porosity on the joint surface and/or eburnation.<sup>66</sup> It is a progressive, chronic condition resulting from loss of joint cartilage causing bone-to-bone contact, which stimulates new bone formation.<sup>67</sup> OA has been often associated with behavioural factors such as the amount and type of physical activity undertaken.<sup>68</sup>

Osteophytes, when observed in isolation, without signs of porosity and/or eburnation cannot be considered as OA.<sup>69</sup> Joint changes in the form of marginal osteophytes/lipping, especially in the spine, is one of the most normal outcomes of

the ageing process, they are usually uncommon in individuals below 30 years of age.<sup>70</sup> It seems possible, however, that certain activity patterns are a risk factor for the development of osteophytes, i.e. a radiographic study of former elite athletes showed that individuals involved in the throwing disciplines, as well as high jumpers, had a higher risk of developing osteophytosis in the lumbar vertebrae in comparison to runners and other jumpers.<sup>71</sup>

Osteophytes were most commonly noticed in Row 1; only one individual in Row 2 (and none in Row 3) show this lesion. Osteophytes were most commonly found in the vertebral column, especially on the thoracic and lumbar vertebral bodies. Since osteophytosis is usually connected with the ageing process it is interesting to note that two of six individuals identified with osteophytosis were young adults (YA), one

<sup>66</sup> Buikstra & Ubelaker 1994, 122.

<sup>67</sup> Aufderheide & Rodrigues-Martin 1998, 93, 97.

<sup>68</sup> Weiss 2006; Weiss & Jurmain 2007.

<sup>69</sup> Rogers & Waldron 1995, 26.

<sup>70</sup> Aufderheide & Rodrigues-Martin 1998, 96.

<sup>71</sup> Schmitt *et al.* 2004.

Table 23. Nonmetric traits (*n* = number of traits recorded).

	Inca bone	Bregmatic bone	Apical bone	Metopic suture	Wormian bones (sutural ossicles)	Other	Total
Row 1	1	0	0	0	2	0	3
Row 2	1	2	1	2	3	1	10
Row 3	0	0	0	2	4	1	7
<b>Total</b>	<b>2</b>	<b>2</b>	<b>1</b>	<b>4</b>	<b>9</b>	<b>2</b>	<b>20</b>

individual could be determined only as “adult”, whereas three individuals were estimated as middle adults (MA). One individual (no. 1266), a young adult male in Row 1, shows OA on the medial epiphysis of the left clavicle.

Enthesophytes shows as bony projections or irregularities at the insertion of tendons and ligaments which may develop as an effect of prolonged and inordinate muscular wear or due to an inflammation, but they can also develop without a known cause.<sup>72</sup> Although both osteophytes and enthesophytes are often a skeletal response to stress, some individuals may be more prone to “bone formation”.<sup>73</sup> Two individuals, both determined as young adults, in Row 1 and Row 2 (nos. 1355 and 1369), show small enthesophytes on the upper arm (humerus) and on the lower leg (fibula).

Periostitis, or periosteal new bone formation is one of the most commonly reported pathological lesions in archaeological human skeletal remains. Although any bone in the skeleton may be affected, the long bones, particularly the tibiae, most often show this lesion.<sup>74</sup> Periostitis is a reaction to a pathological stimuli or a secondary reaction to trauma; it first appears as “woven bone formation” seen as a porous-like appearance on the outer surface of the bone which, when healed, becomes remodelled and incorporated into the cortex and show as lamellar bone-striations on the outer bone surface. The aetiology of periosteal reactions are rarely possible to differentiate in archaeological skeletons.<sup>75</sup> Two individuals in Row 1 show periostitis on the tibiae (nos. 1366 and 1393); in both cases the periostitis was healed. Since no other pathologies were found on these individuals, it seems possible that the periostitis resulted from a skin ulcer on their legs. It should be noted, however that only the lower part of the skeleton of no. 1393 was present.

<sup>72</sup> Larsen 1997, 188; Rogers *et al.* 1997.

<sup>73</sup> Rogers *et al.* 1997.

<sup>74</sup> Weston 2012.

<sup>75</sup> Ortner & Putschar 1985, 129–132.

## NONMETRIC TRAITS

Nonmetric traits result from ossification failure or non-pathological abnormal bone formation often visible as small extra bones located in cranial sutures, extra foramina, bony bridges, etc.<sup>76</sup> Cranial nonmetric traits have long been used in population studies of biological distance since they show some heritability, although environmental factors may also play a role in their development.<sup>77</sup>

Fifteen individuals exhibit at least one nonmetric trait on the cranium and one individual showed a postcranial trait. Thirteen of 16 (81%) individuals with recorded nonmetric traits were found in Rows 2 and 3. However, since it was not possible to record the presence or absence of nonmetric traits on all skeletons, theories regarding a possible genetic relationship between individuals cannot be suggested.

The most frequently observed nonmetric traits were wormian bones ( $n = 9$ ) followed by the metopic suture ( $n = 4$ ); all of them most commonly noted on individuals in Rows 2 and 3 (Table 23, Fig. 34). Bregmatic bones, inca bones, and an apical bone were also noted. Other nonmetric traits observed includes enlarged parietal foramina (no. 1344, Row 3, Fig. 35) and in one case a postcranial trait, so-called Allen’s fossa (no. 1269, Row 2, Fig. 36). Allen’s fossa shows as a depression exposing the underlying trabeculae on the superior anterior neck of the femur.<sup>78</sup> This trait, along with other similar depressions on other parts of the skeleton (e.g. humerus, clavicle) has often been noted on young adults, especially males, who carried out strenuous activities e.g. soldiers.<sup>79</sup>

## TRAUMA

### Introduction

Skeletal trauma is a broad category that includes partial or complete fractures, dislocation of joints, disruption to the nerve or blood supply, and plastic deformation of the bone contour.<sup>80</sup>

Numerous breaks were observed on the skeletons in the mass graves. Since the skeletons *in situ* were not fully exposed, interpretations regarding *perimortem* contra *postmortem* fractures are tentative and in most cases based on fracture patterns: only rarely were fracture margins possible to observe. The interpretations of fractures and trauma should therefore be regarded as probability statements.

<sup>76</sup> Buikstra & Ubelaker 1994, 85.

<sup>77</sup> Pink 2016, 225.

<sup>78</sup> Buikstra & Ubelaker 1994, 94.

<sup>79</sup> Mann & Hunt 2005, 144.

<sup>80</sup> Ortner 2003, 119.



Fig. 34. No. 1389, wormian bones.



Fig. 36. No. 1269, Allen's fossa.

Here only partial or complete fractures to the skeletons were observed. Following established forensic practices the fractures were divided in to three groups: (1) *antemortem* fractures to fresh or green bone with evidence of healing that would have occurred before death, (2) *perimortem* fractures to green bone without evidence of healing, and (3) *postmortem* fractures to dry bone.

In this material, *antemortem* fracture was identified in one individual (no. 1297 in Row 1, Fig. 37). Signs of remodelling at the fracture site characterize *antemortem* fractures. Although the healing process starts almost immediately after injury, the first signs of remodelling (rounded fracture margins) in skeletonized remains is earliest visible a week after the injury took place. The healing process progresses gradually until complete remodelling of the bone takes place.<sup>81</sup> The time for this process is highly variable and dependent on several factors including age, type of fracture, earlier health status of the in-

<sup>81</sup> Lovell 1997; Sauer 1998.



Fig. 35. No. 1344, enlarged parietal foramina.

dividual, etc. Secondary infections could also be incorporated in the *antemortem* process, also including signs of new bone formation or bone resorption.<sup>82</sup>

*Perimortem* fractures, identified in 14 (likely *perimortem* fracture)/25 (possible *perimortem* fracture) cases, are characterized by fractures to “wet” or “green” bone when no remodelling at the fracture site is present.<sup>83</sup> Though most *perimortem* fractures are believed to be associated with the time of death of the individual, the time span for the *perimortem* period is highly variable since bones can retain their elasticity for several weeks, sometimes even months after death depending on the burial environment.<sup>84</sup> A number of macroscopic criteria can aid the interpretation of *perimortem* fractures. For example, fracture edges often have the same colour as the rest of the bone, staining may be present, and fracture lines are

<sup>82</sup> Ortner & Putschar 1985, 63–65; Ubelaker & Montaperto 2014, 30–34.

<sup>83</sup> Kimmerle & Baraybar 2008, 57.

<sup>84</sup> White *et al.* 2012, 460; Rodriguez-Martin 2006; Maples 1986, 219.



Fig. 37. No. 1297, antemortem trauma to the left parietal.

often smooth and the fracture margin bevelled, with ragged edges less common.<sup>85</sup> Skull fractures (in the case of blunt force trauma) often show bone fragments attached to the site of injury (so called hinge fractures) with radiating fracture lines and/or concentric fracture lines rarely crossing the sutures.<sup>86</sup> In archaeological contexts, it is often impossible to determine a cause, i.e. whether *perimortem* fractures resulted from accidents, intentional violence, or during burial/deposition of the body.<sup>87</sup>

*Postmortem* destruction of dry bones was identified on a majority of the individuals. These fractures result from a wide range of taphonomic factors (e.g. *postmortem* handling of bodies, soil pressure, burial environment, rodent gnawing, excavation damage, weathering, etc.). The fracture margins are often dry and ragged, and because of the biomechanical properties of bone and the loss of elasticity, bones tend to shatter into smaller fragments. The fracture margins are lighter than the rest of the bone and fractures are often produced in a transversally longitudinal axis, or in sharp angles. Radiating fractures and concentric fracture shapes with adhering bones are less common.<sup>88</sup>

### Methods to document trauma

In archaeological contexts, even more than in forensic settings, differentiation between *perimortem* fractures and *postmortem* breakage is often difficult, sometimes impossible.<sup>89</sup> Observations regarding colour and shape of fracture margins, fracture pattern morphology/angle of fracture margins, burial context, signs of weathering or excavation damage, etc., are

commonly used criteria to analyse and aid interpretations regarding the nature/category of fractures. Taphonomic factors may create pseudo-fractures mimicking *perimortem* trauma, but *postmortem* fractures can also hide *perimortem* trauma.<sup>90</sup> An osteological analysis under laboratory conditions including observation of fracture margins and refitting of fragments is often necessary to enable cognisant interpretation regarding the prevalence of *perimortem* contra *postmortem* fractures.

Trauma was documented through ocular inspection. Photographs were taken but individual sketches of fracture pattern were not possible owing to the short time available for field documentation. Additionally, the photographs available are in many cases not clear enough for a reliable view of fracture patterning due to lack of time and lighting conditions at the site.

The *perimortem* fractures were divided in two groups, “likely *perimortem* fracture” (LPF) and “possible *perimortem* fracture” (PPF). This division was inevitably subjective and based only on observations of fracture patterning and fracture morphology characteristics. Furthermore, the division was influenced by bone preservation, e.g. the extent of *postmortem* destruction associated with LPF and PPF. When extensive *postmortem* fragmentation was found in connection with, or partially obscuring the suspected *perimortem* fractures, or when radiating fracture lines could not be observed, the injuries were considered as PPF.

### Results of the trauma analysis

The only case of *antemortem* trauma was observed on a young adult of undetermined sex in the northern part of Row 1 (no. 1297). This individual exhibited a completely healed oval-shaped wound (3 x 4.5 cm) on the posterior part of the left parietal, close to the sagittal suture (Fig. 37). The injury was most likely caused by blunt force impact resulting in a depressed cranial fracture. A differential diagnosis is trepanation (i.e. an intentional removal of a piece of the skull by methods of scraping, drilling, or cutting).<sup>91</sup>

### Likely *perimortem* fractures (LPF)

LPF were noted only on the crania and/or on the lower jaws in 14 of the 79 individuals (18%) (Table 24, Figs. 38–51). All LPF appear to have resulted from blunt force trauma (BFT) and follow (to the extent it was possible to document) the criteria outlined by Nancy C. Lovell and others.<sup>92</sup>

<sup>85</sup> Krovitz & Shipman 2007; Byers 2008, 286–287; Rodríguez-Martín 2006.

<sup>86</sup> Kranioti 2015; Krovitz & Shipman 2007.

<sup>87</sup> Dirkmaat *et al.* 2008, 42.

<sup>88</sup> Galloway *et al.* 2014, 49–55; Krovitz & Shipman 2007.

<sup>89</sup> Ortner & Putschar 1985, 72; Maples 1986, 221.

<sup>90</sup> Calce & Rogers 2007; Galloway *et al.* 2014, 49–55.

<sup>91</sup> Trepanations are known to have been carried out at least from the Mesolithic–Neolithic and the procedure is mentioned by e.g. Hippocrates and Galenos as a method of treating or relieving head trauma, Liston & Day 2009.

<sup>92</sup> Lovell 1997; Rodríguez-Martín 2006; Galloway *et al.* 2014, 49–55; DiMaio & DiMaio 2001, 148–155.

Table 24. Description of fractures. Likely perimortem fracture (LPF) and possible perimortem fracture (PPF) (BFT = blunt force trauma; HBL = the so-called rule of the "hat brim line", see below, p. 73).

Skel. no.	Row	Likely perimortem fracture (LPF)	Fig. no.	Possible perimortem fracture (PPF)	Fig. no.	Posture
1245	1	U		U		Supine
1201	1	U		U		Supine
1202	1	U		U		Supine, inclined on the left side
1253	1	U		U		Supine
1215	1	U		U		Prone
1247	1	U		U		Prone
1266	1	U		U		Supine
1296	1	Left mandible, anterior body: a vertical, slightly oblique BFT fracture to the left mandibular body between the left and the right I1, at mentum. The simple fracture line is smooth, with slightly jagged edges at the superior part. The left I2 and C tooth crowns are missing, probably fractured <i>antemortem</i> or <i>perimortem</i> .	38	U		Supine, skull resting on right side
1297	1	U		U		Lateral, on right side
1342	1	U		U		Prone
1343	1	U		U		Lateral, on left side (face almost prone)
1325	1	U		U		Prone
1379	1	U		U		Lateral, on left side (face almost prone)
1380	1	U		Right temporal, a depressed comminuted fracture to the anterior and posterior part of the squama. The fracture is within the HBL. Radiating fracture lines on the right parietal stopping at the coronal suture. There are also fractures on the right frontal that are not connected with fracture lines on the parietal.	67	Lateral, on left side
1381	1	U		Right temporal, involving also parts of the right parietal and the right lateral frontal: a depressed comminuted almost concentric fracture to the right temporal squama. No radiating fracture lines observed. The fracture is within the HBL.	68	Supine, skull resting on left side
1360	1	U		U		Prone
1358	1	U		U (Skull lifted, no trauma visible).		Supine
1289	1	U		U		Lateral, on right side
1324	1	U		Left mandible, body: a vertical, slightly curved fracture between the left PM1 and PM2, some flaking due to <i>postmortem</i> destruction is present close to the fracture margin. Left temporal, left sphenoid, and part of the lateral left parietal: a depressed comminuted fracture to the left temporal squama, sphenoid, and lateral parietal. The fracture margin is largely smooth, although there is some <i>postmortem</i> destruction as well, with light margin. The fracture is within the HBL. There are very fine radiating fractures on the parietal.	52	Supine, skull resting on right side

Table 24 continued.

Skel. no.	Row	Likely <i>perimortem</i> fracture (LPF)	Fig. no.	Possible <i>perimortem</i> fracture (PPF)	Fig. no.	Posture
1328	1	U		Right temporal, right sphenoid, and the lateral part of the right parietal: a depressed comminuted fracture to the temporal squama, sphenoid, and lateral part of the parietal. The fracture margin is smooth on the postero-lateral part of the parietal and there is <i>postmortem</i> destruction at the fracture margin on the antero-lateral part of the parietal. One fine radiating fracture line is present on the posterior part of the parietal. The fracture is within and slightly above the HBL. Right mandible, body: a depressed comminuted fracture with a slightly curved, vertical fracture margin on the anterior part of the ramus, anterior to the angulus. The fracture is largely limited to the outer table and the cancellous bone.	53	Supine (slightly on the left side)
1359	1	Right temporal: a depressed comminuted fracture to the anterior temporal squama and the sphenoid and two associated concentric fractures to the parietal. Three fine fracture lines radiate from the concentric fracture on the right parietal. The fracture is within the HBL. <i>Postmortem</i> fragmentation is visible at the posterior part of the squama; Left mandible: a vertical fracture below the left C that extends laterally and sets off in a horizontal-lateral direction forming a sharp angle on the lower part of the body. The fracture line is largely smooth with dark margins.	42			Supine-lateral on left side, skull resting on left side
1363	1	U		Right temporal, right sphenoid, right parietal, and right frontal: a depressed comminuted fracture to the right temporal squama, right sphenoid, the lateral margin of the parietal, and the lateral part of the frontal. The fracture margins are largely ragged and partly light in colour. The fracture is within and slightly above the HBL. A radiating fracture line extends from the posterior of parietal to the occipital, intersecting the lambdoid suture. A smooth hemispherical fracture margin on the postero-lateral part of the frontal; fracture margins are dark with fine fracture lines radiating on the frontal.	61	Prone
1364	1	U		Right temporal, right sphenoid, lateral part of the right parietal, and the right lateral part of the frontal: a large depressed comminuted fracture to the squamous part of the temporal, and sphenoid. Faint fracture lines radiate to the frontal and the parietal. The fracture is within and slightly above the HBL. Right mandible: an oblique fracture to the mandibular body, between the right I2 and C. The fracture margin is smooth, slightly curved with no jagged edges.	63	Supine
1365	1	U		Right mandible, body: a single vertical slightly oblique fracture inferior to the right I2.	62	Supine
1350	1	U		U		Supine, skull inclined on the right side
1348	1	U		Left mandible, body: a single oblique slightly curved fracture to the left mandibular body, between the left C and PM1. The edges are slightly ragged. Left femur, neck: an oblique slightly curved interthrochanteric oblique fracture on the femoral neck. Fracture margins were difficult to observe.	54–55	Supine

Table 24 continued.

Skel. no.	Row	Likely <i>perimortem</i> fracture (LPF)	Fig. no.	Possible <i>perimortem</i> fracture (PPF)	Fig. no.	Posture
1281	1	U		U		Supine, skull resting on right side
1349	1	U		Right temporal, right parietal, and right sphenoid: a depressed comminuted fracture on the temporal squama, posterior part of parietal, and the sphenoid. The fracture shows a slightly concentric outline with fracture margins somewhat ragged and varying in colour from dark to light. No radiating fractures were observed. The fracture is within and slightly above the HBL. Left mandible, body: an oblique fracture with slightly jagged edges to the left mandibular body, at PM2.	56–57	Supine
1374	1	Right mandible: an oblique fracture to the mandibular body, between the right C and the right PM1. The fracture line is smooth.	44	Right temporal, right sphenoid: a depressed comminuted fracture to the anterior temporal squama and the right sphenoid with a radiating fracture to the right parietal. The fracture is within and slightly above the HBL. Left mandible, body: an oblique fracture to the mandibular body between the right C and right PM1. The fracture line is partly smooth but with partly ragged edges.	65	Supine
1376	1	U		U		Supine (skull and upper body) lateral on right lower body
1375	1	U		Left mandible, body: a vertical largely smooth fracture with some ragged edge between the left I2 and the right I1. There is some fragmentation on the superior part of the alveoli.	66	Supine, skull resting on the right side
1361	1	U		Right temporal, right sphenoid, and lateral part of the right frontal: a comminuted almost concentric fracture to the temporal squama, sphenoid, and lateral part of the frontal with radiating fractures to the frontal and the right supraorbital margin. The fracture is within the HBL.	60	Supine (cranium resting on left side)
1366	1	U		Left temporal, left sphenoid: a depressed comminuted fracture to the sphenoid and the temporal squama with two faint circular fracture lines on the left frontal and left parietal. The fracture is within the HBL. Right sphenoid: a depressed fracture with faint concentric fractures on the parietal. The fracture is within the HBL.	64	Supine
1318	1	U		U		Supine
1336	1	Right temporal, right sphenoid, and the lateral-posterior part of the right frontal: a depressed comminuted fracture with largely smooth hemispherical fracture margin. The fracture is within, and slightly above the HBL. The colour of the fracture margin varies from dark to light; some <i>postmortem</i> destruction was found in the middle part of the fracture. There are two associated concentric fracture lines on the right parietal with four radiating fracture lines between the concentric fractures. Right mandible, body: a vertical, slightly curved fracture between the right I2 and the right C. The fracture line is smooth, with some jagged edges due to <i>postmortem</i> destruction at the alveolar margin. The smooth fracture margin is dark in colour.	39	U		Lateral (on left side)

Table 24 continued.

Skel. no.	Row	Likely <i>perimortem</i> fracture (LPF)	Fig. no.	Possible <i>perimortem</i> fracture (PPF)	Fig. no.	Posture
1392	1	U		U		Supine
1393	1	U		U		Supine
1355	1	U		U		Lateral (on left side)
1373	1	Right temporal, right sphenoid: a depressed comminuted fracture with a concentric fracture margin to the sphenoid and anterior temporal squama, two radiating fracture lines on the right parietal. The fracture is within the HBL.	43	U		Supine (cranium slightly inclined to the left side)
1354	1	U		U		Supine
1353	1	Right parietal/right sphenoid: a large depressed comminuted fracture with concentric fracture lines to the right parietal. The fracture is within the HBL. Right zygomatic, below the frontal process: a horizontal/oblique fracture with a smooth fracture line. The fracture is within the HBL. Right frontal, superior to the supraorbital margin on the lateral part of the orbit close to the zygomatic process: a small circular depressed comminuted fracture only penetrating the outer table. An oblique fracture line is radiating out from the superior part of the frontal, the fracture line stops at the coronal suture. The fracture is within the HBL. Right frontal: above the supraorbital margin right to glabella: a small depressed fracture, oval-square shaped and limited to the outer table with one radiating fracture line stopping at the coronal suture. The fracture is within the HBL. The fracture line is slightly curved with parts of the fracture margin slightly ragged due to <i>postmortem</i> destruction.	40	Right mandible: a vertical fracture between the right I1 and the right I2. The fracture margins are dark but the fracture line is slightly ragged. Left femur: a sharp oblique intertrochanteric fracture to the left femoral neck above the lesser trochanter.	58–59	Supine
1382	1	U		U		Supine, skull inclined to the left side
1383	1	Right temporal, right sphenoid: a comminuted depressed fracture to the right anterior temporal squama and the right sphenoid associated with concentric fractures on the right parietal and posterior frontal-zygomatic arch. Radiating fractures are found on the right frontal and the right parietal. The fracture is within the HBL. Left frontal: a slightly oblique fracture with smooth margin extending from the supraorbital margin, the oblique fracture is crossed by a transverse fracture extending laterally towards the right orbit. The fracture is within the HBL. Right maxilla: a small depressed comminuted fracture to the infraorbital foramen, oval with smooth fracture margins. Left mandible: a vertical, slightly curved complete fracture to the mandibular body between the left I1–I2. The lower part of the fracture margin show slightly ragged fracture edges probably due to <i>postmortem</i> destruction.	45	Right femur: an intertrochanteric fracture with an oblique fracture line extending from the greater trochanter to the medial part of the proximal diaphysis. The fracture line is smooth. No displacement visible.	69	Supine, skull resting on the left side

Table 24 continued.

Skel. no.	Row	Likely <i>perimortem</i> fracture (LPF)	Fig. no.	Possible <i>perimortem</i> fracture (PPF)	Fig. no.	Posture
1356	1	Right temporal, right sphenoid: a depressed comminuted fracture to the anterior squama and the sphenoid with an associated concentric fracture on the right parietal and radiating faint fractures. The concentric fracture line stops at the lambdoid suture. The fractures are within the HBL. Right mandible: a comminuted fracture to the mandibular ramus, the fracture lines extend from the mandibular notch below the coronoid process. The fracture margins are largely smooth but slightly jagged on the inferior part. Right mandible: a vertical fracture to the right mandibular body below the right C. The fracture line is largely smooth but the inferior part of the fracture is slightly curved and jagged.	41			Lateral (on left side)
1390	1	Right mandible: an oblique complete fracture to the right mandibular body with smooth fracture margins between the right C and right PM1.	46	Right second metacarpal and right third metacarpal: a transverse fracture to the middle diaphyses. The fracture margins are unobservable.	70	Supine
1339	1	U		U		Lateral (on right side)
1340	1	U		U		Lateral (on right side)
1267	2	U		Left temporal, left sphenoid: a depressed comminuted fracture to the sphenoid and anterior part of the temporal squama; no concentric fracture lines were observable. Some of the depressed fragments show light margins consistent with <i>postmortem</i> destruction. A possibly associated transverse fracture was noted on the left frontal, extending from the left part of the coronal suture to the metopic suture. The fracture is within the HBL. Right mandible: an oblique fracture to the right mandibular body at C, the inferior part of the fracture line show <i>postmortem</i> destruction with ragged edges. There is also a horizontal crack on the right mandibular ramus with partly sharp and ragged fracture margin indicating <i>postmortem</i> destruction.	71–72	Supine
1389	2	U		U		Supine (cranium resting on left side)
1268	2	U		U		Lateral (on right side)
1269	2	Left mandible: a vertical, slightly oblique fracture to the mandibular body between the I2 and the C. The margin is largely smooth, with slightly jagged edges below the alveolar margin.	47	U		Supine
1370	2	U		U		Prone (cranium slightly on the right)
1351	2	U		U		Prone (cranium slightly on the left)
1389	2	U		Right mandible, ramus: an oblique fracture with smooth outline extending from the the coronoid process to the angulus.	73	Lateral (on left side)
1371	2	U		U		Supine (slightly on left side)

Table 24 continued.

Skel. no.	Row	Likely <i>perimortem</i> fracture (LPF)	Fig. no.	Possible <i>perimortem</i> fracture (PPF)	Fig. no.	Posture
1357	2	U		Left mandible: an oblique comminuted fracture to the left mandibular ramus. The fracture line extends from the posterior part of the coronoid process to the middle lateral part of ramus.	75	Lateral (on right side)
1369	2	U		Left mandible: an oblique fracture to the mandibular body, between the left I2 and PM1. The fracture line seems smooth but was very difficult to observe because of the incrustations of soil firmly attached to the mandible at the fracture site.	74	Prone (cranium slightly on the right)
1228	2	U		U		Lateral (on the right side)
1386	2	Right mandible: a hemispheric fracture to inferior part of the coronoid process with a radiating fine oblique fracture line extending to the angulus.	48	Right temporal, right sphenoid, right lateral parietal, and the right lateral frontal: a depressed comminuted fracture with one partly smooth concentric fracture line on the right parietal and the posterior temporal. The fracture is within and slightly above the HBL. <i>Postmortem</i> fragmentation is also present, particularly on the frontal and on the parietal.	48	Lateral (on the left side)
1368	2	U		U		Lateral (on the left side)
1388	2	U		Right temporal, right sphenoid, and right parietal: a depressed comminuted fracture to the sphenoid and the anterior part of the temporal squama. Some <i>postmortem</i> destruction and fragmentation with light fracture margins is also visible at the fracture site. A concentric fine fracture line is present on the right parietal, no radiating fracture lines were observed. The fracture is within the HBL. Right mandible: a vertical fracture to the mandibular corpus posterior to the M3. The fracture margin is largely smooth. Right mandible: an oblique fracture to the mandibular body between the right and the left I1. The superior part of the fracture line is smooth with some slightly ragged edges at inferior part of the fracture line possibly due to <i>postmortem</i> destruction. Left femur, distal 1/3 of the diaphysis: an oblique complete fracture with smooth outline.	77-78	Lateral (on the left side)
1387	2	U		Right mandible: a vertical, slightly curved fracture to the mandibular body inferior of the right C and right I2. A connecting (incomplete) transverse and slightly curved fracture line radiates from the vertical fracture on the inferior part of the body towards the posterior part.	76	Lateral (on left side)
1397	2	U		U		Lateral (on right side)
1285	3	U		U		Lateral (on left side)
1277	3	U		U		Lateral (on left side)
1276	3	U		U		Lateral (on left side)
1275	3	U		U		Supine (cranium slightly on left side)

Table 24 continued.

Skel. no.	Row	Likely <i>perimortem</i> fracture (LPF)	Fig. no.	Possible <i>perimortem</i> fracture (PPF)	Fig. no.	Posture
1271	3	U		Right temporal, right sphenoid, right zygomatic, and lateral part of the right parietal and right lateral frontal: a depressed comminuted fracture with one partly smooth concentric fracture line on the right parietal. The fracture is within and above the HBL. <i>Postmortem</i> fragmentation is also visible at the site with some light and ragged edges.	79	Supine (postcranial skeleton on the left)
1272	3	Right parietal: a small a depressed comminuted fracture with concentric fracture margin to the posterior part of the parietal, next to the sagittal suture. Two faint radiating fracture lines meet with a complete transverse fracture across the right parietal (possibly <i>postmortem</i> ). The fracture is within the HBL.	49	U		Supine (cranium on left side)
1294	3	U		U (crust covers large part of the cranium).		Prone
1316	3	Left parietal, left temporal, left sphenoid: an extensive depressed comminuted fracture to the right lateral part of the parietal, the temporal squama, and the left sphenoid. The parietal fracture is slightly concentric with a smooth fracture margin. Several radiating fracture lines extend across the left parietal. The fracture extends within and above the HBL.	50			Lateral (on right side)
1332	3	U		U		Supine (cranium on left side)
1384	3	U		U		Supine (cranium on left side)
1385	3	U		U		Lateral (on right side)
1333	3	Left frontal: a vertical fracture extends from the supraorbital margin in association with a small depressed fracture (one small depressed bone flake). A faint oblique fracture line radiates from the fracture on the supraorbital margin and stops at the coronal suture. The fracture is located above the HBL.	51	Right mandible, body: an oblique fracture of the mandibular body extending from the right I2. The superior part of the the fracture is largely smooth although ragged edges are noted on the inferior part, possibly due to <i>postmortem</i> destruction. There is also a vertical incomplete fracture line visible on the mandibular body posterior and inferior to the right M3. This fracture is possibly connected to the oblique fracture in a horizontal plane but due to incomplete excavation the relation between the fracture lines could not be observed.	80	Supine (cranium slightly inclined to the left side)
1344	3	U		U		Prone (cranium slightly on the right)
1398	3	U		U		Lateral (on right side)
1400	3	U		U		Prone
1399	3	U		U		Lateral (on left side)

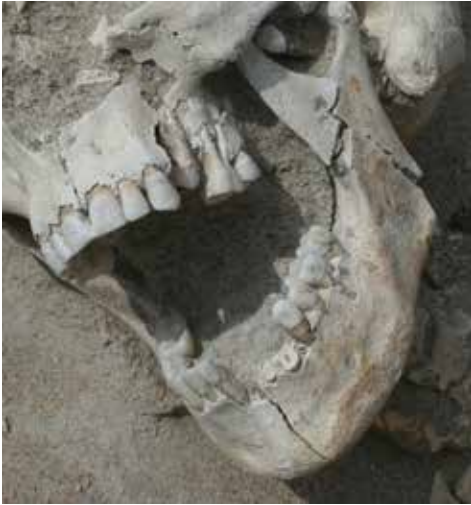

Fig. 38. No. 1296, LPF, left mandible.



Fig. 39. No. 1336, LPF, right temporal and right mandible.



Fig. 40. No. 1353, LPF, right parietal, right zygomatic, right frontal.

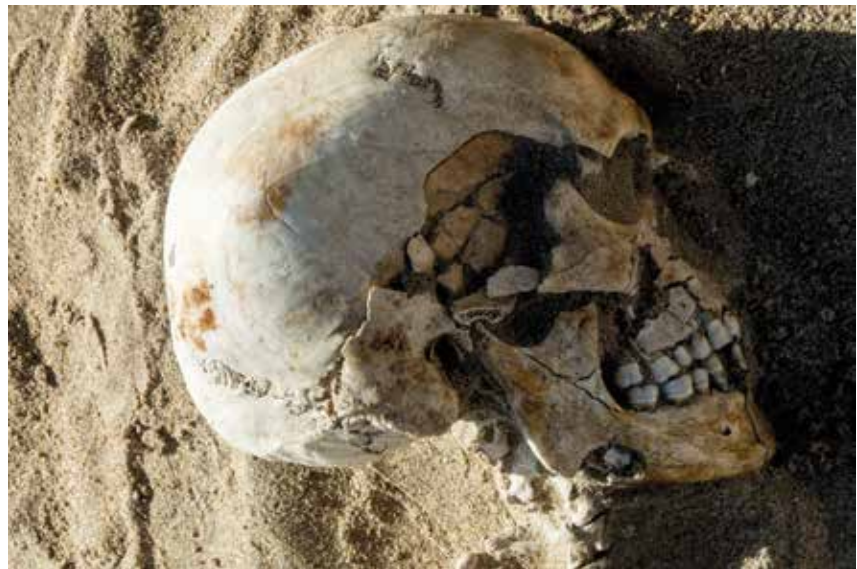

Fig. 41. No. 1356, LPF, right temporal, right sphenoid, right mandible.

Nine of 47 individuals (18%) in Row 1 show LPF fractures to the cranium and/or to the lower jaw (Figs. 38–46), whereas in Row 2, two of 16 individuals (12%) show LPF only to the lower jaw (Figs. 47–48). In Row 3, LPF were found on the crania in three of 16 individuals (19%) (Figs. 49–51).

LPF to the mandible were found on 11% ( $n = 79$ ) of the individuals: 15% ( $n = 47$ ) in Row 1 and in 12% ( $n = 16$ ) in Row 2. A majority of the mandibular fractures were single anterior or unilateral fractures to the symphyseal/parasymphyseal area, or to the mandibular body. Two individuals exhibited ramus fractures, one of which was found in connection with a

parasymphyseal fracture (no. 1356 in Row 1, Fig. 41). Midline fractures are not commonly found in adults.<sup>93</sup>

Mandibular fractures are often caused either by blows to the chin through interpersonal violence, accidents, during sports, or, in our time one of the most common causes is through road-traffic accidents.<sup>94</sup> Unilateral corpus fractures, which were most commonly found in this material (Figs. 38–

<sup>93</sup> Galloway & Wedel 2014, 154–156.

<sup>94</sup> Thapliyal *et al.* 2008.



Fig. 42. No. 1359, LPF, right temporal, left mandible.

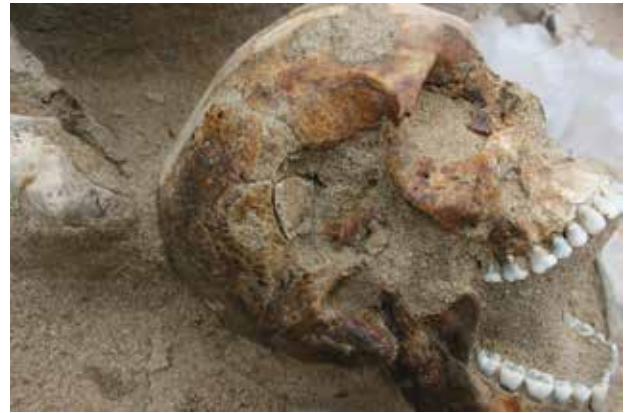

Fig. 43. No. 1373, LPF, right temporal, right sphenoid.

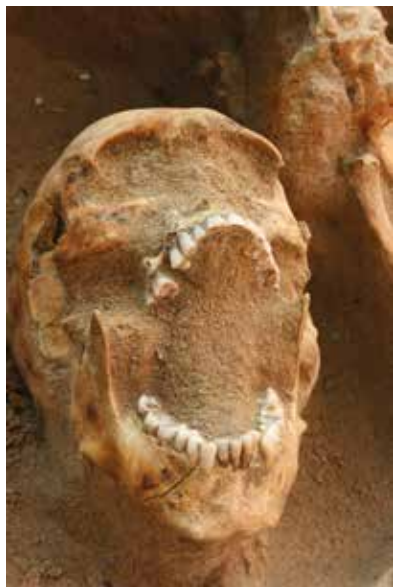

Fig. 44. No. 1374, LPF, right mandible.



Fig. 45. No. 1383, LPF, right temporal, right sphenoid, left frontal, right maxilla, and left mandible.



Fig. 46. No. 1390, LPF, right mandible.

39 and 44–47), are usually caused by lateral impact radiating from the point of impact.<sup>95</sup>

The LPF on the cranium were primarily found in the temporal/sphenoid/parietal area or on the frontal (Figs. 39–43, 45, 48 and 50–51). Nine individuals exhibited depressed comminuted fractures to this area: six individuals in Row 1 and three individuals in Row 3. None of the individuals in Row 2 exhibited LPF to the cranium. The fractures were located on the right side of the cranium in seven of nine individuals (78%).

Depressed cranial fractures resulting from BFT are often the result of interpersonal violence. Yet, fractures occurring during, for instance, transportation of dead bodies, or during deposition or burial of recently dead individuals, may produce similar skeletal fractures.<sup>96</sup>

Although the LPF encountered in this material could have resulted from interpersonal violence, other causes cannot be excluded. In 64% (nine individuals of 14) the LPF were located on the side of the cranium facing up. Thus, some of the fractures could have resulted from soil compression or from disturbances in connection with deposition when the skeletons were rela-

<sup>95</sup> Unnewher *et al.* 2003, 329; Arbour 2008, 167; Kimmerle & Baraybar 2008, 167.

<sup>96</sup> Byers 2008, 283; Dirkmaat *et al.* 2008; Kranioti 2015.

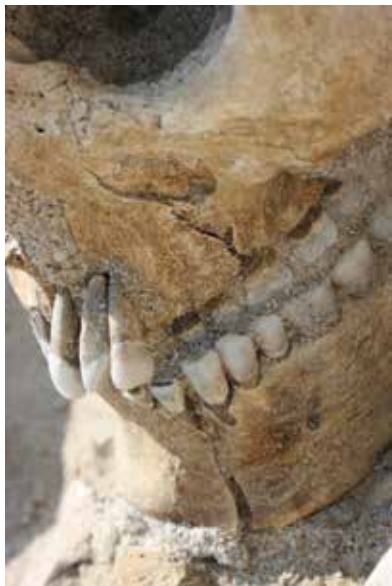

Fig. 47. No. 1269, LPF, left mandible.

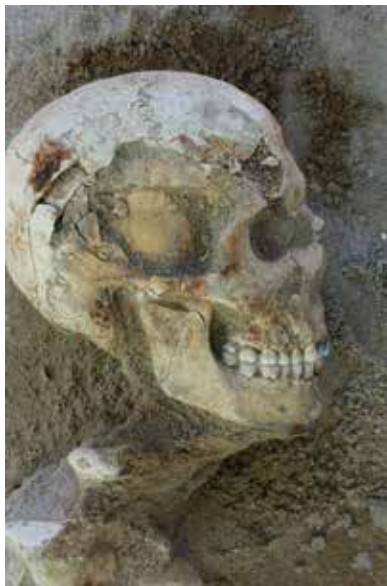

Fig. 48. No. 1386, LPF, right mandible.



Fig. 49. No. 1272, LPF, right parietal.



Fig. 50. No. 1316, LPF, left parietal, left temporal, left sphenoid.



Fig. 51. No. 1333, LPF, left frontal.

tively fresh or moist. However, Alan Richard Moritz noted that if the head was immobilized, i.e., resting on the ground a blow would result in a comminuted fracture with inward displacement on the cranium.<sup>97</sup> This type of fractures was noted in nine individuals (nos. 1359, 1336, 1373, 1353, 1383, 1356, 1272, 1316, and 1339—Row 3), which makes blows to the head on individuals lying down possible. Another likely scenario is that some of the individuals were executed at site when kneeling

(perhaps in front of a trench)—a blow from blunt object like a club, swung from lower to higher on the side of the head could have resulted in the fractures noticed.<sup>98</sup>

In three of 14 individuals (21%) LPF skull fractures (i.e. including mandible) were located on the side which was not facing up. Of course, these could only be noticed when the

<sup>97</sup> Moritz 1954.

<sup>98</sup> Ta'Ala *et al.* 2006, 996–1001. We thank Prof. Maria A. Liston for this suggestion and the reference.

skeletons were lying in a supine position or when the skull was inclined to the opposite side.

Interpersonal blunt force trauma to the skull from a right-handed opponent (in face-to-face combat) are often encountered on the left side of the skull while fractures resulting from falls are often linear and often found on the right side of the head.<sup>99</sup> In this material, seven of the nine individuals (78%) with LPF cranial fractures, and five of nine individuals (55%) with LPF mandibular fractures showed fractures to the right side. These figures cannot be regarded as an accurate prevalence since often only one side of the crania and mandibles were possible to observe in the field.

In forensic settings, the differentiation of head trauma resulting from assault or falls is crucial. An often-used criterion to aid these interpretations is the so-called rule of the “hat brim line” (HBL). The HBL is the area corresponding to the maximum circumference of the vault. Célia Kremer *et al.* defined the HBL according to anthropometric landmarks on the skull to make it applicable to a skull without soft tissue; inspired by the Frankfurt horizontal plane the superior margin passes through the glabella and the inferior margin passes through the centre of the external auditory meatus.<sup>100</sup> Fractures above the HBL line are often considered more likely to result from assaults whereas fractures occurring under or within this line more often result from falls from standing height, or down stairs.<sup>101</sup> In a study of head trauma either resulting from falls from one’s own height, downstairs, or homicide-related blows with a blunt weapon, Kremer *et al.* found that although fractures above the HBL were associated with blows, fractures within the HBL were less conclusive.<sup>102</sup> They also found that fractures from blows more commonly occurred on the left side, whereas fall-related fractures were often found on the right side.

Although fracture localization according to the HBL rule is often suggested as one criterion for differentiating between fractures resulting from a falls or other causes like violent assaults to the head, a number of forensic studies have questioned this division and found that other criteria (e.g. side of lateralization, calvaria fracture type, etc.) should be used in connection to the HBL rule, since it is not by itself diagnostic for differentiating between falls versus homicide-related fractures.<sup>103</sup> The HBL may be applicable for differentiating falls from face-to-face combat. However, if an individual (in this case likely shackled or otherwise constrained) was kneeling and executed by a blow to the head with a blunt object by an assailant standing behind the victim, or, if a blow to the skull

Table 25. Distribution of likely and possible perimortem trauma (LPF and PPF) (n = no. of individuals).

	LPF (n)	%	PPF (n)	%
Row 1	9	17.7	16	34
Row 2	2	12.5	7	44
Row 3	3	18.7	2	12
<b>Total</b>	<b>14</b>	<b>17.7</b>	<b>25</b>	<b>31.6</b>

with a blunt object to a victim lying down, fractures may be found on the side of the head and most likely within the HBL.

Since the majority of the LPFs observed in this material was located within, or slightly above the HBL, frequently on the right side, it is likely that a number of them could have resulted from falls to the ground. However, most of the comminuted BFT trauma with inward displacement likely resulted from assaults to the head when the individuals were lying down or kneeling.

#### Possible perimortem fractures (PPF)

A total of 25 individuals (32%) show evidence of PPF (Table 25); 16 of 47 (34%) in Row 1, seven of 16 in Row 2 (44%) and two of 16 (12%) in Row 3 (Figs. 52–80).

Most PPF were observed on the skull, especially in the temporal area and/or to the lower jaw (Figs. 52–54, 56–58, 60–68, 71–77 and 79–80). In Row 1, five individuals exhibited cranium fractures as well as fractures to the mandible, two individuals in Row 2 exhibited both cranium and mandible fractures, while there were none in Row 3. All fractures seem to have resulted from BFT.

In 44% of the 16 individuals exhibiting mandible fractures, and in 50% of the 14 individuals with cranium fractures, the trauma was situated on the side that was not facing up in the ground. It is thus possible that some of the fractures noted could have been encountered before deposition of the bodies.

Five individuals, four in Row 1 and one in Row 2 show evidence of possible postcranial BFT trauma: four individuals (nos. 1348, 1353, 1383, and 1388, Figs. 55, 59, 69, and 78) show possible trauma to the femur, and one individual (no. 1390, Fig. 70) exhibited transverse mid-shaft fractures to the right second and third metacarpals. Three of four femur fractures were intertrochanteric fractures; one oblique fracture was found to the lower diaphysis.

## Summary and conclusion

The osteological field documentation of 79 individuals deposited in three rows at the Phaleron cemetery in a salty marshland, i.e. in a beach context, shows that they were all primary depositions. However, the lengthy interval between excava-

<sup>99</sup> Aufderheide & Rodríguez-Martin 1998, 23; Kranioti 2015.

<sup>100</sup> Kremer *et al.* 2008.

<sup>101</sup> Burk 2012, 197; Kranioti 2015; Spitz 1993, 236.

<sup>102</sup> Kremer *et al.* 2008.

<sup>103</sup> Kremer *et al.* 2008; Guyomarc’h *et al.* 2010.



Fig. 52. No. 1324, PPF, left mandible, left temporal.



Fig. 53. No. 1328, PPF, right parietal, right temporal, right sphenoid, right mandible.



Fig. 54. No. 1348, PPF, left mandible.



Fig. 55. No. 1348, PPF, left femur.

tion and the osteological field documentation, as well as the limited opportunity to observe all skeletal elements, makes interpretations of the skeletons and their context tentative.

A majority of the individuals were young adult or juvenile males, most of them without signs of active disease and with a generally good oral health status.

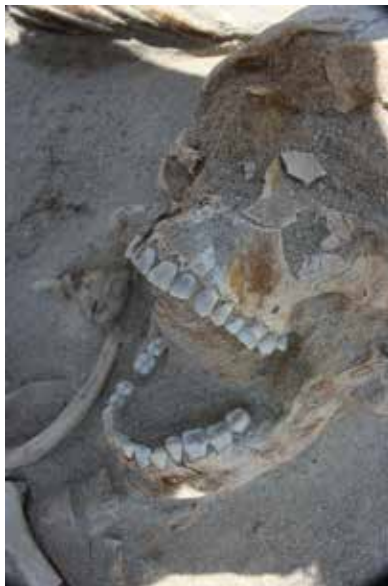The articulated skeletons indicate that the bodies were deposited in a shallow trench or on the ground and covered with soil a short time after deposition. However, parts of the bodies were probably poorly or only partially covered as evidenced by a number of displaced but articulated skeletal parts located close to or in between the skeletons, occasionally missing skeletal parts, and in one case evidence of animal scavenging.

The orientation and position of the skeletons in the three rows varies and suggest that they were deposited at different occasions. An interval between the depositions in the three rows could not be established. However, the approximate similar stratigraphical level, arrangement of the skeletons, as well as the short distance between the rows seem to suggest that the depositions were made within a short period of time.

*Postmortem* disturbances were noted particularly in the southern and northern part of Row 1, where fragmentation, dispersal, and removal of major parts of some skeletons were observed. The likely cause is that later depositions of two individuals (nos. 1336 and 1355) disturbed the depositions of individuals nos. 1318, 1392, and 1393. In the northern part of



*Fig. 56. No. 1349, PPF, right temporal.*



*Fig. 57. No. 1349, PPF, left mandible.*



*Fig. 58. No. 1353, PPF, right mandible.*



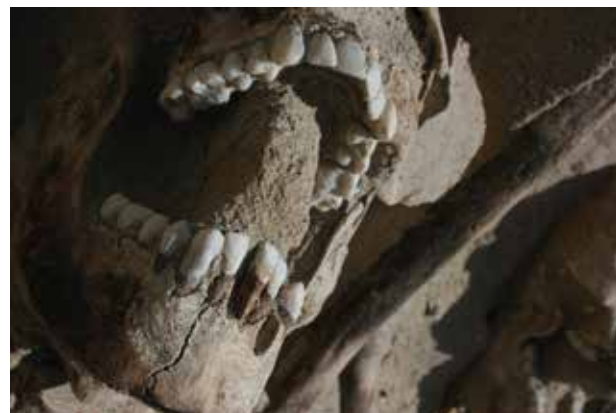*Fig. 59. No. 1353, PPF, left femur.*



*Fig. 60. No. 1361, PPF, right temporal.*



*Fig. 61. No. 1363, PPF, right temporal.*



*Fig. 62. No. 1365, PPF, right mandible.*



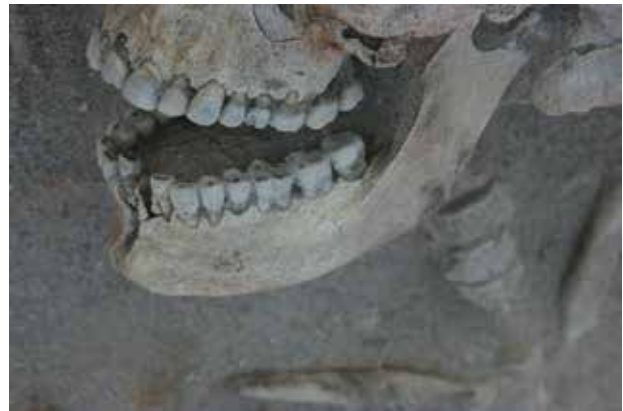*Fig. 63. No. 1364, PPF, right temporal, right mandible.*



*Fig. 64. No. 1366, PPF, right sphenoid.*



*Fig. 65. No. 1374, PPF, right temporal, left mandible.*



*Fig. 66. No. 1375, PPF, left mandible.*



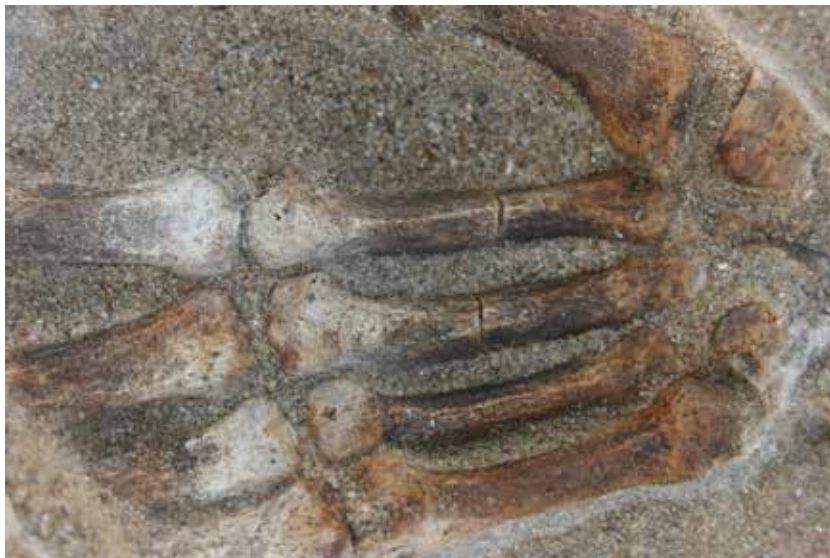*Fig. 67. No. 1380, PPF, right temporal.*



*Fig. 68. No. 1381, PPF, right temporal.*



*Fig. 69. No. 1383, PPF, right femur.*



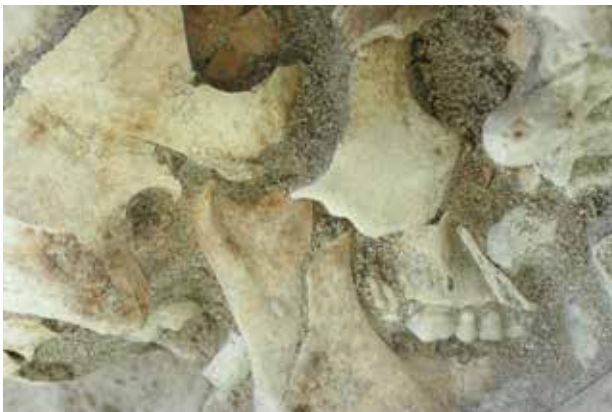*Fig. 70. No. 1390, PPF, right second metacarpal and right third metacarpal.*



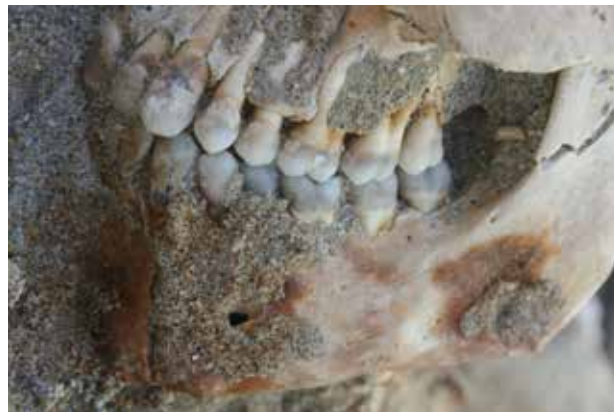*Fig. 71. No. 1267, PPF, left temporal.*



*Fig. 72. No. 1267, PPF, right mandible.*



*Fig. 73. No. 1389, PPF, right temporal, right mandible.*



*Fig. 74. No. 1369, PPF, left mandible.*

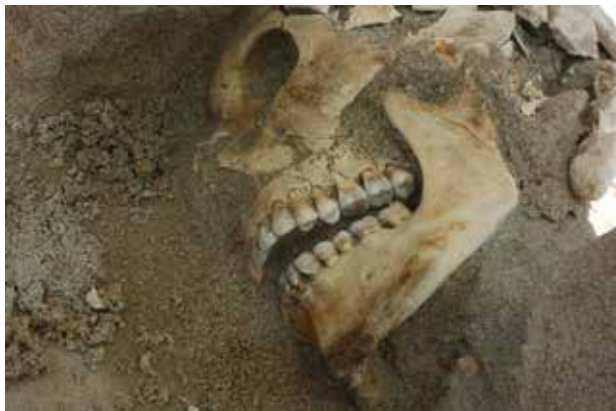

Fig. 75. No. 1357, PPF, left mandible.

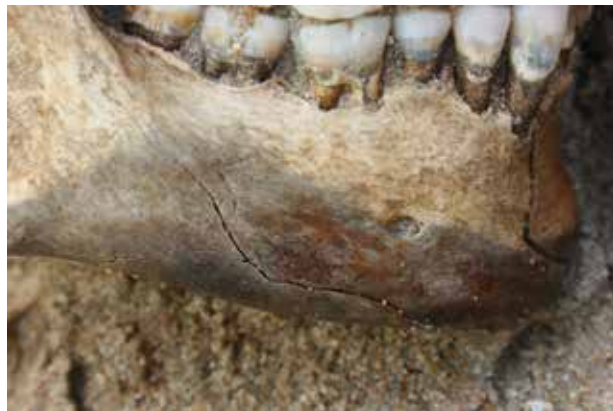

Fig. 76. No. 1387, PPF, right mandible.

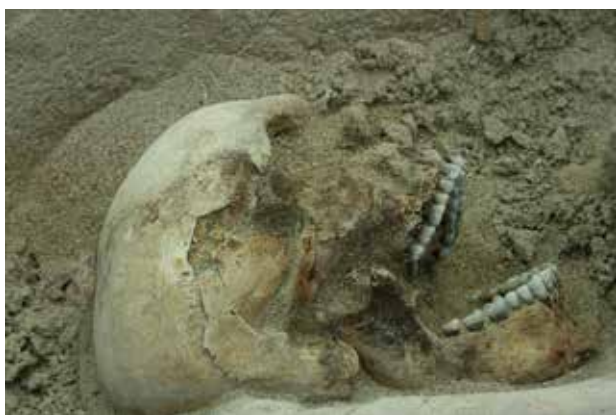

Fig. 77. No. 1388, PPF, right temporal, right mandible.



Fig. 78. No. 1388, PPF, left femur.

the row, later construction works for a hippodrome may have disturbed the (earlier?) depositions of nos. 1245 and 1247.

The positions of a majority of individuals in Row 1 seem more or less arranged in this row, i.e. most individuals were located side by side in supine position, often with limbs intertwined, heads oriented to the east, and arms positioned over their heads with wrists shackled.

In the southern part of Row 1, seven individuals (nos. 1354, 1353, 1356, 1339, 1340, 1336, as well as no. 1355) seem to have been deposited later than the majority of the individuals in this row. These individuals are positioned north-south, with skulls largely oriented to the south and with limb bones sometimes overlapping the southernmost individuals in the more orderly laid-out individuals in this part of the row. Since the individuals were already uncovered at the time of documentation and no information about colour changes in the soil or additional observations was available at the time, it could not be determined whether these seven individuals are associated with the same event/context as the rest of the individuals in this row, nor the timespan between the depositions.

In contrast to Row 1, the individuals in Row 2 seem somewhat haphazardly deposited; the orientation and position of these individuals are largely variable. Eight individuals in the northern part of Row 2 are oriented approximately north-south, with heads to the south, their skeletons overlapping each other. South of no. 1371 there is an empty space of c. 0.4-0.5 m, and the following eight individuals in this row were found in different positions and orientation, overlapping each other. The level of all skeletons is similar, but the different orientation of the two groups in this row seems to suggest that they were deposited on different occasions but probably close in time.

In Row 3, the northernmost three individuals, nos. 1285, 1277, and 1276, are located close to each other in similar positions, i.e. on their left side with lower limbs bent at the knees. The positions of these individuals seem to indicate they collapsed/fell on the spot, almost like dominoes, as if they had been lined up and executed. The individuals deposited in the middle to southern part of the row, however, are positioned in a disorderly manner, partly on top of each other with limbs more or less intertwined but in similar orientation, approximately east-west.



Fig. 79. No. 1271, PPF, right temporal, right zygomatic, right parietal, right frontal.

The three individuals, nos. 1275, 1271, and 1272, lay in similar positions as the northernmost individuals, although their skulls were in supine position or slightly inclined to the left side. Nos. 1294 and 1316 were oriented likewise, although no. 1294 was in prone position partly covering no. 1316. All these individuals were oriented east–west, with skulls towards south-west. The three individuals in the southernmost part were found more or less next to each other in different positions, occasionally with limbs positioned on top of the neighbouring individual, with heads oriented to the south.

Although the circumstances surrounding the depositions of the 79 individuals cannot be clarified at this stage, the short distance between the rows, the stratigraphy and position of the skeletons, and the location of their more or less intertwined limbs, as well as the largely articulated state of the skeletons makes it likely that they were deposited within a short time span, although perhaps as a result of separate events. It is possible that some individuals could have been transported to the site from elsewhere (almost or already dead?) and that some bodies in Row 1 were arranged before they were covered.

Cause of death could not be determined even in cases when extensive and likely *perimortem* fractures were observed, since fractures produced during contact with the ground or during deposition/covering of the bodies may result in skeletal fractures that mimic but are not related to injuries inflicted at, or shortly before death. The only object related to injury and/or possible cause of death was an arrowhead found in the chest of no. 1272, in Row 3.

Many of the suspected *perimortem* skull fractures were located on the side of the skull facing up, i.e., when the skull was inclined on one side, or when the individual was placed in a lateral position. These may be the result of blunt force trauma, but taphonomic factors resulting in *postmortem* breaks mimicking *perimortem* fractures cannot be excluded. However, the



Fig. 80. No. 1333, PPF, right mandible.

soil covering the skeletons consisted of sand without inclusions of stones or other heavy objects.

*Perimortem* fractures in other parts of the skeleton than noted here cannot be excluded since postcranial fracture patterning, especially on thin and delicate bones such as the rib cage or hand/foot bones, were difficult to evaluate as the bones were often partially covered in soil, or poorly preserved through prolonged exposure.

The scenario surrounding the depositions of the individuals in the mass graves at Phaleron is largely obscure and cannot be elucidated through the osteological field observation. However, it seems likely that the individuals died within a short period of time, some of them more or less simultaneously. Why and where the individuals were killed is a matter of conjecture; the observations from the field documentation neither validate, nor disprove the hypothesis that these individuals were the captives and victims of the so-called “Cylonian conspiracy”.

A hypothetical scenario is that a majority of the captives, probably in poor physical condition, e.g. starved, dehydrated, and beaten but otherwise in good general health, were brought to Phaleron in shackles, some of them plausibly tied to a frame with ropes, as suggested by their positions. The individuals may have been pushed to the ground, some of them perhaps kneeling, before fatal blows/punches to the head of the individuals not already dead were inflicted before the bodies were covered.

ANNE INGVARSSON

Gustavianum, Uppsala University Museum  
Akademigatan 3  
753 10 Uppsala, Sweden  
anne.ingvarsson@gustavianum.uu.se

Swedish Institute at Athens  
Mitseon 9  
117 42 Athens, Greece

YLVA BÄCKSTRÖM

Department of Archaeology and Ancient History  
Lund University  
Box 192  
221 00 Lund, Sweden  
ylva.backstrom@ark.lu.se

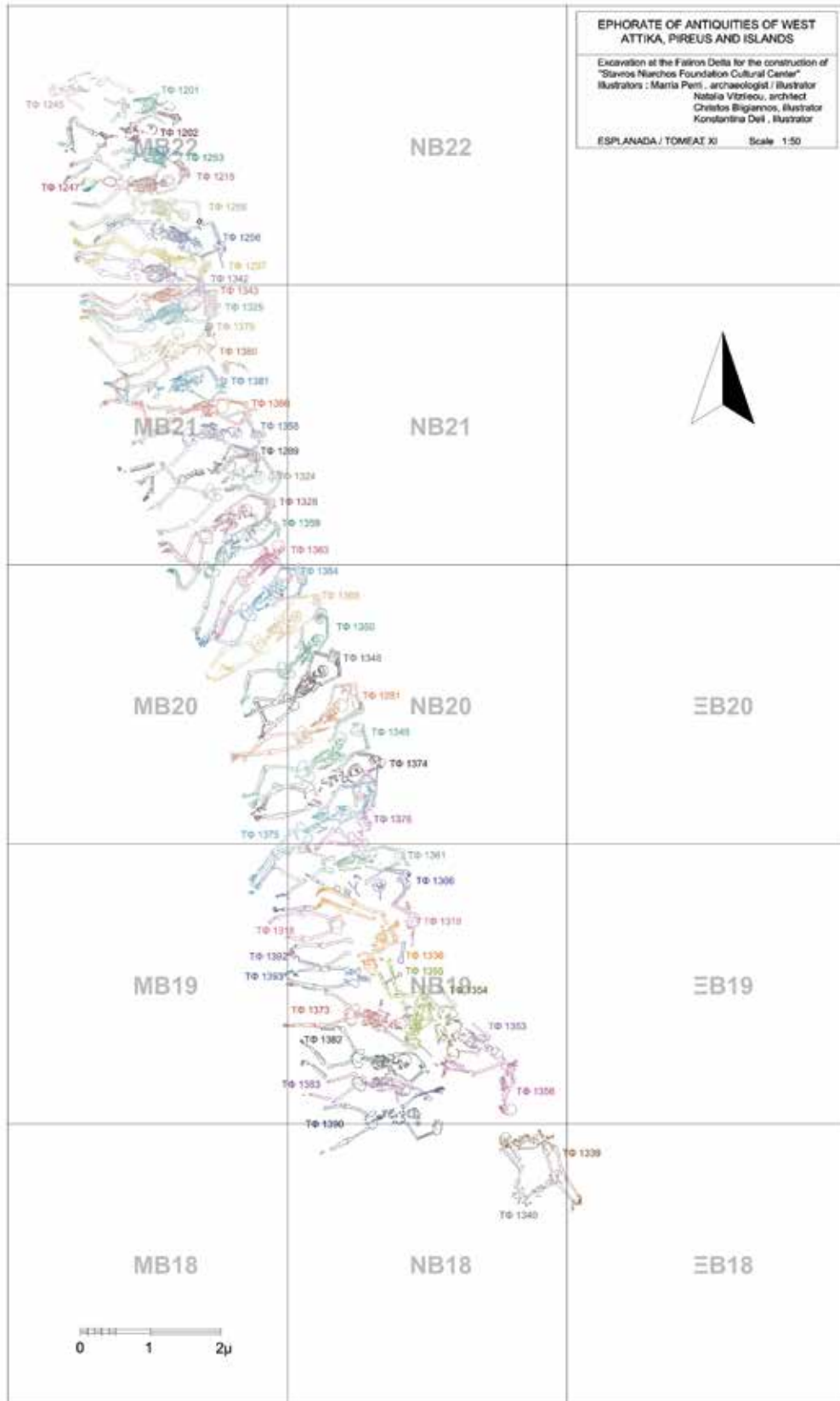


Fig. 81. Skeletons, Row 1.

## Appendix I Skeletal catalogue

### DESCRIPTION

For information regarding the data recorded in this appendix, see above, under the heading “Methods”.

### ABBREVIATIONS

- A = absent
- AMTL = *antemortem* tooth loss
- Cribra = cribra orbitalia
- Dx = right
- LEH = linear enamel hypoplasia
- OA = Osteoarthritis
- PH = porotic hyperostosis
- Sin = left
- U = unobservable
- X = present

### Skeletons—Row I (Fig. 81)

#### SKELETON NO. 1201—ROW I (FIG. 82)

##### *Taphonomy/Preservation*

The skeleton is placed in a supine position in an E–W direction (cranium to the E). The skeleton consists mainly of the torso and a smashed cranium (mandible is missing). Both femurs are presented by bone stumps; only the proximal parts are present. Approximately half of the skeleton is preserved, but the quality of the bones is bad and more than 2/3 of the skeleton is fragmented and affected by erosion.

Quantitative preservation: 2

Qualitative preservation: 1

##### *Position*

Skeleton: Supine

Cranium: Supine

Limbs: Left upper limb—A, Left hand—A, Left lower limb—slightly flexed; Right upper limb—A, Right hand—A, Right lower limb—flexed

##### *Relation to other skeletons*

Right foot below the knee of skeleton no. 1202; left foot below the tibia and fibula of skeleton no. 1202

##### *Finds*

Shackles: No/not observable

*Estimate of sex: Undetermined*

Criteria: Skull, and measurement

##### *Skull*

Skull—trait	Left	L/R	Right
Angle of the frontal		U	
Frontal/parietal eminences		U	
Nuchal crest		U	
Mastoid process	4		U
Zygomatic bone	U		U
Orbital outline	U		U
Supraorbital margin	U		U
Glabella		U	
Gonial angle flare	U		U
Mental eminence		U	

##### *Measurement*

47 cm (femur dx, maximum head)

*Estimate of age at death: Adult*

Criteria: epiphyses, and suture closure

##### *Epiphyses*

Skull (cranium + mandible)	U
Thorax (sternum + ribs)	A
Vertebral column	U
Shoulder girdle (clavicle + scapula)	U
Upper limbs	>14
Pelvis (coxae + sacrum + coccygis)	>25
Lower limbs	>14

##### *Suture closure (ectocranial)*

Coronal	Minimal—significant
Sagittal	U
Lambdoid	U

##### *Pathology/Trauma*

*Antemortem* trauma: U

Likely *perimortem* trauma: U

Possible *perimortem* trauma: U

#### SKELETON NO. 1202—ROW I (FIG. 83)

##### *Taphonomy/Preservation*

The skeleton is placed in a supine position in an E–W direction (cranium to the E). Visceral cranium smashed, mandible missing. Most parts of the

left side of the body are missing; torso (ribs and vertebrae) fragmented, and badly preserved. Bone stumps of both femurs (proximal parts) present. Right arm stretched above the head; hands in shackle. Approximately half of the skeleton is preserved, but the quality of the bones is bad and more than 2/3 of the skeleton is fragmented and affected by erosion.

Quantitative preservation: 2

Qualitative preservation: 1

##### *Position*

Skeleton: Supine—inclined to the left

Cranium: Supine—slightly to the left

Limbs: Left upper limb—A, Left hand—A, Left lower limb—flexed, Right upper limb—extended, Right hand—A, Right lower limb—flexed

##### *Relation to other skeletons*

Right femur below the right hand of skeleton no. 1245; knee joint on top of the right foot of skeleton no. 1201; right tibia below the left foot of skeleton no. 1201; right arm (with shackle) below the left scapula of skeleton no. 1201

##### *Finds*

Shackles: Yes—right wrist

*Estimate of sex: Undetermined*

Criteria: Skull, and pelvis

##### *Skull*

Skull—trait	Left	L/R	Right
Angle of the frontal		A	
Frontal/parietal eminences		A	
Nuchal crest		U	
Mastoid process	U		U
Zygomatic bone	A		A
Orbital outline	A		A
Supraorbital margin	A		A
Glabella		A	
Gonial angle flare	A		A
Mental eminence		A	



Fig. 82. Skeleton no. 1201.



Fig. 83. Skeleton no. 1202.

*Pelvis*

Pelvis—trait	Left	Right
Subpubic concavity	A	A
Ventral arc	A	A
Ischiopubic ramus	A	A
Subpubic angle	A	A
Greater sciatic notch	5	U
Preauricularis sulcus	U	U

*Estimate of age at death: Adult*

Criteria: Epiphyses, and suture closure

*Epiphyses*

Skull (cranium + mandible)	U
Thorax (sternum + ribs)	A
Vertebral column	U/A
Shoulder girdle (clavicle + scapula)	U/A
Upper limbs	>14
Pelvis (coxae + sacrum + coccygis)	U/A
Lower limbs	>16

*Suture closure (ectocranial)*

Coronal	Significant
Sagittal	U
Lambdoid	U

*Pathology/Trauma*

*Antemortem* trauma: U

Likely *perimortem* trauma: U

Possible *perimortem* trauma: U

*Nonmetric skeletal traits*

Metopic suture

**SKELTON NO. 1215—ROW I (FIG. 84)**

*Taphonomy/Preservation*

The skeleton is placed in a prone position in an E–W direction (cranium to the E), with hands in a shackle above the head. A skull (individual no. 1247), belonging to another individual, was

found between the legs. The skeleton is almost complete; only parts of the the feet are missing, but more than 2/3 of the skeleton is badly preserved, eroded, and fragmented.

Quantitative preservation: 3

Qualitative preservation: 1

*Position*

Skeleton: Prone

Cranium: Prone

Limbs: Left upper limb—flexed, Left hand—extended, Left lower limb—flexed, Right upper limb—flexed, Right hand—extended (on top of left hand), Right lower limb—flexed

*Relation to other skeletons*

Skull of individual no. 1247 between the legs (left and right femur)

*Finds*

Shackles: Yes—wrists



Fig. 84. Skeleton no. 1215.



Fig. 85. Skeleton no. 1245.

*Estimate of sex: Male?*

Criteria: Skull

Skull

Skull—trait	Left	L/R	Right
Angle of the frontal		U	
Frontal/parietal eminences		No	
Nuchal crest		U	
Mastoid process	5		5
Zygomatic bone	U		U
Orbital outline	U		U
Supraorbital margin	U		U
Glabella		U	
Gonial angle flare	2		2
Mental eminence		U	

*Estimate of age at death: Adult*

Criteria: Epiphyses, and suture closure

*Epiphyses*

Skull (cranium + mandible)	U
Thorax (sternum + ribs)	U
Vertebral column	U
Shoulder girdle (clavicle + scapula)	U
Upper limbs	>17
Pelvis (coxae + sacrum + coccygis)	>20
Lower limbs	U

*Suture closure (ectocranial)*

Coronal	U
Sagittal	Almost obliterated
Lambdoid	U

*Pathology/Trauma*

*Antemortem* trauma: U

Likely *perimortem* trauma: U

Possible *perimortem* trauma: U?

**SKELETON NO. 1245—ROW I (FIG. 85)**

*Taphonomy/Preservation*

The skeleton is placed in a supine position in W–E direction (cranium to the W). The preserved skeleton consists mainly of the torso (fragmented and the major part of the spinal column missing), and a smashed cranium; most parts of the left side of the body are missing, as well as the lower parts of the arms and legs on the right side. Approximately half of the skeleton is preserved, but the quality of the bones is bad, and more than 2/3 of the skeleton is fragmented and affected by erosion.

Quantitative preservation: 2

Qualitative preservation: 1



Fig. 86. Individual no. 1247.

#### Position

Skeleton: Supine—with emphasis on the right side

Cranium: Lateral—to the right

Limbs: Left upper limb—U, Left hand—on top of left rib cage (disorganized bones), Left lower limb—A, Right upper limb—flexed, Right hand—palm upwards (connected bones), Right lower limb—flexed

#### Relation to other skeletons

Right hand on right proximal femur of skeleton no. 1202

#### Finds

Pottery below humerus and femur

Shackles: No

Estimate of sex: Undetermined

Criteria: Skull, pelvis, and measurement

#### Skull

Skull—trait	Left	L/R	Right
Angle of the frontal		Ambiguous	
Frontal/parietal eminences		Slight	
Nuchal crest		U	
Mastoid process	A		U
Zygomatic bone	3		U
Orbital outline	A		U
Supraorbital margin	A		U
Glabella		3	
Gonial angle flare	A		U
Mental eminence		A	

#### Pelvis

Pelvis—trait	Left	Right
Subpubic concavity	A	A
Ventral arc	A	A
Ischiopubic ramus	A	A
Subpubic angle	A	A
Greater sciatic notch	A	4
Preauricularis sulcus	U	U

#### Measurement

45 cm (femur dx, maximum head)

Estimate of age at death: Middle adult

Criteria: Epiphyses, suture closure, tooth eruption, and tooth wear

#### Epiphyses

Skull (cranium + mandible)	U
Thorax (sternum + ribs)	U/A
Vertebral column	U
Shoulder girdle (clavicle + scapula)	U/A
Upper limbs	>14
Pelvis (coxae + sacrum + coccygis)	U/A
Lower limbs	>12

#### Suture closure (ectocranial)

Coronal	Significant
Sagittal	Obliteration
Lambdoid	Significant

#### Tooth eruption, M3

Maxilla	Mandible
Sin—erupted Dx—U	Dx—erupted Sin—U

#### Tooth wear

Maxilla	Mandible
U	35–45

#### Pathology/Trauma

Dental pathology: Enamel fracture on right mandible P1 (labial)

Antemortem trauma: U

Likely *perimortem* trauma: U

Possible *perimortem* trauma: U

#### INDIVIDUAL NO. 1247—ROW I (FIG. 86)

#### Taphonomy/Preservation

Poorly preserved skeleton; only smashed skull present.

Quantitative preservation: 1

Qualitative preservation: 1

#### Position

Cranium: Prone

#### Relation to other skeletons

The skull was found between the legs of skeleton no. 1215

#### Finds

Shackles: No (only cranium present)

Estimate of sex: Undetermined

Criteria: Skull

#### Skull

Skull—trait	Left	L/R	Right
Angle of the frontal		U	
Frontal/parietal eminences		U	
Nuchal crest		U	
Mastoid process	U		U
Zygomatic bone	U		U
Orbital outline	U		U
Supraorbital margin	U		U
Glabella		U	
Gonial angle flare	U		U
Mental eminence		U	

Estimate of age at death: Adult?

#### Pathology/Trauma

Antemortem trauma: U

Likely *perimortem* trauma: U

Possible *perimortem* trauma: U

#### SKELETON NO. 1253—ROW I (FIG. 87)

#### Taphonomy/Preservation

The skeleton is placed in a supine position in an E–W direction (cranium to the E), with arms probably placed above the head. Only the proximal parts of left and right femora are preserved. Left upper limb is missing, ulna and radius and most of humerus from the right side is missing. Left and right hand are missing. Visceral cranium is fragmented, mandible missing. Approximately half of the skeleton is preserved. The quality of the bones is intermediate, and around 1/3–2/3 of the bones have a pronounced degree of erosion of surfaces and fragmentation.

Quantitative preservation: 2

Qualitative preservation: 2

#### Position

Skeleton: Supine

Cranium: Supine

Limbs: Left upper limb—A, Left hand—A, Left lower limb—extended, Right



Fig. 87. Skeleton no. 1253.



Fig. 88. Skeleton no. 1266.

upper limb—probably straight up, Right hand—A, Right lower limb—extended  
*Relation to other skeletons*

The left leg of skeleton no. 1215 is found below this skeleton

*Finds*

Shackles: No, but iron found below the right femur (could belong to a lower-lying burial?)

*Estimate of sex: Undetermined*

Criteria: Pelvis

*Pelvis*

Pelvis—trait	Left	Right
Subpubic concavity	A	A
Ventral arc	A	A
Ischiopubic ramus	A	A
Subpubic angle	A	A
Greater sciatic notch	U	5
Preauricularis sulcus	U	U

*Estimate of age at death: Adult*

Criteria: Epiphyses

*Epiphyses*

Skull (cranium + mandible)	U
Thorax (sternum + ribs)	U/A
Vertebral column	U
Shoulder girdle (clavicle + scapula)	U/A
Upper limbs	>17
Pelvis (coxae + sacrum + coccygis)	>25
Lower limbs	>16

*Pathology/Trauma*

*Antemortem* trauma: U

Likely *perimortem* trauma: U

Possible *perimortem* trauma: U

**SKELETON NO. 1266—ROW I (FIGS. 16 & 88)**

*Taphonomy/Preservation*

The skeleton is placed in a supine position in an E–W direction (cranium to the E), with hands in a shackle above the head. Left foot is disjunct and displaced. The skeleton is almost complete; more than 2/3 of the skeletal parts are present, and they are well preserved.

Quantitative preservation: 3

Qualitative preservation: 3

*Position*

Skeleton: Supine

Cranium: Supine

Limbs: Left upper limb—flexed (above the head), Left hand—U, Left lower limb—extended, Right upper limb—flexed, Right hand—U, Right lower limb—flexed

*Relation to other skeletons*

Right lower limb (femur, tibia, fibula, and foot) below the pelvic arc of skeleton no. 1215

*Finds*

*Oinochoe* between the legs

Shackles: Yes—wrists

*Estimate of sex: Male?*

Criteria: Skull and measurement

*Skull*

Skull—trait	Left	L/R	Right
Angle of the frontal		Sloped	
Frontal/parietal eminences		No	
Nuchal crest		U	
Mastoid process	U		5
Zygomatic bone	?		?
Orbital outline	3		U
Supraorbital margin	3		3
Glabella		5	
Gonial angle flare	U		3
Mental eminence		A	

*Measurement*

48.1 cm (femur sin, maximum head)

*Estimate of age at death: Young adult*

Criteria: Epiphyses, tooth eruption, and tooth wear

*Epiphyses*

Skull (cranium + mandible)	U
Thorax (sternum + ribs)	U
Vertebral column	U
Shoulder girdle (clavicle + scapula)	24–29
Upper limbs	>20
Pelvis (coxae + sacrum + coccygis)	>23
Lower limbs	>20

*Tooth eruption, M3*

Maxilla	Mandible
Sin—U	Sin—U
Dx—erupted	Dx—U?

*Tooth wear*

Maxilla	Mandible
17–25	17–25

*Stature: 163.75 cm (femur sin)*

*Pathology/Trauma*

Osteoarthritis: Porosity and osteophytes on clavicle (sin?)

*Antemortem* trauma: U

Likely *perimortem* trauma: U

Possible *perimortem* trauma: U

## SKELETON NO. 1281—ROW 1

(FIG. 89)

*Taphonomy/Preservation*

The skeleton is placed in a supine position in a NE–SW direction (cranium to the NE), with hands in a shackle above the head. Legs are crossed; left over right. The skeleton is almost complete; more than 2/3 of the skeletal parts are present, and they are well preserved.

Quantitative preservation: 3

Qualitative preservation: 3

*Position*

Skeleton: Supine

Cranium: Supine—inclined to the right side

Limbs: Left upper limb—flexed, Left hand—flexed, Left lower limb—extended, Right upper limb—flexed, Right hand—more extended, Right lower limb—slightly flexed

*Relation to other skeletons*

Left arm below the arm of skeleton no. 1349

*Finds*

Shackles: Yes—wrists

*Estimate of sex: Male*

Criteria: Skull, pelvis, and measurement

*Skull*

Skull—trait	Left	L/R	Right
Angle of the frontal		Sloped	
Frontal/parietal eminences		No	
Nuchal crest		2	
Mastoid process	4		U
Zygomatic bone	3		U
Orbital outline	U		U
Supraorbital margin	2		2
Glabella		2	
Gonial angle flare	2		U
Mental eminence		U	

*Pelvis*

Pelvis—trait	Left	Right
Subpubic concavity	U	3
Ventral arc	U	3
Ischiopubic ramus	U	3
Subpubic angle	U	U
Greater sciatic notch	5	4
Preauricularis sulcus	U	U

*Measurement*

44.1 cm (femur dx, maximum head)

*Estimate of age at death: Young adult*

Criteria: Epiphyses, suture closure, pubic symphysis, tooth eruption, and tooth wear

*Epiphyses*

Skull (cranium + mandible)	U
Thorax (sternum + ribs)	U
Vertebral column	U
Shoulder girdle (clavicle + scapula)	Fusing flake? >16–21
Upper limbs	>20
Pelvis (coxae + sacrum + coccygis)	<27
Lower limbs	>20

*Suture closure (ectocranial)*

Coronal	U
Sagittal	U
Lambdoid	Open—minimal

*Pubic symphysis*

Left	Right
U	I:1, c. 18.5

*Tooth eruption, M3*

Maxilla	Mandible
Sin—not erupted	Sin—not erupted
Dx—U	Dx—U

*Tooth wear*

Maxilla	Mandible
U	17–25

*Stature: 170.89 cm (femur dx)*

*Pathology/Trauma*

*Antemortem* trauma: U

Likely *perimortem* trauma: U

Possible *perimortem* trauma: U



Fig. 89. Skeleton no. 1281.



Fig. 90. Skeleton no. 1289.

**SKELETON NO. 1289—ROW I (FIG. 90)**

*Taphonomy/Preservation*

The skeleton is placed on its right side in a NNE–SSW direction (cranium to the NNE), with hands in a shackle above the head. Left femur is found at a much higher level than the rest of the skeleton. It is almost complete; more than 2/3 of the skeletal parts are present. The quality of the bones is intermediate, and around 1/3–2/3 of the bones have a pronounced degree of erosion of surfaces and fragmentation.

Quantitative preservation: 3

Qualitative preservation: 2

*Position*

Skeleton: Lateral—on the right side

Cranium: Lateral—on the right side

Limbs: Left upper limb—almost extended, Left hand—U, Left lower limb—flexed, Right upper limb—flexed, Right hand—U, Right lower limb—flexed

*Relation to other skeletons*

Right arm below the left humerus of skeleton no. 1358; left arm above the left arm of skeleton no. 1358; left femur above the left knee of skeleton no. 1358; right femur below the tibia of skeleton no. 1358

*Finds*

Shackles: Yes—wrists

*Estimate of sex: Male*

Criteria: Skull, and pelvis

*Skull*

Skull—trait	Left	L/R	Right
Angle of the frontal		sloped	
Frontal/parietal eminences		No	
Nuchal crest		5	
Mastoid process	4		U
Zygomatic bone	U		U
Orbital outline	U		U
Supraorbital margin	U		4
Glabella		U	
Gonial angle flare	U		U
Mental eminence		U	

*Pelvis*

Pelvis—trait	Left	Right
Subpubic concavity	U	U
Ventral arc	U	U
Ischiopubic ramus	U	U
Subpubic angle	U	U
Greater sciatic notch	5	U
Preauricularis sulcus	U	U

*Estimate of age at death: Adult*

Criteria: Epiphyses, and suture closure

*Epiphyses*

Skull (cranium + mandible)	U
Thorax (sternum + ribs)	U
Vertebral column	U
Shoulder girdle (clavicle + scapula)	>18
Upper limbs	>17
Pelvis (coxae + sacrum + coccygis)	U
Lower limbs	>19

*Suture closure (ectocranial)*

Coronal	Minimal
Sagittal	Minimal
Lambdoid	Minimal

*Stature: 158.99 cm (femur sin)**Pathology/Trauma*

Cribra/PH: Possibly Porotic hyperostosis on occipital

*Antemortem* trauma: ULikely *perimortem* trauma: UPossible *perimortem* trauma: U*Nonmetric skeletal traits*

Inca bone

**SKELETON NO. 1296—ROW 1  
(FIGS. 24, 38, & 91)***Taphonomy/Preservation*

The skeleton is placed in a supine position in an E–W direction (cranium to the E), with wrists in shackles, above the head. The skull is inclined on the right side. Left leg is crossed over the right leg. Left foot is displaced between the two tibiae. The skeleton is almost complete; more than 2/3 of the skeletal parts are present. Around 1/3–2/3 of the bones have a pronounced degree of erosion on the surfaces and are fragmented.

Quantitative preservation: 3

Qualitative preservation: 2

*Position*

Skeleton: Supine

Cranium: Supine—resting on the right side

Limbs: Left upper limb—flexed, Left hand—U, Left lower limb—flexed, Right upper limb—flexed, Right hand—U, Right lower limb—extended

*Relation to other skeletons*

Right humerus below the left arm of skeleton no. 1266

*Finds*

Shackles: Yes—wrists

*Estimate of sex: Undetermined*

Criteria: Skull, and measurement

*Skull*

Skull—trait	Left	L/R	Right
Angle of the frontal		Sloped	
Frontal/parietal eminences		No	
Nuchal crest		U	
Mastoid process	2		U
Zygomatic bone	3		U
Orbital outline	3		U
Supraorbital margin	2		U
Glabella		2	
Gonial angle flare	2		U
Mental eminence		3	

*Measurement*

43 cm (femur sin, maximum head)

*Estimate of age at death: Young adult*

Criteria: Epiphyses, suture closure, and tooth wear

*Epiphyses*

Skull (cranium + mandible)	U
Thorax (sternum + ribs)	U
Vertebral column	>19
Shoulder girdle (clavicle + scapula)	U
Upper limbs	>17
Pelvis (coxae + sacrum + coccygis)	<27
Lower limbs	>17

*Suture closure (ectocranial)*

Coronal	Open
Sagittal	U
Lambdoid	U

*Tooth wear*

Maxilla	Mandible
17–25	17–25

*Pathology/Trauma*

Dental pathology: Linear enamel hypoplasia right C mandible, slight calculus right P2 mandible, and antemortem (?) fracture left I2 and C, mandible.

*Antemortem* trauma: ULikely *perimortem* trauma: YesPossible *perimortem* trauma: U**SKELETON NO. 1297—ROW 1  
(FIGS. 37 & 92)***Taphonomy/Preservation*

The skeleton is placed on its right side in an E–W direction (cranium to the E), with hands in a shackle above the head. It is almost complete; more than 2/3 of the skeletal parts are present. The quality of the bones is intermediate, and around 1/3–2/3 of the bones have a pronounced degree of erosion of surfaces and fragmentation.

Quantitative preservation: 3

Qualitative preservation: 2

*Position*

Skeleton: Lateral—on the right side

Cranium: Lateral—on the right side

Limbs: Left upper limb—flexed, Left hand—U, Left lower limb—flexed, Right upper limb—U, Right hand—U, Right lower limb—flexed

*Relation to other skeletons*

Right lower leg and foot are placed on the lower legs of skeleton no. 1342

*Finds*

Shackles: Yes—wrists

*Estimate of sex: Undetermined*

Criteria: Skull

*Skull*

Skull—trait	Left	L/R	Right
Angle of the frontal		U	
Frontal/parietal eminences		U	
Nuchal crest		U	
Mastoid process	4		U
Zygomatic bone	1–2		U
Orbital outline	U		U
Supraorbital margin	U		U
Glabella		U	
Gonial angle flare	3		U
Mental eminence		U	

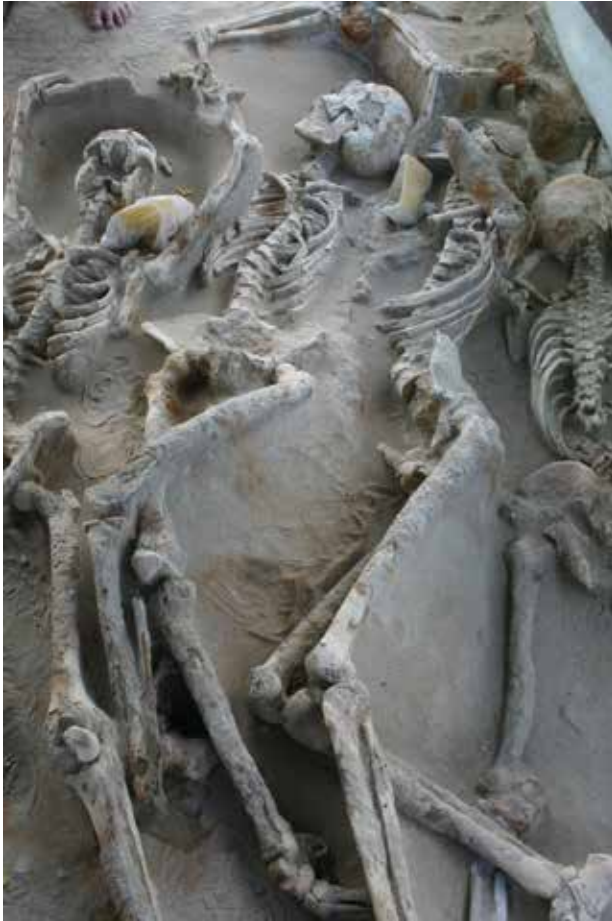

Fig. 91. Skeleton no. 1296.



Fig. 92. Skeleton no. 1297.

*Estimate of age at death: Young adult*

Criteria: Epiphyses, suture closure, and tooth eruption

*Epiphyses*

Skull (cranium + mandible)	U
Thorax (sternum + ribs)	U
Vertebral column	U
Shoulder girdle (clavicle + scapula)	>29
Upper limbs	>17
Pelvis (coxae + sacrum + coccygis)	>23
Lower limbs	>18

*Suture closure (ectocranial)*

Coronal	U
Sagittal	Open
Lambdoid	Open

*Tooth eruption, M3*

Maxilla	Mandible
Sin—U	U
Dx—erupted	

*Pathology/Trauma*

*Antemortem* trauma: U

Likely *perimortem* trauma: U

Possible *perimortem* trauma: U

**FROM THE AREA OF SKELETONS NOS. 1318, 1336, 1355, AND 1373: SOME UNASSOCIATED BONES (FIG. 6)**

A) north of skeleton no. 1318—carpals and metacarpals II–V and two first phalanges laying on skeleton no. 1318 right ulna; (B) A right humerus not belonging to any of the skeletons (?) with transverse fracture on middle diaphysis, probably postmortem; (C) A left humerus with proximal epiphysis under the right lower leg of skeleton no. 1355. Distal epiphysis is fused, epicondylar measurement 65 mm

= male?; (D) A right coxa, fragmented but complete, pubis not observable, greater sciatic notch = 4 male?; ilium resting on the lower legs of skeleton no. 1355; (E) A left partly articulated hand with metacarpal II–V?, some carpals and phalanges with transverse fractures, palmar side up, fingers pointing to skeleton no. 1373 right scapula.; (F) A right radius, positioned across the left arm of skeleton no. 1355.

**SKELETON NO. 1318—ROW I (FIGS. 12–13 & 93)**

*Taphonomy/Preservation*

The skeleton is placed in a supine position in an E–W direction (cranium missing), with hands in a shackle above the head (probably in the E). The skeleton is significantly disturbed, probably by the



Fig. 93. Skeleton no. 1318.



Fig. 94. Skeleton no. 1324.

interment of skeleton no. 1336. Only legs, feet, the pelvic girdle, the lower part of the lumbar spine, lower arms, and hands are present. Cranium and trunk are missing. The left foot is displaced beside the left fibula. Some dispersed bones are found near to this skeleton; an ulna and some phalanges of the hand. Less than 1/3 of the skeleton is preserved, and the quality of the bones is poor, but the bones present are well preserved.

Quantitative preservation: 1

Qualitative preservation: 3

*Position*

Skeleton: Supine

Cranium: Missing

Limbs: Left upper limb—flexed, Left hand—U, Left lower limb—flexed, Right upper limb—probably flexed, Right hand—U, Right lower limb—?

*Relation to other skeletons*

Skeleton no. 1336 is placed over the trunk of this skeleton (probably the reason for the disturbances?)

*Finds*

Shackles: Yes—wrists

*Estimate of sex: Male*

Criteria: Pelvis

*Pelvis*

Pelvis—trait	Left	Right
Subpubic concavity	3	U
Ventral arc	3	U
Ischiopubic ramus	2	U
Subpubic angle	3	U
Greater sciatic notch	5	U
Preauricularis sulcus	U	U

*Estimate of age at death: Juvenile*

Criteria: Epiphyses, and pubic symphysis

*Epiphyses*

Skull (cranium + mandible)	U
Thorax (sternum + ribs)	U
Vertebral column	U
Shoulder girdle (clavicle + scapula)	U
Upper limbs	>16
Pelvis (coxae + sacrum + coccygis)	c. 19, <27
Lower limbs	>17, 18–19

*Pubic symphysis*

Left	Right
I:1, c. 18.5	U

*Stature: c. 161 cm (femur sin)*

*Pathology/Trauma*

*Antemortem* trauma: U

Likely *perimortem* trauma: U

Possible *perimortem* trauma: U

**SKELETON NO. 1324—ROW I**  
(FIGS. 52 & 94)

*Taphonomy/Preservation*

The skeleton is placed in a supine position in a NNE–SSW direction (cranium to the NNE), with hands in a shackle above the head (on a higher level). Head is resting on its right side. The skeleton is almost complete; more than 2/3 of the skeletal parts are present, and they are well preserved.

Quantitative preservation: 3

Qualitative preservation: 3

*Position*

Skeleton: Supine

Cranium: Lateral—on the right side

Limbs: Left upper limb—flexed, Left hand—flexed, Left lower limb—flexed, Right upper limb—flexed, Right hand—flexed, Right lower limb—flexed

*Relation to other skeletons*

The distal part of the right humerus is under the hands of skeleton no. 1289.

*Finds*

Shackles: Yes—wrists

*Estimate of sex: Male*

Criteria: Skull, pelvis, and measurement

*Skull*

Skull—trait	Left	L/R	Right
Angle of the frontal		Sloped	
Frontal/parietal eminences		No	
Nuchal crest		4–5	
Mastoid process	4		U
Zygomatic bone	2		U
Orbital outline	3		3
Supraorbital margin	3		3
Glabella		4	
Gonial angle flare	3		U
Mental eminence		4	

*Pelvis*

Pelvis—trait	Left	Right
Subpubic concavity	3	3
Ventral arc	3	3
Ischiopubic ramus	U	2
Subpubic angle	U	U
Greater sciatic notch	4	4
Preauricularis sulcus	U	U

*Measurement*

46.3 cm (femur dx, maximum head)

*Estimate of age at death: Middle adult*

Criteria: Epiphyses, suture closure, pubic symphysis, and tooth eruption

*Epiphyses*

Skull (cranium + mandible)	U
Thorax (sternum + ribs)	U
Vertebral column	U
Shoulder girdle (clavicle + scapula)	>23
Upper limbs	>20
Pelvis (coxae + sacrum + coccygis)	>23
Lower limbs	>20

*Suture closure (ectocranial)*

Coronal	Significant
Sagittal	U
Lambdoid	Minimal

*Pubic symphysis*

Left	Right
U	IV:1, c. 35.2

*Tooth eruption, M3*

Maxilla	Mandible
Sin/dx—erupted	Sin/dx—erupted

*Stature: 166.13 cm (femur dx)*

*Pathology/Trauma*

*Antemortem* trauma: U

Likely *perimortem* trauma: U

Possible *perimortem* trauma: Y

**SKELETON NO. 1325—ROW I**  
(FIG. 95)

*Taphonomy/Preservation*

The skeleton is placed in a prone position in an E–W direction (cranium to the E), with hands in a shackle above the head. The phalanges of the right hand are slightly displaced. The skeleton is almost complete; more than 2/3 of the skeletal parts are present, and they are well preserved.

Quantitative preservation: 3

Qualitative preservation: 3

*Position*

Skeleton: Prone

Cranium: Prone

Limbs: Left upper limb—flexed, Left hand—U/A, Left lower limb—flexed, Right upper limb—flexed, Right hand—flexed, Right lower limb—flexed

*Relation to other skeletons*

Skull below the right arm of skeleton no. 1343; left leg partly below the right leg of skeleton no. 1343

*Finds*

Shackles: Yes—wrists (connected with skeletons nos. 1342 and 1343)

*Estimate of sex: Male?*

Criteria: Skull, and pelvis

*Skull*

Skull—trait	Left	L/R	Right
Angle of the frontal		U	
Frontal/parietal eminences		U	
Nuchal crest		U	
Mastoid process	U		U
Zygomatic bone	U		U
Orbital outline	U		U
Supraorbital margin	U		U
Glabella		U	
Gonial angle flare	U		3
Mental eminence		U	

*Pelvis*

Pelvis—trait	Left	Right
Subpubic concavity	U	U
Ventral arc	U	U
Ischiopubic ramus	U	U
Subpubic angle	U	U
Greater sciatic notch	3	4
Preauricularis sulcus	U	U

*Estimate of age at death: Adult*

Criteria: Epiphyses, and suture closure

*Epiphyses*

Skull (cranium + mandible)	U
Thorax (sternum + ribs)	U
Vertebral column	U
Shoulder girdle (clavicle + scapula)	U
Upper limbs	>20
Pelvis (coxae + sacrum + coccygis)	>23
Lower limbs	>20

*Suture closure (ectocranial)*

Coronal	U
Sagittal	U
Lambdoid	Minimal

*Stature: 163.75 cm (femur sin)*

*Pathology/Trauma*

*Antemortem* trauma: U

Likely *perimortem* trauma: U

Possible *perimortem* trauma: U



Fig. 95. Skeleton no. 1325.



Fig. 96. Skeleton no. 1328.

**SKELETON NO. 1328—ROW 1  
(FIGS. 53 & 96)**

*Taphonomy/Preservation*

The skeleton is placed in a supine position in a NE–SW direction (cranium to the NE, resting on the left side), with hands in a shackle above the head. Legs are bent to the left; left leg resting on the lateral side and right standing up straight (higher than the rest of the body). Left knee cap, right pelvis, right shoulder joint, and the spinal column (displacement between thoracic vertebra no. 12, and lumbar vertebra no. 1) are significantly disturbed by depositional processes. The skeleton is almost complete; more than 2/3 of the skeletal parts are present, and they are well preserved.

Quantitative preservation: 3

Qualitative preservation: 3

*Position*

Skeleton: Supine (slightly on left side)

Cranium: Supine—slightly to the left

Limbs: Left upper limb—flexed, Left

hand—extended, Left lower limb—

flexed, Right upper limb—flexed, Right

hand—flexed, Right lower limb—flexed

*Relation to other skeletons*

Right hand of skeleton no. 1363 below

skull; left humerus below the left arm

and hand of skeleton no. 1359

*Finds*

Shackles: Yes—wrists

*Estimate of sex: Male*

Criteria: Skull, pelvis, and measurement

*Skull*

Skull—trait	Left	L/R	Right
Angle of the frontal		Sloped	
Frontal/parietal eminences		Slight	
Nuchal crest		U	
Mastoid process	5		U
Zygomatic bone	3		U
Orbital outline	3		U
Supraorbital margin	3		3
Glabella		3	
Gonial angle flare	U		3
Mental eminence		U	

*Pelvis*

Pelvis—trait	Left	Right
Subpubic concavity	3	U
Ventral arc	3	U
Ischiopubic ramus	U	U
Subpubic angle	3	U
Greater sciatic notch	5	U
Preauricularis sulcus	U	U

*Measurement*

48 cm (femur sin, maximum head)

*Estimate of age at death: Young adult*

Criteria: Epiphyses, suture closure, pubic symphysis, tooth eruption, and tooth wear

*Epiphyses*

Skull (cranium + mandible)	U
Thorax (sternum + ribs)	U
Vertebral column	U
Shoulder girdle (clavicle + scapula)	>29
Upper limbs	>20
Pelvis (coxae + sacrum + coccygis)	20–24
Lower limbs	>20

*Suture closure (ectocranial)*

Coronal	Significant—obliterated
Sagittal	Significant—obliterated
Lambdoid	Open

*Pubic symphysis*

Left	Right
III:1 (28.7)	U

*Tooth eruption, M3*

Maxilla	Mandible
Sin—U	Sin—erupted
Dx—erupted	Dx—erupted

*Tooth wear*

Maxilla	Mandible
	25–35

*Stature: c. 168.5 cm (femur sin)*

*Pathology/Trauma*

Dental pathology: Slight calculus on incisors, mandible

*Antemortem* trauma: U

Likely *perimortem* trauma: U

Possible *perimortem* trauma: Y

**SKELETON NO. 1336—ROW 1 (FIGS. 39 & 97)**

*Taphonomy/Preservation*

The skeleton is placed on its left side in a N–S (upper body, with cranium to the S) and an E–W direction (lower body). Hands are placed behind the back, no shackles visible (but traces of iron). The skeleton is almost complete; more than 2/3 of the skeletal parts are present, and they are well preserved.

Quantitative preservation: 3

Qualitative preservation: 3

*Position*

Skeleton: Lateral—on the left side

Cranium: Lateral—on the left side

Limbs: Left upper limb—flexed, Left hand—extended, Left lower limb—extended, Right upper limb—flexed, Right hand—flexed, Right lower limb—extended

*Relation to other skeletons*

The skeleton is placed at an opposite angle to, and on top of skeletons nos. 1366, 1318, 1392, and 1393 and is probably the reason why these latter skeletons are poorly preserved.

*Finds*

Shackles: ?

*Estimate of sex: Undetermined*

Criteria: Skull, and pelvis

*Skull*

Skull—trait	Left	L/R	Right
Angle of the frontal		Sloped	
Frontal/parietal eminences		No	
Nuchal crest		U	
Mastoid process	U		2
Zygomatic bone	U		U
Orbital outline	U		U
Supraorbital margin	U		2
Glabella		U	
Gonial angle flare	U		3
Mental eminence		U	

*Pelvis*

Pelvis—trait	Left	Right
Subpubic concavity	U	U
Ventral arc	U	U
Ischiopubic ramus	U	U
Subpubic angle	U	U
Greater sciatic notch	U	5
Preauricularis sulcus	U	U

*Estimate of age at death: Young adult*

Criteria: Epiphyses, and suture closure

*Epiphyses*

Skull (cranium + mandible)	U
Thorax (sternum + ribs)	U
Vertebral column	U
Shoulder girdle (clavicle + scapula)	U
Upper limbs	>17
Pelvis (coxae + sacrum + coccygis)	>23
Lower limbs	c. 20?

*Suture closure (ectocranial)*

Coronal	Open
Sagittal	Open—minimal
Lambdoid	Open

*Pathology/Trauma*

Cribriform/PH: Porotic hyperostosis? Pinpoint porosity on parietal and occipital—healed

Dental pathology: Blue discoloration on all teeth; I2, C—slight calculus in mandible

*Antemortem* trauma: U

Likely *perimortem* trauma: X

Possible *perimortem* trauma: U

**SKELETON NO. 1339—ROW 1 (FIG. 98)**

*Taphonomy/Preservation*

The skeleton is placed on its right side in an E–W (upper body, with cranium to the W), and NW–SE (lower body, with feet to the SE) direction. Hands are placed behind the back. The skeleton is almost complete; more than 2/3 of the skeletal parts are present, but it is very fragmentary, dry, and cracked.

Quantitative preservation: 3

Qualitative preservation: 2

*Position*

Skeleton: Lateral—on the right side

Cranium: Lateral—on the right side



Fig. 97. Skeleton no. 1336.



Fig. 98. Skeleton no. 1339.

Limbs: Left upper limb—flexed, Left hand—flexed, Left lower limb—flexed, Right upper limb—flexed, Right hand—flexed, Right lower limb—flexed

*Relation to other skeletons*

The skull is placed on the feet of skeleton no. 1340; the legs are placed on the skull of skeleton no. 1340—creating a quadrant in shape

*Finds*

Shackles: No, but according to field observations hands folded on the back—tied

*Estimate of sex: Male*

Criteria: Skull, and pelvis

*Skull*

Skull—trait	Left	L/R	Right
Angle of the frontal		Sloped	
Frontal/parietal eminences		No	
Nuchal crest		2	
Mastoid process	4		U
Zygomatic bone	U		U
Orbital outline	U		3
Supraorbital margin	U		4
Glabella		5	
Gonial angle flare	U		U
Mental eminence		4	

*Pelvis*

Pelvis—trait	Left	Right
Subpubic concavity	U	U
Ventral arc	U	U
Ischiopubic ramus	U	U
Subpubic angle	U	U
Greater sciatic notch	U	4
Preauricular sulcus	U	U

*Estimate of age at death: Adult*

Criteria: Suture closure, and tooth eruption

*Suture closure (ectocranial)*

Coronal	Minimal—significant
Sagittal	Minimal
Lambdoid	Minimal

*Tooth eruption, M3*

Maxilla	Mandible
Sin—erupted	Sin—erupted
Dx—U	Dx—U

Stature: 161.37 cm (femur dx)

*Pathology/Trauma*

Dental pathology: Orange discolouration on all teeth; slight LEH on left C and P1 mandible; slight calculus on left I1, and C, mandible; slight LEH on left C, and P1, maxilla

*Antemortem* trauma: U

Likely *perimortem* trauma: U

Possible *perimortem* trauma: X

**SKELETON NO. 1340—ROW I (FIGS. 33 & 99)**

*Taphonomy/Preservation*

The skeleton is placed on its right side in a NE–SW (upper body, with cranium to the NE), and a N–S (lower body, with feet to the N) direction. Hands are placed behind the back. Approximately half of the skeleton is preserved, and these parts are in good condition.

Quantitative preservation: 2

Qualitative preservation: 3

*Position*

Skeleton: Lateral—on the right side

Cranium: Lateral—on the right side

Limbs: Left upper limb—extended, Left hand—flexed, Left lower limb—flexed, Right upper limb—U, Right hand—U, Right lower limb—flexed

*Relation to other skeletons*

The skull is placed below the legs of skeleton no. 1339; the feet is placed below the skull of skeleton no. 1339—creating a quadrant in shape

*Finds*

Shackles: No, but according to field observations hands folded on the back—tied

*Estimate of sex: Male*

Criteria: Skull, and pelvis

*Skull*

Skull—trait	Left	L/R	Right
Angle of the frontal		Sloped	
Frontal/parietal eminences		No	
Nuchal crest		4	
Mastoid process	5		U
Zygomatic bone	3		U
Orbital outline	U		U
Supraorbital margin	4		U
Glabella		5	
Gonial angle flare	U		U
Mental eminence		4	

*Pelvis*

Pelvis—trait	Left	Right
Subpubic concavity	U	U
Ventral arc	U	U
Ischiopubic ramus	U	U
Subpubic angle	U	U
Greater sciatic notch	4	4
Preauricularis sulcus	U	U

*Estimate of age at death: Young adult*

Criteria: Epiphyses, suture closure, and tooth wear

*Epiphyses*

Skull (cranium + mandible)	U
Thorax (sternum + ribs)	U
Vertebral column	U
Shoulder girdle (clavicle + scapula)	>29
Upper limbs	>17
Pelvis (coxae + sacrum + coccygis)	U
Lower limbs	>20

*Suture closure (ectocranial)*

Coronal	Significant
Sagittal	U
Lambdoid	Significant

*Tooth wear*

Maxilla	Mandible
25–35	U

Stature: 168.51 cm (femur sin)

*Pathology/Trauma*

Dental pathology: Slight calculus on left and right I1, I2, and C, mandible

Cribra/PH: “orange peel” porosity (healed) on posterior dx parietal and some on occipital

*Antemortem* trauma: U

Likely *perimortem* trauma: U

Possible *perimortem* trauma: U

**SKELETON NO. 1342—ROW I (FIG. 100)**

*Taphonomy/Preservation*

The skeleton is placed in a prone position in an E–W direction (cranium to the E), with hands in a shackle above the head. Skull is prone, resting on the left side. The skeleton is almost complete; more than 2/3 of the skeletal parts are present, and they are well preserved.

Quantitative preservation: 3

Qualitative preservation: 3

*Position*

Skeleton: Prone

Cranium: Prone—on left side

Limbs: Left upper limb—extended, Left hand—flexed, Left lower limb—extended, Right upper limb—flexed, Right hand—flexed, Right lower limb—flexed

*Relation to other skeletons*

Left tibia (proximal part) is below the lower legs of skeleton no. 1297; right humerus is above the skull of skeleton no. 1343

*Finds*

Shackles: Yes—wrists, shackles connected with skeletons nos. 1343 and 1325

*Estimate of sex: Undetermined*

Criteria: Skull, and pelvis

*Skull*

Skull—trait	Left	L/R	Right
Angle of the frontal		Straight	
Frontal/parietal eminences		Yes	
Nuchal crest		5	
Mastoid process	U		4
Zygomatic bone	U		1
Orbital outline	U		1
Supraorbital margin	U		1
Glabella		U	
Gonial angle flare	U		2
Mental eminence		U	



Fig. 99. Skeleton no. 1340.



Fig. 100. Skeleton no. 1342.

*Pelvis*

Pelvis—trait	Left	Right
Subpubic concavity	U	U
Ventral arc	U	U
Ischiopubic ramus	U	U
Subpubic angle	U	U
Greater sciatic notch	S	U
Preauricularis sulcus	U	U

*Estimate of age at death: Adult*

Criteria: Epiphyses, and suture closure

*Epiphyses*

Skull (cranium + mandible)	U
Thorax (sternum + ribs)	U
Vertebral column	U
Shoulder girdle (clavicle + scapula)	>20
Upper limbs	>15
Pelvis (coxae + sacrum + coccygis)	>23
Lower limbs	>18

*Suture closure (ectocranial)*

Coronal	Open
Sagittal	Minimal
Lambdoid	Minimal

*Pathology/Trauma*

*Antemortem* trauma: U

Likely *perimortem* trauma: U

Possible *perimortem* trauma: U

**SKELETON NO. 1343—ROW I  
(FIGS. 26–27 & 101)**

*Taphonomy/Preservation*

The skeleton is placed on its left side in an E–W direction (cranium to the E), with hands connected to a shackle above the head. The skeleton is almost complete; more than 2/3 of the skeletal parts are present, and they are well preserved.

Quantitative preservation: 3

Qualitative preservation: 3

*Position*

Skeleton: Lateral—on the left side

Cranium: Lateral—on the left side, face almost prone

Limbs: Left upper limb—flexed, Left hand—U, Left lower limb—flexed, Right upper limb—flexed, Right hand—U, Right lower limb—flexed

*Relation to other skeletons*

Right arm placed on skull of skeleton no. 1325; right leg placed on left leg of skeleton no. 1325

*Finds*

Shackles: Yes—wrists, shackles connected with skeletons nos. 1342 and 1325

*Estimate of sex: Undetermined*

Criteria: Skull, and pelvis

*Skull*

Skull—trait	Left	L/R	Right
Angle of the frontal		Straight	
Frontal/parietal eminences		Slight	
Nuchal crest		U	
Mastoid process	U		4
Zygomatic bone	U		U
Orbital outline	U		U
Supraorbital margin	U		U
Glabella		U	
Gonial angle flare	U		U
Mental eminence		U	

*Pelvis*

Pelvis—trait	Left	Right
Subpubic concavity	U	U
Ventral arc	U	U
Ischiopubic ramus	U	U
Subpubic angle	U	U
Greater sciatic notch	3	U
Preauricularis sulcus	U	U

*Estimate of age at death: Adult*

Criteria: Epiphyses, and suture closure

*Epiphyses*

Skull (cranium + mandible)	U
Thorax (sternum + ribs)	U
Vertebral column	U
Shoulder girdle (clavicle + scapula)	U
Upper limbs	>17
Pelvis (coxae + sacrum + coccygis)	>20
Lower limbs	>18

*Suture closure (ectocranial)*

Coronal	Significant
Sagittal	Significant
Lambdoid	Significant

*Pathology/Trauma*

Dental pathology: LEH on right C (maxilla)

Other: A small resorptive bone lesion (or *postmortem* destruction?)

Lytic lesion on the right parietal, close to coronalis

*Antemortem* trauma: U

Likely *perimortem* trauma: U

Possible *perimortem* trauma: X

**SKELTON NO. 1348—ROW 1**  
(FIGS. 54–55 & 102)

*Taphonomy/Preservation*

The skeleton is placed in a supine position in a NE–SW direction (cranium to the NE), with hands in a shackle above the head. The legs are bent, and the left knee is sticking up above the rest of the body; the right leg is resting on its lateral side. The skeleton is almost complete; more than 2/3 of the skeletal parts are present, and they are well preserved.

Quantitative preservation: 3

Qualitative preservation: 3

*Position*

Skeleton: Supine

Cranium: Supine—slight inclination to the right

Limbs: Left upper limb—flexed, Left hand—flexed, Left lower limb—flexed, Right upper limb—flexed, Right hand—flexed, Right lower limb—flexed

*Relation to other skeletons*

Right leg below the left leg of skeleton no. 1350; right arm above the left shoulder of skeleton no. 1350

*Finds*

Shackles: Yes—wrists

*Estimate of sex: Male?*

Criteria: Skull, pelvis, and measurement

*Skull*

Skull—trait	Left	L/R	Right
Angle of the frontal		Sloped	
Frontal/parietal eminences		No	
Nuchal crest		U	
Mastoid process	3		U
Zygomatic bone	2		U
Orbital outline	3		U
Supraorbital margin	2		2
Glabella		3	
Gonial angle flare	2		U
Mental eminence		3	

*Pelvis*

Pelvis—trait	Left	Right
Subpubic concavity	U	U
Ventral arc	3	3
Ischiopubic ramus	U	U
Subpubic angle	U	U
Greater sciatic notch	4	4
Preauricularis sulcus	U	U

*Measurement*

47.7 cm (femur dx, maximum head)

*Estimate of age at death: Young adult*

Criteria: Epiphyses, suture closure, pubic symphysis, tooth eruption, and tooth wear

*Epiphyses*

Skull (cranium + mandible)	U
Thorax (sternum + ribs)	>25
Vertebral column	U
Shoulder girdle (clavicle + scapula)	24–29
Upper limbs	>20
Pelvis (coxae + sacrum + coccygis)	>23
Lower limbs	>20

*Suture closure (ectocranial)*

Coronal	Minimal
Sagittal	U
Lambdoid	U

*Pubic symphysis*

Left	Right
II:1, c. 23.4	II:1, c. 23.4

*Tooth eruption, M3*

Maxilla	Mandible
Sin—erupted	Sin/dx—not present
Dx—not present	

*Tooth wear*

Maxilla	Mandible
U	17–25

*Stature: 161.37 cm (femur dx)*

*Pathology/Trauma*

Dental pathology: Congenital absence of right M3 in mandible and maxilla; slight linear hypoplasia on left and right I–C, mandible

*Antemortem* trauma: U

Likely *perimortem* trauma: U

Possible *perimortem* trauma: X

**SKELTON NO. 1349—ROW 1**  
(FIGS. 28–29, 56–57, & 103)

*Taphonomy/Preservation*

The skeleton is placed in a supine position in a NE–SW direction (cranium to the NE), with hands in a shackle above the head. The right arm is displaced. The skeleton is almost complete; more than 2/3 of the skeletal parts are present, and they are well preserved.

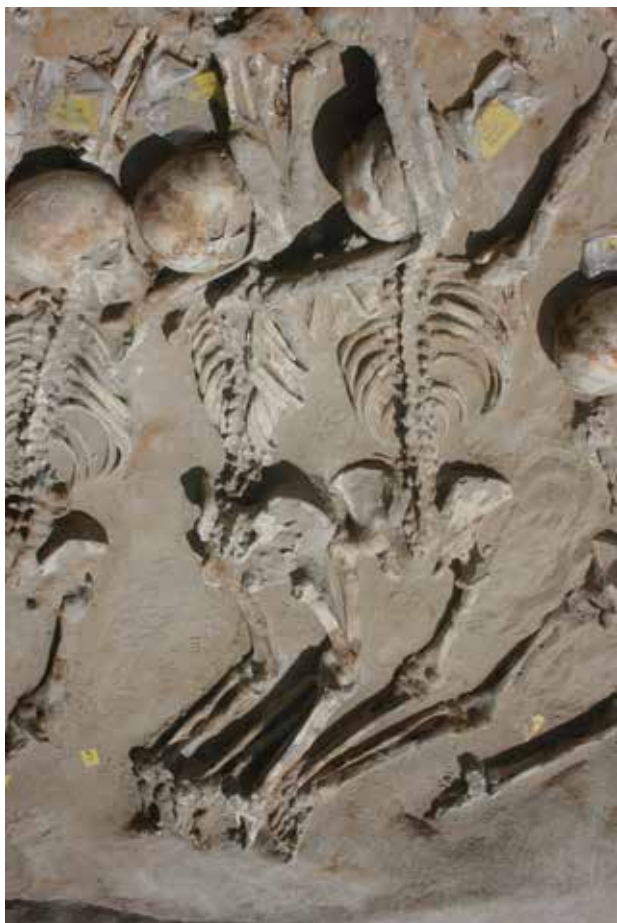

Fig. 101. Skeleton no. 1343.



Fig. 102. Skeleton no. 1348.

Quantitative preservation: 3

Qualitative preservation: 3

*Position*

Skeleton: Supine

Cranium: Supine—slightly inclined to the right

Limbs: Left upper limb—flexed, Left hand—U, Left lower limb—extended, Right upper limb—flexed, Right hand—U, Right lower limb—flexed

*Relation to other skeletons*

Right arm above the left arm of skeleton no. 1281

*Finds*

Shackles: Yes—wrists

*Estimate of sex: Male*

Criteria: Skull, pelvis, and measurement

*Skull*

Skull—trait	Left	L/R	Right
Angle of the frontal		Sloped	
Frontal/parietal eminences		No	
Nuchal crest		U	
Mastoid process	5		5
Zygomatic bone	2		2
Orbital outline	2		2
Supraorbital margin	4		4
Glabella		U	
Gonial angle flare	2		2
Mental eminence		4	

*Pelvis*

Pelvis—trait	Left	Right
Subpubic concavity	U	U
Ventral arc	U	U
Ischiopubic ramus	U	U
Subpubic angle	U	U
Greater sciatic notch	4	U
Preauricularis sulcus	U	U

*Measurement*

48 cm (femur dx, maximum head)

*Estimate of age at death: Middle adult*

Criteria: Epiphyses, suture closure, pubic symphysis, tooth eruption, and tooth wear



Fig. 103. Skeleton no. 1349.



Fig. 104. Skeleton no. 1350.

*Epiphyses*

Skull (cranium + mandible)	U
Thorax (sternum + ribs)	U
Vertebral column	U
Shoulder girdle (clavicle + scapula)	>20
Upper limbs	>20
Pelvis (coxae + sacrum + coccygis)	>23
Lower limbs	>20

*Suture closure (ectocranial)*

Coronal	Significant—obliteration
Sagittal	Obliteration
Lambdoid	U

*Pubic symphysis*

<b>Left</b>	<b>Right</b>
U	V:1, 45.6

*Tooth eruption, M3*

<b>Maxilla</b>	<b>Mandible</b>
Sin—erupting	Sin/dx—erupted
Dx—erupting/erupted?	

*Tooth wear*

<b>Maxilla</b>	<b>Mandible</b>
U	Sin: 25–35 Dx: 17–25

*Stature: 168.51 cm (femur dx)*

*Pathology/Trauma*

Dental pathology: right I1 mandible — chipped *antemortem*

*Antemortem* trauma: U

Likely *perimortem* trauma: U

Possible *perimortem* trauma: X

**SKELETON NO. 1350—ROW I (FIG. 104)**

*Taphonomy/Preservation*

The skeleton is placed in a supine position in a NE–SW direction (cranium to the NE), with hands in a shackle above the head. The legs are bent, and the knees are sticking up above the rest of the body. The skeleton is almost complete; more than 2/3 of the skeletal parts are present, and they are well preserved.

Quantitative preservation: 3

Qualitative preservation: 3

*Position*

Skeleton: Supine

Cranium: Supine, skull inclined on the right side

Limbs: Left upper limb—slightly flexed, Left hand—slightly flexed, Left lower

limb—slightly flexed, Right upper limb—slightly flexed, Right hand—U, Right lower limb—slightly flexed

*Relation to other skeletons*

Right arm below the left arm of skeleton no. 1365; left arm below the right arm of skeleton no. 1348

*Finds*

Shackles: Yes—wrists

*Estimate of sex: Male*

Criteria: Skull, pelvis, and measurement

*Skull*

Skull—trait	Left	L/R	Right
Angle of the frontal		Sloped	
Frontal/parietal eminences		No	
Nuchal crest		U	
Mastoid process	3		U
Zygomatic bone	2		U
Orbital outline	3		U
Supraorbital margin	3		U
Glabella		3	
Gonial angle flare	3		U
Mental eminence		3	

*Pelvis*

Pelvis—trait	Left	Right
Subpubic concavity	3	U
Ventral arc	3	U
Ischiopubic ramus	3	U
Subpubic angle	4	U
Greater sciatic notch	U	U
Preauricularis sulcus	U	U

*Measurement*

43.4 cm (femur dx, maximum head)

*Estimate of age at death: Middle adult*

Criteria: Epiphyses, suture closure, pubic symphysis, tooth eruption, and tooth wear

*Epiphyses*

Skull (cranium + mandible)	U
Thorax (sternum + ribs)	>25
Vertebral column	U
Shoulder girdle (clavicle + scapula)	>29
Upper limbs	>20
Pelvis (coxae + sacrum + coccygis)	>23
Lower limbs	>20

*Suture closure (ectocranial)*

Coronal	Significant
Sagittal	U
Lambdoid	U

*Pubic symphysis*

Left	Right
IV:1, 35.2	U

*Tooth eruption, M3*

Maxilla	Mandible
Sin—A	Sin/dx—present
Dx—present	

*Tooth wear*

Maxilla	Mandible
U	Sin: 17–25 Dx: 25–35

*Stature: 161.37 cm (femur dx)*

*Pathology/Trauma*

Dental pathology: Medium LEH on all teeth in mandible, 2 lines; AMTL M1 sin (maxilla)

*Antemortem* trauma: U

Likely *perimortem* trauma: U

Possible *perimortem* trauma: U

**SKELETON NO. 1353—ROW I  
(FIGS. 40, 58–59, & 105)**

*Taphonomy/Preservation*

The skeleton is placed in a supine position in a NW–SE direction (cranium to the SE), with hands behind the back. skeletons nos. 1354 and 1355 cover the lower part of the body. The skeleton is almost complete; more than 2/3 of the skeletal parts are present, and they are well preserved.

Quantitative preservation: 3

Qualitative preservation: 3

*Position*

Skeleton: Supine

Cranium: Supine

Limbs: Left upper limb—flexed, Left hand—U, Left lower limb—extended, Right upper limb—flexed, Right hand—U, Right lower limb—extended

*Relation to other skeletons*

Right femur below skeleton no. 1354; left femur and tibia below skeleton no. 1355

*Finds*

Shackles: No/not observable (but hands folded on the back and not visible—skeleton resting on back)

*Estimate of sex: Undetermined*

Criteria: Skull, and pelvis

*Skull*

Skull—trait	Left	L/R	Right
Angle of the frontal		Straight	
Frontal/parietal eminences		No	
Nuchal crest		U	
Mastoid process	5		U
Zygomatic bone	3		U
Orbital outline	3		U
Supraorbital margin	2		U
Glabella		3	
Gonial angle flare	3		U
Mental eminence		5	

*Pelvis*

Pelvis—trait	Left	Right
Subpubic concavity	U	U
Ventral arc	U	U
Ischiopubic ramus	U	U
Subpubic angle	U	U
Greater sciatic notch	U	3
Preauricularis sulcus	U	U

*Estimate of age at death: Young adult*

Criteria: Epiphyses, suture closure, tooth eruption, and tooth wear

*Epiphyses*

Skull (cranium + mandible)	U
Thorax (sternum + ribs)	U
Vertebral column	U
Shoulder girdle (clavicle + scapula)	U
Upper limbs	>17
Pelvis (coxae + sacrum + coccygis)	>23
Lower limbs	>15

*Suture closure (ectocranial)*

Coronal	Open—minimal
Sagittal	Open—minimal
Lambdoid	U

*Tooth eruption, M3*

Maxilla	Mandible
Sin/dx—erupted	Sin/dx—erupted

*Tooth wear*

Maxilla	Mandible
U	25–35

*Pathology/Trauma*

Dental pathology: Slight–medium calculus on incisive left mandible and on right I1–C; slight linear hypoplasia on



Fig. 105. Skeleton no. 1353.



Fig. 106. Skeleton no. 1354.

right C and P1 mandible; medium calculus on left and right C maxilla. Pronounced bilateral muscular markings at mentalis.

*Antemortem* trauma: U

Likely *perimortem* trauma: X

Possible *perimortem* trauma: X

**SKELETON NO. 1354—ROW I (FIG. 106)**

*Taponomy/Preservation*

The skeleton is placed in a supine position in a N–S direction (cranium to the S), with hands behind the back. Viscerocranium is crushed. Both lower legs (tibia and fibula) are missing; and also the left foot. Part of the thorax is missing; bodies of the thoracic vertebrae, and half of the ribs. The skeleton is almost com-

plete; more than 2/3 of the skeletal parts are present. The quality of the bones is intermediate, and around 1/3–2/3 of the bones have a pronounced degree of erosion of surfaces and fragmentation.

Quantitative preservation: 3

Qualitative preservation: 2

*Position*

Skeleton: Supine

Cranium: Supine—slightly inclined to the left

Limbs: Left upper limb—flexed, Left hand—U, Left lower limb—flexed, Right upper limb—flexed, Right hand—U, Right lower limb—flexed

*Relation to other skeletons*

The skeleton is lying on top of the lower part of skeleton no. 1353 with legs across skeleton no. 1355.

*Finds*

Shackles: No/not observable (but hands folded on the back and not visible—skeleton resting on back)

*Estimate of sex: Undetermined*

Criteria: Skull, and pelvis

*Skull*

Skull—trait	Left	L/R	Right
Angle of the frontal		U	
Frontal/parietal eminences		No	
Nuchal crest		4	
Mastoid process	U		5
Zygomatic bone	2		U
Orbital outline	U		U
Supraorbital margin	3		U
Glabella		3	
Gonial angle flare	3		U
Mental eminence		3	

*Pelvis*

Pelvis—trait	Left	Right
Subpubic concavity	U	U
Ventral arc	U	U
Ischiopubic ramus	U	U
Subpubic angle	U	U
Greater sciatic notch	3	U
Preauricularis sulcus	N	N

*Estimate of age at death: Middle adult*

Criteria: Epiphyses, suture closure, tooth eruption, and tooth wear

*Epiphyses*

Skull (cranium + mandible)	U
Thorax (sternum + ribs)	U
Vertebral column	U
Shoulder girdle (clavicle + scapula)	>29
Upper limbs	>16
Pelvis (coxae + sacrum + coccygis)	>23
Lower limbs	>20

*Suture closure (ectocranial)*

Coronal	Significant
Sagittal	Significant
Lambdoid	U

*Tooth eruption, M3*

Maxilla	Mandible
Sin—present, but not <i>in situ</i>	Sin/dx—erupted

*Tooth wear*

Maxilla	Mandible
U	25–35

*Pathology/Trauma*

Dental pathology: Ante mortem tooth loss—right M1 mandible

OA: Medium lipping on cervical vertebrae nos. 3–7

*Antemortem* trauma: U

Likely *perimortem* trauma: U

Possible *perimortem* trauma: X

### SKELETON NO. 1355—ROW I (FIGS. 32 & 107)

*Taphonomy/Preservation*

The skeleton is placed on its left side in an approximate N–S direction (with cranium to the S). Legs are bent to the left. Hands are placed behind the back. The skeleton is placed at an opposite angle to, and on top of skeletons nos. 1373 and 1393, and is probably the reason why

this latter skeleton is quite fragmented.

One right radius, not belonging to this individual, was found on the distal part of left humerus. The skeleton is almost complete; more than 2/3 of the skeletal parts are present, and they are well preserved.

Quantitative preservation: 3

Qualitative preservation: 3

*Position*

Skeleton: Lateral (on left side)

Cranium: Lateral (on left side)

Limbs: Left upper limb—flexed, Left hand—A/U, Left lower limb—flexed, Right upper limb—flexed, Right hand—A/U, Right lower limb—flexed

*Relation to other skeletons*

Placed on top of skeletons nos. 1393 and 1373

*Find*

Shackles: No according to diary/hands folded on the back according to field observation

*Estimate of sex: Male*

Criteria: Skull, and pelvis

*Skull*

Skull—trait	Left	L/R	Right
Angle of the frontal		Sloped	
Frontal/parietal eminences		No	
Nuchal crest		5	
Mastoid process	U		5
Zygomatic bone	U		U
Orbital outline	U		U
Supraorbital margin	U		3
Glabella		4	
Gonial angle flare	U		3
Mental eminence		4	

*Pelvis*

Pelvis—trait	Left	Right
Subpubic concavity	U	U
Ventral arc	U	U
Ischiopubic ramus	U	U
Subpubic angle	U	U
Greater sciatic notch	U	5
Preauricularis sulcus	U	U

*Estimate of age at death: Young adult*

Criteria: Epiphyses, suture closure, and tooth eruption

*Epiphyses*

Skull (cranium + mandible)	U
Thorax (sternum + ribs)	U
Vertebral column	U
Shoulder girdle (clavicle + scapula)	U
Upper limbs	>20
Pelvis (coxae + sacrum + coccygis)	>23
Lower limbs	>20

*Suture closure (ectocranial)*

Coronal	Open
Sagittal	Minimal
Lambdoid	Open

*Tooth eruption, M3*

Maxilla	Mandible
Sin—U	Sin/dx—U
Dx—erupted	

*Stature: 163.75 cm (femur dx)*

*Pathology/Trauma*

Dental pathology: Slight LEH linear hypoplasia on left and right I1–I2 in maxilla

Cribriform and PH: Pinpoint porosity on dorsal part of right parietal, expanded diploë

Other: Entesophyte on left fibula (distal diaphysis)

*Antemortem* trauma: U

Likely *perimortem* trauma: U

Possible *perimortem* trauma: X

### SKELETON NO. 1356—ROW I (FIGS. 41 & 108)

*Taphonomy/Preservation*

The skeleton is placed on its left side in a N–S (upper body, with cranium to the S) and an E–W direction (lower body, with feet to the W). Hands are placed behind the back. The skeleton is almost complete; more than 2/3 of the skeletal parts are present, and they are well preserved.

Quantitative preservation: 3

Qualitative preservation: 3

*Position*

Skeleton: Lateral—on left side

Cranium: Lateral—on left side

Limbs: Left upper limb—U, Left hand—probably flexed, Left lower



Fig. 107. Skeleton no. 1355.



Fig. 108. Skeleton no. 1356.

limb—flexed, Right upper limb—extended, Right hand—flexed?, Right lower limb—flexed

*Relation to other skeletons*

Pelvis is close to skeleton no. 1353 and feet close to skeleton no. 1354.

*Finds*

Shackles: No, but according to field observations hands folded on the back—tied.

*Estimate of sex: Male?*

Criteria: Skull, and pelvis

*Skull*

Skull—trait	Left	L/R	Right
Angle of the frontal		Sloped	
Frontal/parietal eminences		Yes	
Nuchal crest		4	
Mastoid process	U		4
Zygomatic bone	U		2
Orbital outline	U		U
Supraorbital margin	U		2
Glabella		3	
Gonial angle flare	U		2
Mental eminence		3	

*Pelvis*

Pelvis—trait	Left	Right
Subpubic concavity	U	U
Ventral arc	U	U
Ischiopubic ramus	U	U
Subpubic angle	U	U
Greater sciatic notch	U	4
Preauricularis sulcus	U	U

*Estimate of age at death: Adult*

Criteria: Epiphyses, suture closure, and tooth eruption

*Epiphyses*

Skull (cranium + mandible)	U
Thorax (sternum + ribs)	U
Vertebral column	U
Shoulder girdle (clavicle + scapula)	U
Upper limbs	>20
Pelvis (coxae + sacrum + coccygis)	>23
Lower limbs	>20

*Suture closure (ectocranial)*

Coronal	Significant
Sagittal	Obliteration
Lambdoid	Significant

*Tooth eruption, M3*

<b>Maxilla</b>	<b>Mandible</b>
Sin—U	Sin—U
Dx—probably not present	Dx—U

*Stature:* 163.75 cm (*femur dx*)

*Pathology/Trauma*

Cribriform and PH: Pinpoint porosity on right parietal near the sagittal suture; even more slight porosity on frontal and occipital, close to sutures

*Antemortem* trauma: U

Likely *perimortem* trauma: X

Possible *perimortem* trauma: U

**SKELETON NO. 1358—ROW I**  
(FIG. 109)

*Taphonomy/Preservation*

The skeleton is placed in a supine position in an E–W direction (cranium to the E), with hands in a shackle above the head. Left humerus, right pelvis, and femur are significantly disturbed. The skeleton is almost complete; more than 2/3 of the skeletal parts are present. The quality of the bones is intermediate, and around 1/3–2/3 of the bones have a pronounced degree of erosion of surfaces and fragmentation.

Quantitative preservation: 3

Qualitative preservation: 2

*Position*

Skeleton: Supine

Cranium: Supine

Limbs: Left upper limb—flexed, Left hand—extended?, Left lower limb—flexed (knees pointing upwards), Right upper limb—flexed, Right hand—extended?, Right lower limb—flexed (knees pointing upwards)

*Relation to other skeletons*

The right leg is positioned above the right leg of skeleton no. 1360; the right arm of skeleton no. 1360 is positioned over the right arm of skeleton no. 1358; the left arm of skeleton no. 1289 is positioned over the left arm of skeleton

no. 1358; the left leg of skeleton no. 1289 is positioned over the left leg of skeleton no. 1358.

 *Finds*

Shackles: Yes—wrists

*Estimate of sex:* Male

Criteria: Skull, and pelvis

*Skull*

Skull—trait	Left	L/R	Right
Angle of the frontal		Sloped	
Frontal/parietal eminences		No	
Nuchal crest		U	
Mastoid process	4		4
Zygomatic bone	3		U
Orbital outline	2		2
Supraorbital margin	3		3
Glabella		5	
Gonial angle flare	U		U
Mental eminence		3	

*Pelvis*

Pelvis—trait	Left	Right
Subpubic concavity	U	U
Ventral arc	U	3
Ischiopubic ramus	U	U
Subpubic angle	U	U
Greater sciatic notch	5	5
Preauricularis sulcus	U	U

*Estimate of age at death:* Middle adult

Criteria: Epiphyses, suture closure, pubic symphysis, tooth eruption, and tooth wear

*Epiphyses*

Skull (cranium + mandible)	U
Thorax (sternum + ribs)	U/A
Vertebral column	U
Shoulder girdle (clavicle + scapula)	>29
Upper limbs	>20
Pelvis (coxae + sacrum + coccygis)	>20
Lower limbs	>20

*Suture closure (ectocranial)*

Coronal	Significant
Sagittal	U
Lambdoid	U

*Pubic symphysis*

Left	Right
U	IV:1, c. 35.2

*Tooth eruption, M3*

<b>Maxilla</b>	<b>Mandible</b>
Sin/dx—erupted	Sin/dx—erupted and wear

*Tooth wear*

<b>Maxilla</b>	<b>Mandible</b>
25–35	25–35

*Pathology/Trauma*

Dental pathology: Caries on left P2 (and M1?) in mandible; linear enamel hypoplasia on left and right C in mandible; right I in mandible with extensive wear

*Antemortem* trauma: U

Likely *perimortem* trauma: U

Possible *perimortem* trauma: X

**SKELETON NO. 1359—ROW I**  
(FIGS. 42 & 110)

*Taphonomy/Preservation*

The skeleton is placed in supine position (especially the lower part of the body) in a NE–SW direction (cranium to the E), with hands in a shackle above the head. The upper body is slightly positioned to the left side. The right leg is flexed over 90 degrees. The left knee is sticking up above the rest of the body. The skeleton is almost complete; more than 2/3 of the skeletal parts are present, and they are well preserved.

Quantitative preservation: 3

Qualitative preservation: 3

*Position*

Skeleton: Supine—inclined to the left  
Cranium: Lateral—skull resting on left side

Limbs: Left upper limb—“extended”, Left hand—U, Left lower limb—extended, Right upper limb—“extended”, Right hand—palm upwards, Right lower limb—flexed

*Relation to other skeletons*

Right arm above the left arm of skeleton no. 1328; left arm below the left arm of skeleton no. 1363

 *Finds*

Shackles: Yes—wrists

*Estimate of sex:* Male

Criteria: Skull, pelvis, and measurement



Fig. 109. Skeleton no. 1358.



Fig. 110. Skeleton no. 1359.

*Skull*

Skull—trait	Left	L/R	Right
Angle of the frontal		Straight	
Frontal/parietal eminences		Slight	
Nuchal crest		U	
Mastoid process	U		5
Zygomatic bone	U		2
Orbital outline	2		2
Supraorbital margin	U		4
Glabella		4	
Gonial angle flare	U		3
Mental eminence		3	

*Pelvis*

Pelvis—trait	Left	Right
Subpubic concavity	3	U
Ventral arc	3	U
Ischiopubic ramus	3	U
Subpubic angle	U	U
Greater sciatic notch	U	U
Preauricularis sulcus	U	U

*Measurement*

44.9 cm (femur sin, maximum head)

*Estimate of age at death: Young adult*

Criteria: Epiphyses, suture closure, pubic symphysis, and tooth eruption

*Epiphyses*

Skull (cranium + mandible)	U
Thorax (sternum + ribs)	U
Vertebral column	U
Shoulder girdle (clavicle + scapula)	>20
Upper limbs	>20
Pelvis (coxae + sacrum + coccygis)	>23, <27?
Lower limbs	>20

*Suture closure (ectocranial)*

Coronal	Minimal
Sagittal	U
Lambdoid	Minimal

*Pubic symphysis*

Left	Right
II:2, c. 23.4	U

*Tooth eruption, M3*

Maxilla	Mandible
Sin/dx—erupted	dx—erupted

Stature: 163.75 cm (*femur sin*)

*Pathology/Trauma*

Dental pathology: Blue discolouration esp. in mandible; linear enamel hypoplasia on right C, PM1, PM2 (max), 2 lines

Other: Long neck

*Antemortem* trauma: U

Likely *perimortem* trauma: X

Possible *perimortem* trauma: U

### SKELETON NO. 1360—ROW 1 (FIG. 111)

*Taphonomy/Preservation*

The skeleton is placed in a prone position in an E–W direction (cranium to the E), with hands in a shackle above the head. Left clavicle is displaced in a horizontal position. The skeleton is almost complete; more than 2/3 of the skeletal parts are present. The quality of the bones is intermediate, and around 1/3–2/3 of the bones have a pronounced degree of erosion of surfaces and fragmentation.

Quantitative preservation: 3

Qualitative preservation: 2

*Position*

Skeleton: Prone

Cranium: Lateral—on left side

Limbs: Left upper limb—extended, Left hand—flexed, Left lower limb—extended, Right upper limb—flexed, Right hand—U, Right lower limb—flexed.

*Relation to other skeletons*

Left pectoral girdle below the left elbow of skeleton no. 1381; the right femur below the right femur of skeleton no. 1358; left lower leg below the right leg of skeleton no. 1381

*Finds*

Shackles: Yes—wrists

*Estimate of sex*: Male?

Criteria: Skull, and pelvis

*Skull*

Skull—trait	Left	L/R	Right
Angle of the frontal		Sloped	
Frontal/parietal eminences		No	
Nuchal crest		3	
Mastoid process	U		4
Zygomatic bone	U		3
Orbital outline	U		U
Supraorbital margin	U		U
Glabella		U	
Gonial angle flare	U		3
Mental eminence		U	

*Pelvis*

Pelvis—trait	Left	Right
Subpubic concavity	U	U
Ventral arc	U	U
Ischiopubic ramus	U	U
Subpubic angle	U	U
Greater sciatic notch	5	U
Preauricularis sulcus	U	U

*Estimate of age at death: Adult*

Criteria: Epiphyses, suture closure, and tooth eruption

*Epiphyses*

Skull (cranium + mandible)	U
Thorax (sternum + ribs)	U
Vertebral column	U
Shoulder girdle (clavicle + scapula)	U
Upper limbs	>17
Pelvis (coxae + sacrum + coccygis)	>23
Lower limbs	>20

*Suture closure (ectocranial)*

Coronal	Minimal
Sagittal	Minimal
Lambdoid	Minimal

*Tooth eruption, M3*

Maxilla	Mandible
Sin—U	Sin—U
Dx—erupted	Dx—U

Stature: 173.63 cm (*humerus dx*)

*Pathology/Trauma*

Dental pathology: U

Other: Marked discolouration on right parietal (posterior)

*Antemortem* trauma: U

Likely *perimortem* trauma: U

Possible *perimortem* trauma: U

### SKELETON NO. 1361—ROW 1 (FIGS. 60 & 112)

*Taphonomy/Preservation*

The skeleton is placed in a supine position in an E–W direction (cranium to the E), with hands in a shackle above the head. The skeleton is almost complete; more than 2/3 of the skeletal parts are present, and they are well preserved.

Quantitative preservation: 3

Qualitative preservation: 3

*Position*

Skeleton: Supine

Cranium: Lateral—resting on left side

Limbs: Left upper limb—flexed, Left hand—U, Left lower limb—flexed, Right upper limb—slightly flexed, Right hand—U, Right lower limb—flexed

*Relation to other skeletons*

Left knee below the right knee of skeleton no. 1366; right knee below the left leg of skeleton no. 1375

*Finds*

Shackles: Yes—wrists

*Estimate of sex*: Male?

Criteria: Skull, pelvis, and measurement

*Skull*

Skull—trait	Left	L/R	Right
Angle of the frontal		Sloped	
Frontal/parietal eminences		No	
Nuchal crest		U	
Mastoid process	U		3
Zygomatic bone	U		3
Orbital outline	U		U
Supraorbital margin	U		2
Glabella		3	
Gonial angle flare	U		3
Mental eminence		3	

*Pelvis*

Pelvis—trait	Left	Right
Subpubic concavity	U	2
Ventral arc	U	3
Ischiopubic ramus	U	3
Subpubic angle	U	3
Greater sciatic notch	U	4
Preauricularis sulcus	U	U

*Measurement*

46 cm (femur dx, maximum head)



Fig. 111. Skeleton no. 1360.



Fig. 112. Skeleton no. 1361.

*Estimate of age at death: Middle adult*

Criteria: Epiphyses, suture closure, pubic symphysis, tooth eruption, and tooth wear

*Epiphyses*

Skull (cranium + mandible)	U
Thorax (sternum + ribs)	U
Vertebral column	U
Shoulder girdle (clavicle + scapula)	>29
Upper limbs	>20
Pelvis (coxae + sacrum + coccygis)	>23
Lower limbs	>20

*Suture closure (ectocranial)*

Coronal	U
Sagittal	Obliteration
Lambdoid	Significant-obliteration

*Pubic symphysis*

<b>Left</b>	<b>Right</b>
IV:1, c. 35.2	U

*Tooth eruption, M3*

<b>Maxilla</b>	<b>Mandible</b>
Sin—U	Sin—erupted
Dx—erupted	Dx—U

*Tooth wear*

<b>Maxilla</b>	<b>Mandible</b>
U	Dx—35–45
	Sin—U

*Stature: 151.85 cm (femur dx)*

*Pathology/Trauma*

Dental pathology: Calculus labial on left and right I1–I2 in mandible

Osteoarthritis: Medium lipping on vertebrae (thoracic vertebrae, lumbar vertebra no. 5, and promotorium on sacrum)

*Antemortem* trauma: U

Likely *perimortem* trauma: U

Possible *perimortem* trauma: X

**SKELETON NO. 1363—ROW I (FIGS. 61 & 113)**

*Taphonomy/Preservation*

The skeleton is placed in a prone position in a NE–SW direction (cranium to the NE), arms extended in 90 degrees from the longitudinal axis of the body. Shackles are found around both wrists.

The skeleton is almost complete; more than 2/3 of the skeletal parts are present, and they are well preserved.

Quantitative preservation: 3

Qualitative preservation: 3

*Position*

Skeleton: Prone

Cranium: Lateral—on left side

Limbs: Left upper limb—flexed, Left hand—extended, palm upwards, Left lower limb—extended, Right upper limb—flexed, Right hand—extended,

palm upwards, Right lower limb—extended

#### Relation to other skeletons

Left arm below skeleton no. 1359; right arm below skeleton no. 1364; lower legs and feet below skeleton no. 1364

#### Finds

Shackles: Yes—wrists

Estimate of sex: *Undetermined*

Criteria: Skull, and pelvis

#### Skull

Skull—trait	Left	L/R	Right
Angle of the frontal		Sloped	
Frontal/parietal eminences		Slight	
Nuchal crest		3	
Mastoid process	U		4
Zygomatic bone	U		2
Orbital outline	1		U
Supraorbital margin	U		3
Glabella		3	
Gonial angle flare	U		2
Mental eminence		U	

#### Pelvis

Pelvis—trait	Left	Right
Subpubic concavity	U	U
Ventral arc	U	U
Ischiopubic ramus	U	U
Subpubic angle	U	U
Greater sciatic notch	3	3
Preauricularis sulcus	U	U

Estimate of age at death: *Young adult*

Criteria: Epiphyses, suture closure, tooth eruption, and tooth wear

#### Epiphyses

Skull (cranium + mandible)	U
Thorax (sternum + ribs)	U
Vertebral column	U
Shoulder girdle (clavicle + scapula)	>20
Upper limbs	>17
Pelvis (coxae + sacrum + coccygis)	>23
Lower limbs	>17

#### Suture closure (ectocranial)

Coronal	Open
Sagittal	Minimal
Lambdoid	Open—minimal

#### Tooth eruption, M3

Maxilla	Mandible
Dx—erupted	Dx—erupted

#### Tooth wear

Maxilla	Mandible
17–25	U

#### Pathology/Trauma

Dental pathology: Large abscess and periodontitis at the alveolus of right M1 in maxilla

Antemortem trauma: U

Likely *perimortem* trauma: U

Possible *perimortem* trauma: X

#### SKELETON NO. 1364—ROW 1 (FIGS. 63 & 114)

#### Taphonomy/Preservation

The skeleton is placed in a supine position in a NE–SW direction (cranium to the NE), with hands in a shackle above the head. The skeleton is almost complete; more than 2/3 of the skeletal parts are present, and they are well preserved.

Quantitative preservation: 3

Qualitative preservation: 3

#### Position

Skeleton: Supine

Cranium: Supine—some inclination towards the left

Limbs: Left upper limb—flexed, Left hand—extended?, Left lower limb—flexed, Right upper limb—flexed, Right hand—flexed?, Right lower limb—flexed

#### Relation to other skeletons

Lower limbs above the lower limbs of skeleton no. 1363

#### Finds

Shackles: Yes—wrists

Estimate of sex: *Male*

Criteria: Skull, and pelvis

#### Skull

Skull—trait	Left	L/R	Right
Angle of the frontal		Straight?	
Frontal/parietal eminences		No	
Nuchal crest		U	
Mastoid process	U		3
Zygomatic bone	1		U
Orbital outline	1		U
Supraorbital margin	2		U
Glabella		U	
Gonial angle flare	2		U
Mental eminence		4	

#### Pelvis

Pelvis—trait	Left	Right
Subpubic concavity	3	3
Ventral arc	3	3
Ischiopubic ramus	3	3
Subpubic angle	3	3
Greater sciatic notch	3	3
Preauricularis sulcus	U	U

Estimate of age at death: *Young adult*

Criteria: Epiphyses, suture closure, pubic symphysis, tooth eruption, and tooth wear

#### Epiphyses

Skull (cranium + mandible)	U
Thorax (sternum + ribs)	A
Vertebral column	U
Shoulder girdle (clavicle + scapula)	>29
Upper limbs	>17
Pelvis (coxae + sacrum + coccygis)	c. 25?
Lower limbs	>20

#### Suture closure (ectocranial)

Coronal	Open
Sagittal	Open
Lambdoid	U

#### Pubic symphysis

Left	Right
II:1, 23.4	U

#### Tooth eruption, M3

Maxilla	Mandible
Dx—erupted	Dx—not fully erupted

#### Tooth wear

Maxilla	Mandible
17–25	17–25



Fig. 113. Skeleton no. 1363.



Fig. 114. Skeleton no. 1364.

*Stature:* 153.04 cm (*femur dx*)

*Pathology/Trauma*

Dental pathology: P2 left maxilla, root *in situ*, caries, possibly some caries on left M1 in maxilla as well?

*Antemortem* trauma: U

Likely *perimortem* trauma: U

Possible *perimortem* trauma: X

**SKELETON NO. 1365—ROW I  
(FIGS. 62 & 115)**

*Taphonomy/Preservation*

The skeleton is placed in a supine position in a NE–SW direction (cranium to the NE), with hands in a shackle above the head. The right foot (with the bones of the foot still articulated) is displaced between right and left tibia. The skull has dropped backwards. The skeleton is

almost complete; more than 2/3 of the skeletal parts are present, and they are well preserved.

Quantitative preservation: 3

Qualitative preservation: 3

*Position*

Skeleton: Supine

Cranium: Supine—some inclination towards the right

Limbs: Left upper limb—flexed, Left hand—U, Left lower limb—extended, Right upper limb—flexed, Right hand—U, Right lower limb—flexed.

*Relation to other skeletons*

Left arm above the right arm of skeleton no. 1350

*Finds*

Shackles: Yes—wrists

*Estimate of sex:* Male?

Criteria: Skull, and pelvis

*Skull*

Skull—trait	Left	L/R	Right
Angle of the frontal		U	
Frontal/parietal eminences		U	
Nuchal crest		U	
Mastoid process	3		U
Zygomatic bone	2		2
Orbital outline	U		U
Supraorbital margin	2		2
Glabella		3	
Gonial angle flare	2		U
Mental eminence		3	



Fig. 115. Skeleton no. 1365.



Fig. 116. Skeleton no. 1366.

*Pelvis*

Pelvis—trait	Left	Right
Subpubic concavity	3	3
Ventral arc	3	3
Ischiopubic ramus	U	U
Subpubic angle	U	U
Greater sciatic notch	U	U
Preauricularis sulcus	U	U

*Estimate of age at death: Juvenile*

Criteria: Epiphyses, suture closure, pubic symphysis, and tooth eruption

*Epiphyses*

Skull (cranium + mandible)	U
Thorax (sternum + ribs)	U
Vertebral column	U
Shoulder girdle (clavicle + scapula)	>18
Upper limbs	>20
Pelvis (coxae + sacrum + coccygis)	15–22, c. 19
Lower limbs	>18– 20

*Suture closure (ectocranial)*

Coronal	Open
Sagittal	U
Lambdoid	U

*Pubic symphysis*

Left	Right
I, 18.5	U

*Tooth eruption, M3*

Maxilla	Mandible
A	M3 dx—not present

*Pathology/Trauma*

Dental pathology: Sin C, mandible; periodontis; LEH on right C and P in mandible

*Antemortem* trauma: U

Likely *perimortem* trauma: U

Possible *perimortem* trauma: X

**SKELETON NO. 1366—ROW I  
(FIGS. 64 & 116)**

*Taphonomy/Preservation*

The skeleton is placed in a supine position in an E–W direction (cranium to the E), with hands in a shackle above the head. The mandible, and the left pecto-

ral girdle and upper arm (clavicle, scapula, and humerus) are missing. A lot of bones of the thorax are fragmented and/or missing; no cervical vertebrae were found, and just a few thoracic vertebrae, lumbar vertebrae, and ribs. Only lumbar vertebrae nos. 4 and 5 are connected to sacrum. The skeleton is almost complete; more than 2/3 of the skeletal parts are present, and they are well preserved.

Quantitative preservation: 2

Qualitative preservation: 3

*Position*

Skeleton: Supine

Cranium: Supine—slightly inclined to the left

Limbs: Left upper limb—flexed, Left hand—flexed, Left lower limb—extended (almost), Right upper limb—flexed, Right hand—flexed, Right lower limb—flexed

*Relation to other skeletons*

Right knee above left knee of skeleton no. 1361; the legs of skeleton no. 1336 are placed above the central parts of the body (probably causing the disturbances seen in the skeleton of skeleton no. 1366?)

*Finds*

Shackles: Yes—wrists

*Estimate of sex: Male?*

Criteria: Skull, and measurement

*Skull*

Skull—trait	Left	L/R	Right
Angle of the frontal		Sloped	
Frontal/parietal eminences		No	
Nuchal crest		4	
Mastoid process	U		3
Zygomatic bone	U		3
Orbital outline	U		3
Supraorbital margin	U		2
Glabella		4	
Gonial angle flare	U		U
Mental eminence		U	

*Measurement*

46 cm (femur dx, maximum head)

*Estimate of age at death: Young adult*

Criteria: Epiphyses, suture closure, tooth eruption, and tooth wear

*Epiphyses*

Skull (cranium + mandible)	U
Thorax (sternum + ribs)	U
Vertebral column	>19
Shoulder girdle (clavicle + scapula)	>20
Upper limbs	>17
Pelvis (coxae + sacrum + coccygis)	>23
Lower limbs	>20

*Suture closure (ectocranial)*

Coronal	Significant
Sagittal	U
Lambdoid	U

*Tooth eruption, M3*

Maxilla	Mandible
Sin/dx—erupted	A

*Tooth wear*

Maxilla	Mandible
17-25/25-35	U

*Stature: 158.99 cm (femur dx)*

*Pathology/Trauma*

Dental pathology: Mandible missing, marked reddish-brown staining on all teeth, especially incisors

Other: Healed periostitis on right tibia (distal diaphysis, medial border)

*Antemortem trauma: U*

Likely *perimortem* trauma: U

Possible *perimortem* trauma: X

**SKELETON NO. 1373—ROW I (FIGS. 43 & 117)**

*Taphonomy/Preservation*

The skeleton is placed in a supine position in an E–W direction (cranium to the E). Right humerus is stretched above the head, but no shackle was found. The right arm (humerus, ulna, and radius), and hand is missing, as well as the right fibula. Some bones from the hand (MCII–V, and some carpals), and a right pelvis (male) that does not belong to this individual, were found beside the right shoulder. The skeleton is almost complete; more than 2/3 of the skeletal parts are present, and they are well preserved.

Quantitative preservation: 3

Qualitative preservation: 3

*Position*

Skeleton: Supine

Cranium: Supine—slightly bent to the left  
Limbs: Left upper limb—flexed, Left hand—U, Left lower limb—slightly flexed, Right upper limb—A, Right hand—A, Right lower limb—slightly flexed

*Relation to other skeletons*

The eastern part of this skeleton is cut by skeleton no. 1355

*Finds*

Shackles: No—not observable

*Estimate of sex: Male?*

Criteria: Skull, pelvis, and measurement

*Skull*

Skull—trait	Left	L/R	Right
Angle of the frontal		Sloped	
Frontal/parietal eminences		No	
Nuchal crest		U	
Mastoid process	U		5
Zygomatic bone	U		3
Orbital outline	U		3
Supraorbital margin	U		2
Glabella		3	
Gonial angle flare	1		1
Mental eminence		5	

*Pelvis*

Pelvis—trait	Left	Right
Subpubic concavity	U	3
Ventral arc	U	3
Ischiopubic ramus	U	3
Subpubic angle	U	U
Greater sciatic notch	U	4
Preauricularis sulcus	U	U

*Measurement*

51 cm (femur sin, maximum head)

*Estimate of age at death: Young adult*

Criteria: Epiphyses, suture closure, pubic symphysis, tooth eruption, and tooth wear

*Epiphyses*

Skull (cranium + mandible)	U
Thorax (sternum + ribs)	U
Vertebral column	U
Shoulder girdle (clavicle + scapula)	U
Upper limbs	>17
Pelvis (coxae + sacrum + coccygis)	>23
Lower limbs	>20



Fig. 117. Skeleton no. 1373.



Fig. 118. Skeleton no. 1374.

*Suture closure (ectocranial)*

Coronal	Significant
Sagittal	U
Lambdoid	U

*Pubic symphysis*

Left	Right
U	IV:1, c. 35.2

*Tooth eruption, M3*

Maxilla	Mandible
Sin/dx—erupted	Sin—U Dx—erupted

*Tooth wear*

Maxilla	Mandible
U	Dx/sin—17–25

*Stature: 158.99 cm (femur dx)*

*Pathology/Trauma*

Dental pathology: Slight calculus on left and right I1–C in maxilla

OA: Medium lipping on two vertebrae (thoracic bodies); slight lipping on left patella

*Antemortem* trauma: U

Likely *perimortem* trauma: X

Possible *perimortem* trauma: U

**SKELETON NO. 1374—ROW 1  
(FIGS. 44, 65, & 118)**

*Taphonomy/Preservation*

The skeleton is placed in a supine position in a NNE–SSW direction (cranium to the NNE), with hands in a shackle above the head. Thorax is fragmented. The skeleton is almost complete; more than 2/3 of the skeletal parts are present, and they are well preserved.

Quantitative preservation: 3

Qualitative preservation: 3

*Position*

Skeleton: Supine

Cranium: Supine

Limbs: Left upper limb—flexed, Left hand—flexed, Left lower limb—flexed, Right upper limb—flexed, Right hand—flexed, Right lower limb—flexed

*Relation to other skeletons*

Right leg below the left knee of skeleton no. 1349; left arm below the arms of skeleton no. 1376

*Finds*

Shackles: Yes—wrists

*Estimate of sex: Male*

Criteria: Skull, pelvis, and measurement

*Skull*

Skull—trait	Left	L/R	Right
Angle of the frontal		Sloped	
Frontal/parietal eminences		No	
Nuchal crest		U	
Mastoid process	4		U
Zygomatic bone	2		U
Orbital outline	U		U
Supraorbital margin	2		U
Glabella		4	
Gonial angle flare	U		3
Mental eminence		5	

*Pelvis*

Pelvis—trait	Left	Right
Subpubic concavity	3	U
Ventral arc	3	U
Ischiopubic ramus	3	U
Subpubic angle	U	U
Greater sciatic notch	5	U
Preauricularis sulcus	U	U

*Measurement*

47.5 cm (femur dx, maximum head)

*Estimate of age at death: Middle adult*

Criteria: Epiphyses, suture closure, pubic symphysis, tooth eruption, and tooth wear

*Epiphyses*

Skull (cranium + mandible)	U
Thorax (sternum + ribs)	U
Vertebral column	U
Shoulder girdle (clavicle + scapula)	>29
Upper limbs	>20
Pelvis (coxae + sacrum + coccygis)	>23
Lower limbs	>20

*Suture closure (ectocranial)*

Coronal	Significant
Sagittal	U
Lambdoid	U

*Pubic symphysis*

Left	Right
V:1, c. 45.6	U

*Tooth eruption, M3*

Maxilla	Mandible
Sin/dx—erupted	Sin/dx—erupted

*Tooth wear*

Maxilla	Mandible
25–35	25–35

*Stature: 170.55 cm (humerus dx)*

*Pathology/Trauma*

Dental pathology: linear enamel hypoplasia, medium on incisors, canines, and premolars in left and right mandible and left and right maxilla, 2 lines; slight calculus on incisors in mandible and left M1.

Other: Marked discolouration on right parietal (posterior)

*Antemortem* trauma: U

Likely *perimortem* trauma: X

Possible *perimortem* trauma: X

**SKELETON NO. 1375—ROW 1 (FIGS. 66 & 119)**

*Taphonomy/Preservation*

The skeleton is placed in a supine position in a NE–SW direction (cranium to the NE), with hands in a shackle above the head. The knees are slightly bent. Right humerus and left elbow joint (ulna) are disturbed by depositional processes. The skeleton is almost complete; more than 2/3 of the skeletal parts are present, and they are well preserved.

Quantitative preservation: 3

Qualitative preservation: 3

*Position*

Skeleton: Supine

Cranium: Lateral—skull resting on the right side

Limbs: Left upper limb—flexed, Left hand—U, Left lower limb—flexed, Right upper limb—flexed, Right hand—U, Right lower limb—flexed

*Relation to other skeletons*

Arms above the skull of skeleton no. 1376

*Finds*

Shackles: Yes—wrists

*Estimate of sex: Male?*

Criteria: Skull, and pelvis

*Skull*

Skull—trait	Left	L/R	Right
Angle of the frontal		Sloped	
Frontal/parietal eminences		No	
Nuchal crest		U	
Mastoid process	3		U
Zygomatic bone	2		U
Orbital outline	3		U
Supraorbital margin	3		U
Glabella		5	
Gonial angle flare	2		U
Mental eminence		2	

*Pelvis*

Pelvis—trait	Left	Right
Subpubic concavity	3	3
Ventral arc	1	1
Ischiopubic ramus	3	3
Subpubic angle	U	U
Greater sciatic notch	U	U
Preauricularis sulcus	U	U

*Estimate of age at death: Old adult*

Criteria: Epiphyses, suture closure, pubic symphysis, tooth eruption, and tooth wear

*Epiphyses*

Skull (cranium + mandible)	U
Thorax (sternum + ribs)	U
Vertebral column	U
Shoulder girdle (clavicle + scapula)	>20
Upper limbs	>20
Pelvis (coxae + sacrum + coccygis)	>23
Lower limbs	>20

*Suture closure (ectocranial)*

Coronal	Significant—obliteration
Sagittal	U
Lambdoid	U

*Pubic symphysis*

Left	Right
VI:1, c. 61.2	VI:1, c. 61.2

*Tooth eruption, M3*

Maxilla	Mandible
Sin—erupted	Sin—erupted
Dx—U	Dx—U



Fig. 119. Skeleton no. 1375.



Fig. 120. Skeleton 1376.

*Tooth wear*

Maxilla	Mandible
U	Sin—25–35

*Stature:* 163.75 cm (*femur dx*)

*Pathology/Trauma*

Left I–C, mandible: medium calculus; left M3, mandible: caries, buccal; LEH, slight—P1 left mandible, P2 left maxilla—slight chipped fracture anterior/buccal; linear enamel hypoplasia on C–PM2, left maxilla.

Osteoarthritis: Slight lipping anterior on thoracic vertebrae nos. 1–4

*Antemortem* trauma: U

Likely *perimortem* trauma: U

Possible *perimortem* trauma: X

**SKELETON NO. 1376—ROW I (FIG. 120)**

*Taphonomy/Preservation*

The upper part of the skeleton is placed in a supine position in a N–S direction (cranium to the N), and the lower part in a lateral position (on the right side) in an E–W direction between skeletons nos. 1375 and 1361. Hands are locked in a shackle above the head. Right femur and left tibia are significantly disturbed by post-depositional processes; twisted to a supine position. The skeleton is almost complete; more than 2/3 of the skeletal parts are present, and they are well preserved.

Quantitative preservation: 3

Qualitative preservation: 3

*Position*

Skeleton: Supine (skull and upper body), Lateral on the right side (lower body)

Cranium: Supine

Limbs: Left upper limb—slightly flexed, Left hand—U, Left lower limb—flexed, Right upper limb—slightly flexed, Right hand—extended, Right lower limb—extended

*Relation to other skeletons*

Skull below the arms of skeleton no. 1375

*Finds*

Shackles: Yes—wrists

*Estimate of sex:* Male

Criteria: Skull, and pelvis

*Skull*

Skull—trait	Left	L/R	Right
Angle of the frontal		U	
Frontal/parietal eminences		U	
Nuchal crest		U	
Mastoid process	U		U
Zygomatic bone	3		U
Orbital outline	U		U
Supraorbital margin	2		U
Glabella		U	
Gonial angle flare	U		U
Mental eminence		U	

*Pelvis*

Pelvis—trait	Left	Right
Subpubic concavity	U	3
Ventral arc	U	3
Ischiopubic ramus	U	3
Subpubic angle	U	U
Greater sciatic notch	U	4
Preauricularis sulcus	U	U

*Estimate of age at death: Young adult*

Criteria: Epiphyses, suture closure, pubic symphysis, tooth eruption, and tooth wear

*Epiphyses*

Skull (cranium + mandible)	U
Thorax (sternum + ribs)	>16
Vertebral column	U
Shoulder girdle (clavicle + scapula)	>29
Upper limbs	>20
Pelvis (coxae + sacrum + coccygis)	>23
Lower limbs	>19

*Suture closure (ectocranial)*

Coronal	Significant
Sagittal	U
Lambdoid	U

*Pubic symphysis*

Left	Right
U	III:1, c. 28.7

*Tooth eruption, M3*

Maxilla	Mandible
Sin/dx—U	Sin—erupted Dx—U

*Tooth wear*

Maxilla	Mandible
U	Sin—17–25

*Stature: 161.37 cm (femur dx)*

*Pathology/Trauma*

*Antemortem* trauma: U  
Likely *perimortem* trauma: U  
Possible *perimortem* trauma: X

**SKELETON NO. 1379—ROW I (FIG. 121)**

*Taphonomy/Preservation*

The skeleton is placed on its left side/prone in an E–W direction (cranium to the E), with the right hand connected to a shackle above the head. The left arm is probably located below the body. It is almost complete; more than 2/3 of the skeletal parts are present. The quality of the bones is intermediate, and around 1/3–2/3 of the bones have a pronounced degree of erosion of surfaces and fragmentation.

Quantitative preservation: 3

Qualitative preservation: 2

*Position*

Skeleton: Lateral, on left side, prone  
Cranium: Almost prone (on left side)  
Limbs: Left upper limb—U, Left hand—U, Left lower limb—flexed, Right upper limb—flexed, Right hand—flexed, Right lower limb—flexed

*Relation to other skeletons*

Between skeleton no.1325 and skeleton no.1380. The right arm is close to the back of no. 1380.

*Finds*

Shackles: Yes—right wrist (left not excavated or not present)

*Estimate of sex: Male*

Criteria: Skull, and pelvis

*Skull*

Skull—trait	Left	L/R	Right
Angle of the frontal		Sloped	
Frontal/parietal eminences		No	
Nuchal crest		U	
Mastoid process	U		4
Zygomatic bone	U		U
Orbital outline	U		U
Supraorbital margin	U		3
Glabella		4	
Gonial angle flare	U		5
Mental eminence		U	

*Pelvis*

Pelvis—trait	Left	Right
Subpubic concavity	U	U
Ventral arc	U	U
Ischiopubic ramus	U	U
Subpubic angle	U	U
Greater sciatic notch	5	5
Preauricularis sulcus	U	U

*Estimate of age at death: Young adult*

Criteria: Epiphyses, and suture closure

*Epiphyses*

Skull (cranium + mandible)	A
Thorax (sternum + ribs)	U
Vertebral column	U
Shoulder girdle (clavicle + scapula)	U
Upper limbs	>17
Pelvis (coxae + sacrum + coccygis)	>23
Lower limbs	c. 20

*Suture closure (ectocranial)*

Coronal	Open
Sagittal	Minimal—significant
Lambdoid	Minimal

*Stature: 161.37 cm (femur sin)*

*Pathology/Trauma*

*Antemortem* trauma: U  
Likely *perimortem* trauma: U  
Possible *perimortem* trauma: U

**SKELETON NO. 1380—ROW I (FIGS. 67 & 122)**

*Taphonomy/Preservation*

The upper body of the skeleton is placed on its left side; the lower body is supine. The skeleton is placed in an E–W direction (cranium to the E), with at least the right hand in a shackle above the head. Thorax is very fragmented. It is almost complete; more than 2/3 of the skeletal parts are present. The quality of the bones is intermediate, and around 1/3–2/3 of the bones have a pronounced degree of erosion of surfaces and fragmentation.

Quantitative preservation: 3

Qualitative preservation: 2

*Position*

Skeleton: Lateral, on left side (upper body); supine (lower body)

Cranium: Lateral—on left side



Fig. 121. Skeleton no. 1379.



Fig. 122. Skeleton no. 1380.

Limbs: Left upper limb—extended, Left hand—slightly flexed—pointed, Left lower limb—slightly flexed, Right upper limb—flexed, Right hand—U, Right lower limb—slightly flexed

*Relation to other skeletons*

Feet and lower legs above the legs of skeleton no. 1381

*Finds*

Shackles: Yes—right wrist

*Estimate of sex: Male?*

Criteria: Skull

*Skull*

Skull—trait	Left	L/R	Right
Angle of the frontal		Sloped	
Frontal/parietal eminences		No	
Nuchal crest		2	
Mastoid process	U		5
Zygomatic bone	U		2
Orbital outline	U		3
Supraorbital margin	U		3
Glabella		3	
Gonial angle flare	U		U
Mental eminence		5	

*Estimate of age at death: Juvenile*

Criteria: Epiphyses, suture closure, and tooth eruption

*Epiphyses*

Skull (cranium + mandible)	U
Thorax (sternum + ribs)	U
Vertebral column	U
Shoulder girdle (clavicle + scapula)	U/A
Upper limbs	>17
Pelvis (coxae + sacrum + coccygis)	U/A
Lower limbs	>17–20

*Suture closure (ectocranial)*

Coronal	Open
Sagittal	Open
Lambdoid	Open

*Tooth eruption, M3*

Maxilla	Mandible
Sin—U	Sin—U
Dx—erupting	Dx—erupting

Stature: 161.37 cm (femur sin)

*Pathology/Trauma*

Dental pathology: Possible buccal caries on right M2 in mandible (CEJ)

Cribra and PH: Possible Porotic hyperostosis on right parietal—or *postmortem*

Other: Dark demarcated area with possibly some iron attached on frontal

*Antemortem* trauma: U

Likely *perimortem* trauma: U

Possible *perimortem* trauma: X

**SKELETON NO. 1381—ROW I (FIGS. 68 & 123)**

*Taphonomy/Preservation*

The skeleton is placed in a supine position in an E–W direction (cranium to the E), with hands in a shackle above the head. Left femur is twisted; the dorsal side with trochanter minor pointing upwards. The skeleton is almost complete; more than 2/3 of the skeletal parts are present, and they are well preserved.

Quantitative preservation: 3

Qualitative preservation: 3

*Position*

Skeleton: Supine

Cranium: Supine—skull resting on left side

Limbs: Left upper limb—flexed, Left hand—flexed, Left lower limb—flexed, Right upper limb—flexed, Right hand—flexed, Right lower limb—flexed.

*Relation to other skeletons*

Right pelvis below femur (distal end) of skeleton no. 1380; left femur below the right tibia of skeleton no. 1360; left tibia/fibula below the right tibia/fibula and feet of skeleton no. 1380

*Finds*

Iron staining of soil, left of the left pelvis

Shackles: Yes—wrists

*Estimate of sex: Male?*

Criteria: Skull, and pelvis

*Skull*

Skull—trait	Left	L/R	Right
Angle of the frontal		Sloped	
Frontal/parietal eminences		No	
Nuchal crest		U	
Mastoid process	5		U
Zygomatic bone	2		U
Orbital outline	3		U
Supraorbital margin	2		U
Glabella		2	
Gonial angle flare	3		U
Mental eminence		3	

*Pelvis*

Pelvis—trait	Left	Right
Subpubic concavity	U	U
Ventral arc	3	U
Ischiopubic ramus	3	U
Subpubic angle	U	U
Greater sciatic notch	3	U
Preauricularis sulcus	U	U

*Estimate of age at death: Young adult*

Criteria: Epiphyses, suture closure, pubic symphysis, tooth eruption, and tooth wear

*Epiphyses*

Skull (cranium + mandible)	U
Thorax (sternum + ribs)	A
Vertebral column	U
Shoulder girdle (clavicle + scapula)	>29
Upper limbs	>17
Pelvis (coxae + sacrum + coccygis)	>23
Lower limbs	>20

*Suture closure (ectocranial)*

Coronal	Significant
Sagittal	U
Lambdoid	U

*Pubic symphysis*

Left	Right
III:1, 28.7	U

*Tooth eruption, M3*

Maxilla	Mandible
Sin/dx—erupted	A/U

*Tooth wear*

Maxilla	Mandible
Uneven wear 17–35	Uneven wear 17–35

Stature: 166.13 cm (femur dx)

*Pathology/Trauma*

Dental pathology: M1 left mandible—deep wear and caries (fracture?)—buccal/mesial; M1 right mandible almost no wear; M2 right mandible deep wear occlusal/distal; slight to medium calculus on right mandible incisors and C.

*Antemortem* trauma: U

Likely *perimortem* trauma: U

Possible *perimortem* trauma: X

**SKELETON NO. 1382—ROW I (FIG. 124)**

*Taphonomy/Preservation*

The skeleton is placed in a supine position in an E–W direction (cranium to the E), with wrists folded over the skull. Right ulna, and hand are displaced. The skeleton is almost complete; more than 2/3 of the skeletal parts are present, and they are well preserved.

Quantitative preservation: 3

Qualitative preservation: 3

*Position*

Skeleton: Supine

Cranium: Supine—skull inclined to the left side

Limbs: Left upper limb—flexed, Left hand—flexed, Left lower limb—flexed, Right upper limb—flexed, Right hand—flexed, Right lower limb—flexed

*Relation to other skeletons*

Located between the skeleton no. 1373 and skeleton no. 1383. The lower right leg is close to, and lateral to the left femur of skeleton no. 1373.

*Finds*

Shackles: No but according to field observation wrists folded over the skull—seems to have been tied

*Estimate of sex: Male*

Criteria: Skull, and pelvis



Fig. 123. Skeleton no. 1381.



Fig. 124. Skeleton no. 1382.

*Skull*

Skull—trait	Left	L/R	Right
Angle of the frontal		Sloped	
Frontal/parietal eminences		No	
Nuchal crest		U	
Mastoid process	U		U
Zygomatic bone	U		3
Orbital outline	U		3
Supraorbital margin	U		3
Glabella		4	
Gonial angle flare	(U		3)
Mental eminence		5	

*Pelvis*

Pelvis—trait	Left	Right
Subpubic concavity	5	5
Ventral arc	U	U
Ischiopubic ramus	U	U
Subpubic angle	5	U
Greater sciatic notch	5	U
Preauricularis sulcus	U	U

*Estimate of age at death: Young adult*

Criteria: Epiphyses, suture closure, pubic symphysis, tooth eruption, and tooth wear

*Epiphyses*

Skull (cranium + mandible)	U
Thorax (sternum + ribs)	U
Vertebral column	U
Shoulder girdle (clavicle + scapula)	>17
Upper limbs	>20
Pelvis (coxae + sacrum + coccygis)	>23
Lower limbs	>20

*Suture closure (ectocranial)*

Coronal	Significant
Sagittal	U
Lambdoid	U

*Pubic symphysis*

Left	Right
III:1, 28.7	III:1, 28.7

*Tooth eruption, M3*

Maxilla	Mandible
U	Sin—U Dx—A

*Tooth wear*

Maxilla	Mandible
U	25–35

*Stature: 158.99 cm (femur dx and sin)*

*Pathology/Trauma*

Dental pathology: medium calculus on left I1–C, and right I1–I2, mandible

*Antemortem* trauma: U

Likely *perimortem* trauma: U

Possible *perimortem* trauma: X

**SKELETON NO. 1383—ROW I**  
(FIGS. 45, 69, & 125)

*Taphonomy/Preservation*

The skeleton is placed in a supine position, slightly leaning to the left, in an E–W direction (cranium to the E), with right wrist attached to a shackle above the head. Legs bent to the left side. The skeleton is almost complete; more than 2/3 of the skeletal parts are present, and they are well preserved.

Quantitative preservation: 3

Qualitative preservation: 3

*Position*

Skeleton: Supine—slightly leaning to the left

Cranium: Lateral—skull resting on the left side

Limbs: Left upper limb—flexed, Left hand—extended, palm upwards, Left lower limb—flexed, Right upper limb—extended above head, Right hand—flexed, Right lower limb—flexed

*Relation to other skeletons*

The right arm is placed below the right arm of skeleton no. 1390

*Finds*

Shackles: Yes—right wrist

*Estimate of sex: Male*

Criteria: Skull, pelvis, and measurement

Skull—trait	Left	L/R	Right
Angle of the frontal		Sloped	
Frontal/parietal eminences		No	
Nuchal crest		U	
Mastoid process	U		U
Zygomatic bone	U		3
Orbital outline	U		U
Supraorbital margin	U		2
Glabella		3	
Gonial angle flare	U		3
Mental eminence		3	

*Pelvis*

Pelvis—trait	Left	Right
Subpubic concavity	3	U
Ventral arc	3	U
Ischiopubic ramus	U	U
Subpubic angle	3	U
Greater sciatic notch	5	U
Preauricularis sulcus	U	U

*Measurement*

48 cm (femur sin, maximum head)

*Estimate of age at death: Juvenile*

Criteria: Epiphyses, suture closure, pubic symphysis, tooth eruption, and tooth wear

*Epiphyses*

Skull (cranium + mandible)	U
Thorax (sternum + ribs)	U
Vertebral column	U
Shoulder girdle (clavicle + scapula)	16–21
Upper limbs	≥20
Pelvis (coxae + sacrum + coccygis)	c. 19–20
Lower limbs	c. 18–20

*Suture closure (ectocranial)*

Coronal	Open
Sagittal	U
Lambdoid	U

*Pubic symphysis*

Left	Right
I:1, c. 18.5	I:1, c. 18.5

*Tooth eruption, M3*

Maxilla	Mandible
Sin/dx—erupted	Sin/dx—erupted

*Tooth wear*

Maxilla	Mandible
U	17–25

*Stature: 163.75 cm (femur dx)*

*Pathology/Trauma*

Other: slightly s-shaped spine

*Antemortem* trauma: U

Likely *perimortem* trauma: X

Possible *perimortem* trauma: X

**SKELETON NO. 1390—ROW I**  
(FIGS. 46, 70, & 126)

*Taphonomy/Preservation*

The skeleton is placed in a supine position in an E–W direction (cranium to

the E), with hands in a shackle above the head. The skeleton is almost complete; more than 2/3 of the skeletal parts are present, and they are well preserved.

Quantitative preservation: 3

Qualitative preservation: 3

*Position*

Skeleton: Supine

Cranium: Supine

Limbs: Left upper limb—flexed, Left hand—U, Left lower limb—flexed, Right upper limb—flexed, Right hand—extended, palm upwards, Right lower limb—flexed

*Relation to other skeletons*

Right arm placed above the right arm of skeleton no. 1383

*Finds*

Shackles: Yes—left wrist

*Estimate of sex: Male?*

Criteria: Skull, and pelvis

*Skull*

Skull—trait	Left	L/R	Right
Angle of the frontal		Sloped	
Frontal/parietal eminences		No	
Nuchal crest		U	
Mastoid process	U		5
Zygomatic bone	3		U
Orbital outline	U		U
Supraorbital margin	3		3
Glabella		4	
Gonial angle flare	3		U
Mental eminence		3	

*Pelvis*

Pelvis—trait	Left	Right
Subpubic concavity	U	U
Ventral arc	U	U
Ischiopubic ramus	U	U
Subpubic angle	U	U
Greater sciatic notch	5	U
Preauricularis sulcus	U	U

*Estimate of age at death: Middle adult*

Criteria: Epiphyses, suture closure, tooth eruption, and tooth wear



Fig. 125. Skeleton no. 1383.



Fig. 126. Skeleton no. 1390.

*Epiphyses*

Skull (cranium + mandible)	U
Thorax (sternum + ribs)	U
Vertebral column	U
Shoulder girdle (clavicle + scapula)	U
Upper limbs	>20
Pelvis (coxae + sacrum + coccygis)	>23
Lower limbs	>17

*Suture closure (ectocranial)*

Coronal	Significant
Sagittal	Obliteration
Lambdoid	U

*Tooth eruption, M3*

Maxilla	Mandible
Sin/dx—erupted	Sin/dx—erupted

*Tooth wear*

Maxilla	Mandible
U	25–35

*Stature: 154.23 cm (femur dx)*

*Pathology/Trauma*

Dental pathology: Slight calculus on incisors in left mandible, and on left C  
Osteoarthritis: Significant osteophytosis on three lower vertebral bodies—beginning to form a block; significant osteophytosis on lumbar vertebra no. 5

*Antemortem* trauma: U

Likely *perimortem* trauma: X

Possible *perimortem* trauma: X

**SKELETON NO. 1392—ROW I  
(FIGS. 17, 23, & 127)**

*Taphonomy/Preservation*

Only legs and feet are present; placed in a supine position in an E–W direction (cranium should be to the E). Less than 1/3 of the skeleton is preserved, and

the quality of the bones is poor, but the bones present are well preserved.

Quantitative preservation: 3

Qualitative preservation: 3

*Position*

Skeleton: Supine (lower body)

Cranium: Cranium is missing

Limbs: Left upper limb—A, Left hand—A, Left lower limb—flexed, Right upper limb—A, Right hand—A, Right lower limb—flexed

*Relation to other skeletons*

Skeleton in skeleton no. 1336 is placed where the upper body of this skeleton should be

*Finds*

Shackles: No/not observable

*Estimate of sex: Undetermined*

Criteria: Measurement



Fig. 127. Skeleton no. 1392.

*Measurement*

47 cm (femur sin, maximum head)

*Estimate of age at death: Young adult*

Criteria: Epiphyses

*Epiphyses*

Skull (cranium + mandible)	U
Thorax (sternum + ribs)	U
Vertebral column	U
Shoulder girdle (clavicle + scapula)	U
Upper limbs	U
Pelvis (coxae + sacrum + coccygis)	U
Lower limbs	c. 20?

*Pathology/Trauma*

*Antemortem* trauma: U

Likely *perimortem* trauma: U

Possible *perimortem* trauma: X

**SKELETON NO. 1393—ROW 1  
(FIGS. 14 & 17)**

*Taphonomy/Preservation*

Only lumbar vertebrae, legs, and feet are present; placed in a supine position in an E–W direction (cranium should be to the E). The left foot is displaced between the lower legs. Less than 1/3 of the skeleton is preserved, and the quality of the bones is good and the bones present are well preserved.

Quantitative preservation: 3

Qualitative preservation: 3

*Position*

Skeleton: Supine

Cranium: Cranium is missing

Limbs: Left upper limb—A, Left hand—A, Left lower limb—flexed, Right upper limb—A, Right hand—A, Right lower limb—flexed

*Relation to other skeletons*

Right femur is placed on top of the left leg of skeleton no. 1392; left tibia on the right leg of skeleton no. 1373

*Finds*

Shackles: No/not observable

*Estimate of sex: Male*

Criteria: Pelvis, and measurement

*Pelvis*

Pelvis—trait	Left	Right
Subpubic concavity	U	3
Ventral arc	U	3
Ischiopubic ramus	U	3
Subpubic angle	3	U
Greater sciatic notch	4	U
Preauricularis sulcus	U	U

*Measurement*

48 cm (femur dx, maximum head)

*Estimate of age at death: Young adult*

Criteria: Epiphyses, and pubic symphysis

*Epiphyses*

Skull (cranium + mandible)	U
Thorax (sternum + ribs)	U
Vertebral column	U
Shoulder girdle (clavicle + scapula)	U
Upper limbs	U
Pelvis (coxae + sacrum + coccygis)	<27
Lower limbs	>20

*Pubic symphysis*

Left	Right
U	III:1, c. 28.7

*Stature: 168.51 cm (femur sin)*

*Pathology/Trauma*

Other: Healed periostitis on left tibia (proximal–middle diaphysis, medial border)

*Antemortem* trauma: U

Likely *perimortem* trauma: U

Possible *perimortem* trauma: U

**Skeletons—Row 2  
(Fig. 128)**

**SKELETON NO. 1228—ROW 2  
(FIGS. 19 & 129)**

*Taphonomy/Preservation*

The skeleton is placed on its right side in a NW–SE (with cranium to the NW) direction. Hands are placed in front of the body, in the pelvis area. The right leg is much flexed; placed above the legs of skeleton no. 1386 and skeleton no. 1369. The skull is crushed (post excavation damage). The skeleton is almost complete; more than 2/3 of the skeletal parts are present. The quality of the bones is intermediate, and around 1/3–2/3 of the bones have a pronounced degree of erosion of surfaces and fragmentation.

Quantitative preservation: 3

Qualitative preservation: 2

*Position*

Skeleton: Lateral—on right side

Cranium: Lateral—on right side

Limbs: Left upper limb—flexed, Left hand—flexed, Left lower limb—extended, Right upper limb—slightly flexed, Right hand—flexed, Right lower limb—flexed

*Relation to other skeletons*

Right leg above the legs of skeleton no. 1386 and skeleton no. 1369

*Finds*

Ring on left 4th finger (MC IV -PH I)

Shackles: No

*Estimate of sex: Male?*

Criteria: Skull, and pelvis

*Skull*

Skull—trait	Left	L/R	Right
Angle of the frontal		U	
Frontal/parietal eminences		U	
Nuchal crest		4	
Mastoid process	U		3
Zygomatic bone	U		1
Orbital outline	U		U
Supraorbital margin	U		U
Glabella		4	
Gonial angle flare	U		U
Mental eminence		U	

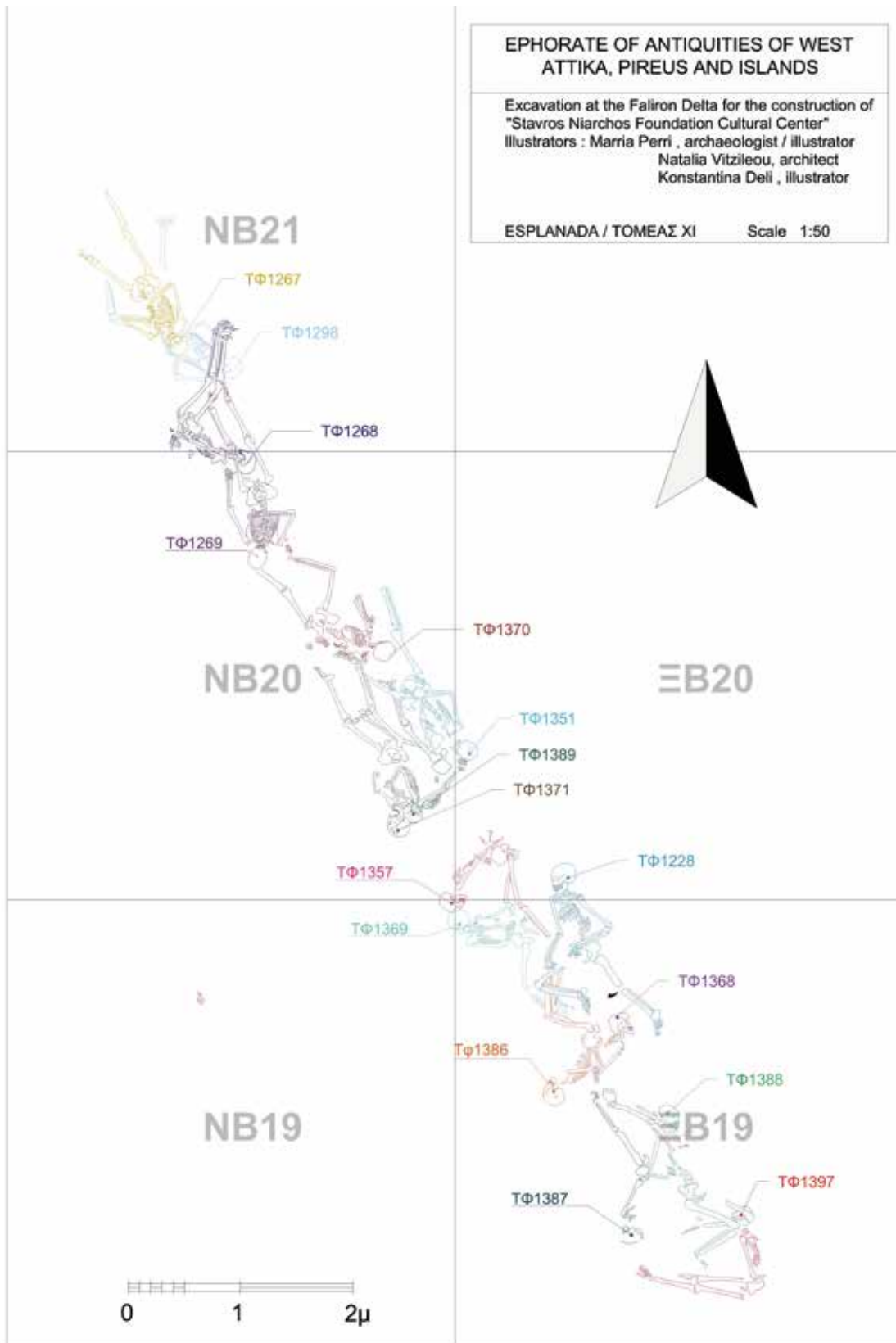


Fig. 128. Skeletons, Row 2.



Fig. 129. Skeleton no. 1228.

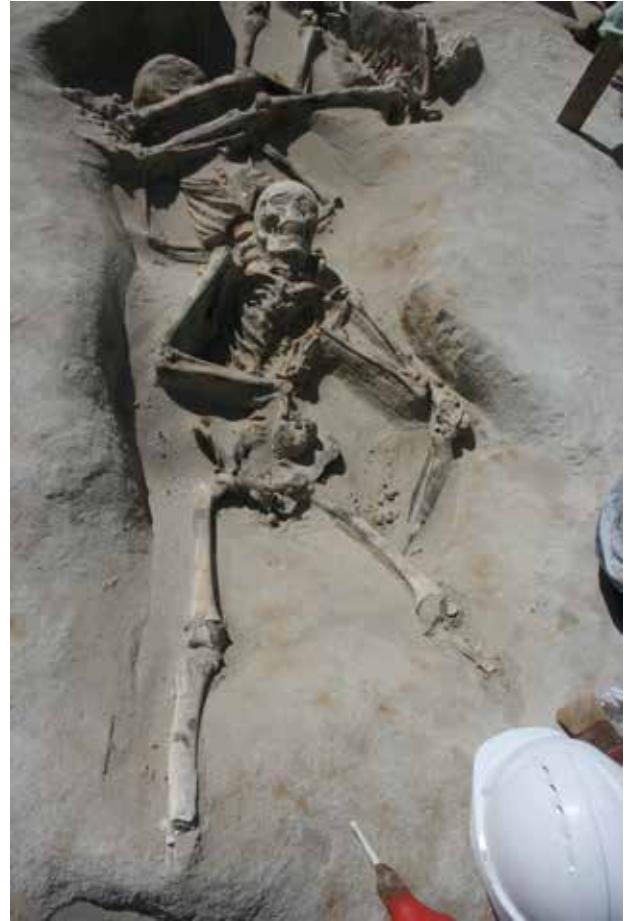

Fig. 130. Skeleton no. 1267.

*Pelvis*

Pelvis—trait	Left	Right
Subpubic concavity	U	U
Ventral arc	U	U
Ischiopubic ramus	U	U
Subpubic angle	U	U
Greater sciatic notch	5	U
Preauricularis sulcus	U	U

*Estimate of age at death: Middle adult*

Criteria: Epiphyses, suture closure, tooth eruption, and tooth wear

*Epiphyses*

Skull (cranium + mandible)	U
Thorax (sternum + ribs)	U
Vertebral column	U
Shoulder girdle (clavicle + scapula)	>29
Upper limbs	>20
Pelvis (coxae + sacrum + coccygis)	U
Lower limbs	>20

*Suture closure (ectocranial)*

Coronal	Significant
Sagittal	Minimal—significant
Lambdoid	Open—minimal

*Tooth eruption, M3*

Maxilla	Mandible
Sin—erupted	Sin—U
Dx—U	Dx—erupted

*Tooth wear*

Maxilla	Mandible
U	35–45

*Stature: 175.17 cm (humerus dx)*

*Pathology/Trauma*

*Antemortem* trauma: U

Likely *perimortem* trauma: U

Possible *perimortem* trauma: U

**SKELETON NO. 1267—ROW 2 (FIGS. 18, 71–72, & 130)**

*Taphonomy/Preservation*

The skeleton is placed in a supine position in a NW–SE direction (cranium to the SE), with arms and hands folded over the torso. Knee caps and feet are missing. The skeleton is almost complete; more than 2/3 of the skeletal parts are present, and they are well preserved.

Quantitative preservation: 3

Qualitative preservation: 3

*Position*

Skeleton: Supine

Cranium: Supine

Limbs: Left upper limb—flexed, Left hand—flexed, Left lower limb—extended, Right upper limb—flexed, Right

hand—flexed, Right lower limb—extended

#### Relation to other skeletons

The skeleton is placed on top of skeleton no. 1298, the skull resting on the pelvis of skeleton no. 1298

#### Finds

Finger ring on left hand (PH I, MC IV)

Shackles: Traces of metal under in the wrists

#### Estimate of sex: Male?

Criteria: Skull, pelvis, and measurement

#### Skull

Skull—trait	Left	L/R	Right
Angle of the frontal		Straight	
Frontal/parietal eminences		No	
Nuchal crest		U	
Mastoid process	5		5
Zygomatic bone	2		U
Orbital outline	3		U
Supraorbital margin	3		3
Glabella		2	
Gonial angle flare	2		U
Mental eminence		5	

#### Pelvis

Pelvis—trait	Left	Right
Subpubic concavity	3	U
Ventral arc	U	U
Ischiopubic ramus	U	U
Subpubic angle	U	U
Greater sciatic notch	3	U
Preauricularis sulcus	U	U

#### Measurement

70 cm (humerus sin, epicondylar breadth)

#### Estimate of age at death: Young adult

Criteria: Epiphyses, suture closure, tooth eruption, and tooth wear

#### Epiphyses

Skull (cranium + mandible)	U
Thorax (sternum + ribs)	U
Vertebral column	U
Shoulder girdle (clavicle + scapula)	24–29
Upper limbs	>20
Pelvis (coxae + sacrum + coccygis)	>23
Lower limbs	>19

#### Suture closure (ectocranial)

Coronal	Minimal
Sagittal	Minimal
Lambdoid	U

#### Tooth eruption, M3

Maxilla	Mandible
Sin—U	Sin/dx—erupting
Dx—erupting	

#### Tooth wear

Maxilla	Mandible
U	17–25

Stature: 158.99 cm (femur dx)

#### Pathology/Trauma

Dental pathology: Slight blue discoloration

Antemortem trauma: U

Likely perimortem trauma: U

Possible perimortem trauma: X

### SKELTON NO. 1268—ROW 2 (FIG. 131)

#### Taphonomy/Preservation

The skeleton is placed on its right side in an E–W (upper body with cranium to the E), and N–S (lower body) direction; that is in an angle of 90 degrees. Hands are placed behind the back. The skeleton is almost complete; more than 2/3 of the skeletal parts are present, and they are well preserved.

Quantitative preservation: 3

Qualitative preservation: 3

#### Position

Skeleton: Lateral—on right side

Cranium: Lateral—on right side

Limbs: Left upper limb—flexed, Left hand—flexed, Left lower limb—slightly flexed, Right upper limb—U, Right hand—flexed, Right lower limb—slightly flexed.

#### Relation to other skeletons

Head on the left femur of skeleton no. 1269; legs on the mandible and neck of skeleton no. 1298

#### Finds

Shackles: No

#### Estimate of sex: Male?

Criteria: Skull, and pelvis

#### Skull

Skull—trait	Left	L/R	Right
Angle of the frontal		Sloped	
Frontal/parietal eminences		No	
Nuchal crest		5	
Mastoid process	2		U
Zygomatic bone	U		U
Orbital outline	U		U
Supraorbital margin	U		U
Glabella		3	
Gonial angle flare	3		U
Mental eminence		4	

#### Pelvis

Pelvis—trait	Left	Right
Subpubic concavity	U	U
Ventral arc	U	U
Ischiopubic ramus	U	U
Subpubic angle	U	U
Greater sciatic notch	4	U
Preauricularis sulcus	U	U

#### Estimate of age at death: Young adult

Criteria: Epiphyses and suture closure

#### Epiphyses

Skull (cranium + mandible)	U
Thorax (sternum + ribs)	>20
Vertebral column	U
Shoulder girdle (clavicle + scapula)	16–21 (flake missing)
Upper limbs	>20
Pelvis (coxae + sacrum + coccygis)	>20
Lower limbs	>19

#### Suture closure (ectocranial)

Coronal	Open—minimal
Sagittal	Minimal
Lambdoid	Minimal

Stature: 161.37 cm (femur sin)

#### Pathology/Trauma

Dental pathology: Slight blue discoloration

Antemortem trauma: U

Likely perimortem trauma: U

Possible perimortem trauma: X

### SKELTON NO. 1269—ROW 2 (FIGS. 30–31, 36, & 132)

#### Taphonomy/Preservation

The skeleton is placed in a prone position in an almost N–S direction (cranium to



Fig. 131. Skeleton no. 1268.



Fig. 132. Skeleton no. 1269.

the S), with arms behind the back. The skeleton is almost complete; more than 2/3 of the skeletal parts are present, and they are well preserved.

Quantitative preservation: 3

Qualitative preservation: 3

*Position*

Skeleton: Supine

Cranium: Supine

Limbs: Left upper limb—extended, Left hand—extended, Left lower limb—extended, Right upper limb—flexed, Right hand—extended, Right lower limb—extended

*Relation to other skeletons*

Head of skeleton no. 1268 on the left femur

*Finds*

Shackles: No

*Estimate of sex: Male*

Criteria: Skull, pelvis, and measurement

*Skull*

Skull—trait	Left	L/R	Right
Angle of the frontal		Ambiguous	
Frontal/parietal eminences		Slight	
Nuchal crest		U	
Mastoid process	U		3
Zygomatic bone	2		2
Orbital outline	3		3
Supraorbital margin	3		3
Glabella		4	
Gonial angle flare	3		3
Mental eminence		5	

*Pelvis*

Pelvis—trait	Left	Right
Subpubic concavity	U	3
Ventral arc	U	3
Ischiopubic ramus	U	3
Subpubic angle	U	3
Greater sciatic notch	5	5
Preauricularis sulcus	N	N

*Measurement*

67 cm (humerus sin, epicondylar breadth)

*Estimate of age at death: Young adult*

Criteria: Epiphyses, suture closure, pubic symphysis, and tooth eruption

*Epiphyses*

Skull (cranium + mandible)	U
Thorax (sternum + ribs)	<20
Vertebral column	U
Shoulder girdle (clavicle + scapula)	<21
Upper limbs	>20
Pelvis (coxae + sacrum + coccygis)	<27
Lower limbs	c. 20

*Suture closure (ectocranial)*

Coronal	Minimal—significant
Sagittal	Minimal—significant
Lambdoid	Minimal

*Pubic symphysis*

Left	Right
III:1, (28.7)	III:1, (28.7)

*Tooth eruption, M3*

Maxilla	Mandible
Sin/dx—erupted	Sin/dx—erupted

Stature: 163.75 cm (*femur sin*)

*Pathology/Trauma*

*Antemortem* trauma: U

Likely *perimortem* trauma: X

Possible *perimortem* trauma: X

### SKELETON NO. 1298—ROW 2 (FIG. 133)

*Taphonomy/Preservation*

The skeleton is placed in a supine position in a NW–SE direction (cranium to the SE), with arms and hands folded over the torso. The skeleton is almost complete; more than 2/3 of the skeletal parts are present, and they are well preserved.

Quantitative preservation: 3

Qualitative preservation: 3

*Position*

Skeleton: Supine

Cranium: Supine—cranium resting on left side

Limbs: Left upper limb—flexed, Left hand—U, Left lower limb—slightly flexed, Right upper limb—flexed, Right hand—U, Right lower limb—U

*Relation to other skeletons*

Lumbar vertebrae and pelvis below skeleton no. 1267; skull and neck under the lower legs of skeleton no. 1268

*Finds*

Shackles: No

*Estimate of sex: Male?*

Criteria: Skull

*Skull*

Skull—trait	Left	L/R	Right
Angle of the frontal		Sloped	
Frontal/parietal eminences		No	
Nuchal crest		4	
Mastoid process	4		U
Zygomatic bone	U		2
Orbital outline	U		U
Supraorbital margin	U		3
Glabella		3	
Gonial angle flare	U		U
Mental eminence		U	

*Estimate of age at death: Adult*

Criteria: Epiphyses, and suture closure

*Epiphyses*

Skull (cranium + mandible)	U
Thorax (sternum + ribs)	U
Vertebral column	U
Shoulder girdle (clavicle + scapula)	>29
Upper limbs	>17
Pelvis (coxae + sacrum + coccygis)	>20
Lower limbs	>20

*Suture closure (ectocranial)*

Coronal	Significant—obliteration
Sagittal	Significant
Lambdoid	Minimal—significant

Stature: 162.85 cm (*humerus sin*)

*Pathology/Trauma*

Dental pathology: Slight blue discoloration

*Antemortem* trauma: U

Likely *perimortem* trauma: U

Possible *perimortem* trauma: X

### SKELETON NO. 1351—ROW 2 (FIG. 134)

*Taphonomy/Preservation*

The skeleton is placed in a prone and outstretched position in a NW–SE direction (cranium to the SE), hands crossed behind the back (probably tied).

The skeleton is almost complete; more than 2/3 of the skeletal parts are present, and they are well preserved.

Quantitative preservation: 3

Qualitative preservation: 3

*Position*

Skeleton: Prone

Cranium: Prone—cranium slightly on the left

Limbs: Left upper limb—flexed, Left hand—flexed, Left lower limb—extended, Right upper limb—flexed, Right hand—flexed, Right lower limb—extended

*Relation to other skeletons*

Right femur (distal) is below the right lower leg and foot of skeleton no. 1371; the left hand of skeleton no. 1389 against the right parietal of this skeleton

*Finds*

Shackles: No

*Estimate of sex: Male*

Criteria: Skull, and pelvis

*Skull*

Skull—trait	Left	L/R	Right
Angle of the frontal		U	
Frontal/parietal eminences		No	
Nuchal crest		5	
Mastoid process	U		U
Zygomatic bone	U		U
Orbital outline	U		U
Supraorbital margin	U		U
Glabella		U	
Gonial angle flare	2		U
Mental eminence		U	

*Pelvis*

Pelvis—trait	Left	Right
Subpubic concavity	U	U
Ventral arc	U	U
Ischiopubic ramus	3	U
Subpubic angle	U	U
Greater sciatic notch	U	U
Preauricularis sulcus	U	U

*Estimate of age at death: Adult*

Criteria: Epiphyses, and suture closure

*Epiphyses*

Skull (cranium + mandible)	U
Thorax (sternum + ribs)	U
Vertebral column	U
Shoulder girdle (clavicle + scapula)	>20
Upper limbs	>20
Pelvis (coxae + sacrum + coccygis)	>23
Lower limbs	>20



Fig. 133. Skeleton no. 1298.



Fig. 134. Skeleton no. 1351.

*Suture closure (ectocranial)*

Coronal	Minimal
Sagittal	Minimal
Lambdoid	Minimal

*Stature: 166.13 cm (femur sin)*

*Pathology/Trauma*

*Antemortem* trauma: U

Likely *perimortem* trauma: U

Possible *perimortem* trauma: U

*Nonmetric skeletal traits*

Small os inca in lambdoid suture

**SKELETON NO. 1357—ROW 2  
(FIGS. 75 & 135)**

*Taponomy/Preservation*

The skeleton is placed on its right side in an SW–NE (upper body with cranium to the SW), and N–S (lower body) direction; almost at an angle of 45 degrees.

Hands are crossed behind the back. The skeleton is incomplete, and the skull is damaged. The quality of the bones is intermediate, and around 1/3–2/3 of the bones have a pronounced degree of erosion of surfaces and fragmentation.

Quantitative preservation: 3

Qualitative preservation: 2

*Position*

Skeleton: Lateral—on right side

Cranium: Lateral—on right side

Limbs: Left upper limb—flexed, Left hand—flexed, Left lower limb—flexed,

Right upper limb—U, Right hand—flexed, Right lower limb—flexed

Relation to other skeletons

The skeleton is lying directly N of skeleton no. 1369, and with the right arm-elbow of skeleton no. 1369 above the right femur of no. 1357.

*Finds*

Shackles: No

*Estimate of sex: Male?*

Criteria: Skull, and pelvis

*Skull*

Skull—trait	Left	L/R	Right
Angle of the frontal		U	
Frontal/parietal eminences		U	
Nuchal crest		3	
Mastoid process	4		U
Zygomatic bone	3		U
Orbital outline	1		U
Supraorbital margin	3		U
Glabella		U	
Gonial angle flare	3		U
Mental eminence		2	



Fig. 135. Skeleton no. 1357.



Fig. 136. Skeleton no. 1368.

*Pelvis*

Pelvis—trait	Left	Right
Subpubic concavity	U	U
Ventral arc	U	U
Ischiopubic ramus	U	U
Subpubic angle	4	U
Greater sciatic notch	4	U
Preauricularis sulcus	U	U

*Estimate of age at death: Young adult*

Criteria: Epiphyses, suture closure, tooth eruption, and tooth wear

*Epiphyses*

Skull (cranium + mandible)	U
Thorax (sternum + ribs)	U
Vertebral column	U
Shoulder girdle (clavicle + scapula)	U
Upper limbs	>20
Pelvis (coxae + sacrum + coccygis)	>23
Lower limbs	>19

*Suture closure (ectocranial)*

Coronal	Minimal
Sagittal	Minimal
Lambdoid	Minimal

*Tooth eruption, M3*

Maxilla	Mandible
Sin—erupted	Sin—erupted
Dx—U	Dx—U

*Tooth wear*

Maxilla	Mandible
17–25	U

*Stature: 178.03 cm (femur sin)*

*Pathology/Trauma*

Dental pathology: Medium calculus on left and right I1–I2, maxilla; slight calculus on left C maxilla.

*Antemortem* trauma: U

Likely *perimortem* trauma: U

Possible *perimortem* trauma: X

**SKELETON NO. 1368—ROW 2 (FIG. 136)**

*Taphonomy/Preservation*

The skeleton is placed on its left side in a NE–SW (upper body, with cranium to the NE) and an NW–SE direction (lower body). Hands are placed behind the back (probably tied). The skeleton is almost complete; more than 2/3 of the skeletal parts are present, and they are well preserved.

Quantitative preservation: 3

Qualitative preservation: 3

*Position*

Skeleton: Lateral—on left side

Cranium: Lateral—on left side

Limbs: Left upper limb—U, Left hand—flexed, Left lower limb—extended, slightly flexed, Right upper limb—

flexed, Right hand—U, Right lower limb—extended, slightly flexed

*Relation to other skeletons*

Right hand of skeleton no. 1386 placed on this skeleton

*Finds*

Shackles: No

*Estimate of sex: Male?*

Criteria: Skull, and pelvis

*Skull*

Skull—trait	Left	L/R	Right
Angle of the frontal		Sloped	
Frontal/parietal eminences		No	
Nuchal crest		4	
Mastoid process	U		4
Zygomatic bone	U		U
Orbital outline	U		3
Supraorbital margin	U		4
Glabella		3	
Gonial angle flare	U		1
Mental eminence		3	

*Pelvis*

Pelvis—trait	Left	Right
Subpubic concavity	U	U
Ventral arc	U	U
Ischiopubic ramus	U	U
Subpubic angle	U	U
Greater sciatic notch	U	5
Preauricularis sulcus	U	U

*Estimate of age at death: Middle adult*

Criteria: Epiphyses, suture closure, tooth eruption, and tooth wear

*Epiphyses*

Skull (cranium + mandible)	U
Thorax (sternum + ribs)	U
Vertebral column	U
Shoulder girdle (clavicle + scapula)	U
Upper limbs	>20
Pelvis (coxae + sacrum + coccygis)	>20
Lower limbs	>18

*Suture closure (ectocranial)*

Coronal	Significant
Sagittal	Significant—obliteration
Lambdoid	Significant—complete

*Tooth eruption, M3*

Maxilla	Mandible
Sin—U	Sin—U
Dx—erupted	Dx—erupted

*Tooth wear*

Maxilla	Mandible
17–25	U

*Stature: 162.85 cm (humerus dx)*

*Pathology/Trauma*

Dental pathology: Slight calculus on all mandibular teeth; right maxilla: slight calculus on I1, I2; slight linear enamel hypoplasia on I1, left and right in maxilla; blue discolouration on right I2, maxilla and slight on I1, I2, C mandible

*Antemortem* trauma: X

Likely *perimortem* trauma: U

Possible *perimortem* trauma: U

**SKELETON NO. 1369—ROW 2**

(FIGS. 74 & 137)

*Taphonomy/Preservation*

The skeleton is placed in a prone position in a W–E direction (cranium to the W), and a N–S (lower body) direction. Hands are placed behind the back with the right hand on top (sticking up). The skeleton is almost complete. The quality of the bones is intermediate, and around 1/3–2/3 of the bones have a pronounced degree of erosion of surfaces and fragmentation.

Quantitative preservation: 3

Qualitative preservation: 2

*Position*

Skeleton: Prone

Cranium: Prone—cranium slightly on the right

Limbs: Left upper limb—flexed, Left hand—U, Left lower limb—flexed, Right upper limb—flexed, Right hand—U, Right lower limb—flexed

*Relation to other skeletons*

Lower legs below the right lower leg of skeleton no. 1228 and the lower legs of skeleton no. 1386

*Finds*

Shackles: No

*Estimate of sex: Male*

Criteria: Skull, pelvis, and measurement.

*Skull*

Skull—trait	Left	L/R	Right
Angle of the frontal		Sloped	
Frontal/parietal eminences		No	
Nuchal crest		4	
Mastoid process	5		U
Zygomatic bone	2		2
Orbital outline	U		U
Supraorbital margin	4		U
Glabella		4	
Gonial angle flare	1		U
Mental eminence		U	

*Pelvis*

Pelvis—trait	Left	Right
Subpubic concavity	U	U
Ventral arc	U	U
Ischiopubic ramus	U	U
Subpubic angle	U	U
Greater sciatic notch	5	U
Preauricularis sulcus	U	U

*Measurement*

47 cm (femur sin, maximum head)

*Estimate of age at death: Young adult*

Criteria: Epiphyses, suture closure, and tooth eruption

*Epiphyses*

Skull (cranium + mandible)	U
Thorax (sternum + ribs)	U
Vertebral column	U
Shoulder girdle (clavicle + scapula)	>20
Upper limbs	>20
Pelvis (coxae + sacrum + coccygis)	U
Lower limbs	>19

*Suture closure (ectocranial)*

Coronal	Open
Sagittal	Open
Lambdoid	Open

*Tooth eruption, M3*

Maxilla	Mandible
Sin—erupted	Sin—erupted
Dx—U	Dx—U

*Stature: 161.37 cm (femur sin)*

*Pathology/Trauma*

Dental pathology: Slight calculus on C and P1 in the left mandible

*Antemortem* trauma: U

Likely *perimortem* trauma: U

Possible *perimortem* trauma: X

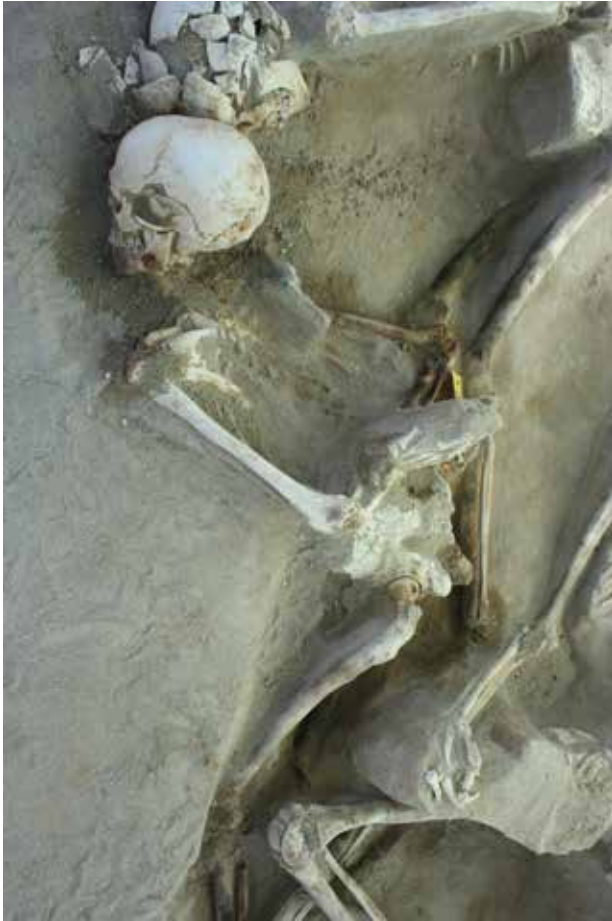

Fig. 137. Skeleton no. 1369.

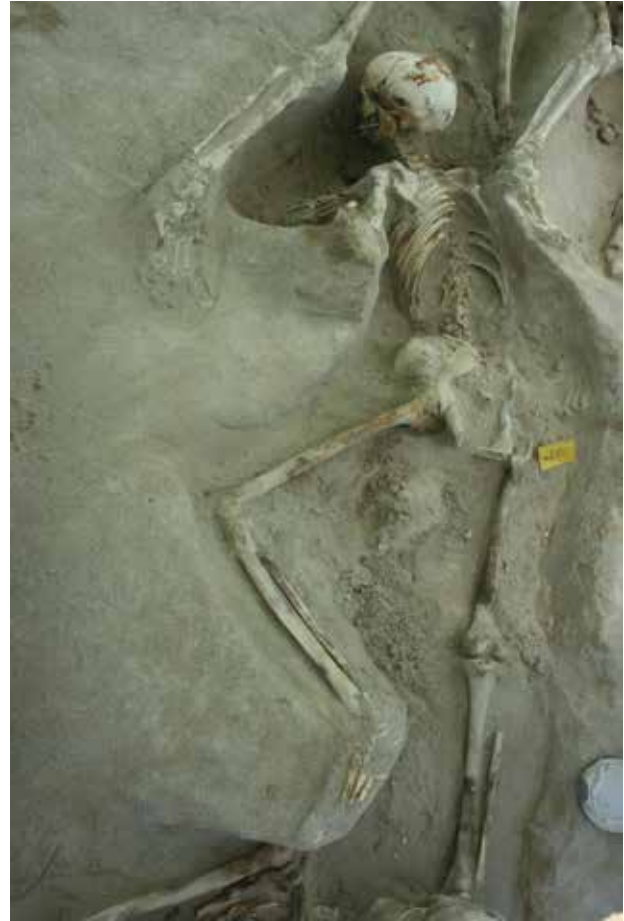

Fig. 138. Skeleton no. 1370.

**SKELETON NO. 1370—ROW 2  
(FIG. 138)**

*Taphonomy/Preservation*

The skeleton is placed in a prone position in a NW–SE direction (cranium to the SE), almost in a recovery position. The skeleton is almost complete; more than 2/3 of the skeletal parts are present, and they are well preserved.

Quantitative preservation: 3

Qualitative preservation: 3

*Position*

Skeleton: Prone

Cranium: Prone—cranium slightly on the right side

Limbs: Left upper limb—flexed, Left hand—flexed, Left lower limb—flexed, Right upper limb—U, Right hand—extended, Right lower limb—U

*Relation to other skeletons*

Lower legs/feet below skull of skeleton no. 1269

*Finds*

Shackles: No

*Estimate of sex: Male?*

Criteria: Skull, pelvis, and measurement

*Skull*

Skull—trait	Left	L/R	Right
Angle of the frontal		Straight	
Frontal/parietal eminences		No	
Nuchal crest		5	
Mastoid process	2		U
Zygomatic bone	2		U
Orbital outline	U		U
Supraorbital margin	4		U
Glabella		3	
Gonial angle flare	U		U
Mental eminence		U	

*Pelvis*

Pelvis—trait	Left	Right
Subpubic concavity	U	U
Ventral arc	U	U
Ischiopubic ramus	U	U
Subpubic angle	U	U
Greater sciatic notch	5	U
Preauricular sulcus	U	U

*Measurement*

78 cm (femur dx, epicondylar breadth)

*Estimate of age at death: Adult*

Criteria: Epiphyses, and suture closure

*Epiphyses*

Skull (cranium + mandible)	U
Thorax (sternum + ribs)	U
Vertebral column	U
Shoulder girdle (clavicle + scapula)	>20
Upper limbs	>20
Pelvis (coxae + sacrum + coccygis)	>23
Lower limbs	>20

*Suture closure (ectocranial)*

Coronal	Open—minimal
Sagittal	Open—minimal
Lambdoid	Open—minimal

*Stature: 156.61 cm (femur dx)*

*Pathology/Trauma*

Dental pathology: Slight calculus on sin C, P1 and P2, mandible

*Antemortem* trauma: U

Likely *perimortem* trauma: U

Possible *perimortem* trauma: U

**SKELETON NO. 1371—ROW 2 (FIG. 139)**

*Taphonomy/Preservation*

The skeleton is placed in a supine position (slightly on the left side) in a NW–SE direction (cranium to the SE), with arms and hands folded over the torso (possibly tied). Left lower arm and hand is sticking up. The skeleton is almost complete; more than 2/3 of the skeletal parts are present, and they are well preserved.

Quantitative preservation: 3

Qualitative preservation: 3

*Position*

Skeleton: Supine—slightly on left side

Cranium: Supine—slightly on left side

Limbs: Left upper limb—flexed, Left hand—flexed, Left lower limb—extended, Right upper limb—flexed, Right hand—flexed, Right lower limb—extended

*Relation to other skeletons*

Right leg above the left leg of skeleton no. 1389

*Finds*

Shackles: No

*Estimate of sex: Male?*

Criteria: Skull, and pelvis

*Skull*

Skull—trait	Left	L/R	Right
Angle of the frontal		Sloped	
Frontal/parietal eminences		Slight	
Nuchal crest		3	
Mastoid process	U		3
Zygomatic bone	U		2
Orbital outline	1		1
Supraorbital margin	3		U
Glabella		4	
Gonial angle flare	1		U
Mental eminence		4	

*Pelvis*

Pelvis—trait	Left	Right
Subpubic concavity	U	U
Ventral arc	U	U
Ischiopubic ramus	U	U
Subpubic angle	3	3
Greater sciatic notch	U	4
Preauricularis sulcus	U	U

*Estimate of age at death: Young adult*

Criteria: Epiphyses, suture closure, tooth eruption, and tooth wear

*Epiphyses*

Skull (cranium + mandible)	U
Thorax (sternum + ribs)	U
Vertebral column	U
Shoulder girdle (clavicle + scapula)	>29
Upper limbs	>20
Pelvis (coxae + sacrum + coccygis)	>23
Lower limbs	>19

*Suture closure (ectocranial)*

Coronal	Minimal
Sagittal	Minimal—significant
Lambdoid	Minimal

*Tooth eruption, M3*

Maxilla	Mandible
Sin—U	Sin—U
Dx—erupted	Dx—erupted

*Tooth wear*

Maxilla	Mandible
U	25–35

*Stature: 161.37 cm (femur dx)*

*Pathology/Trauma*

Dental pathology: Slight calculus on I2 and C in the right mandible

*Antemortem* trauma: U

Likely *perimortem* trauma: U

Possible *perimortem* trauma: U

**SKELETON NO. 1386—ROW 2 (FIGS. 48 & 140)**

*Taphonomy/Preservation*

The skeleton is placed on its left side in a 90 degrees angle in a SW–NE (upper body, with cranium to the SW), and a NW–SE direction (lower body). Hands are placed behind the back (as if tied). The skeleton is almost complete; more than 2/3 of the skeletal parts are present, and they are well preserved.

Quantitative preservation: 3

Qualitative preservation: 3

*Position*

Skeleton: Lateral—on left side

Cranium: Lateral—on left side

Limbs: Left upper limb—U, Left hand—extended, Left lower limb—flexed, Right upper limb—flexed, Right hand—U, Right lower limb—flexed

*Relation to other skeletons*

Lower legs and feet below the right lower leg of skeleton no. 1228, but above the lower legs of skeleton no. 1369; the right hand is resting on skeleton no. 1368

*Finds*

Shackles: No, but demarcated staining on right parietal, possibly from iron?

*Estimate of sex: Male?*

Criteria: Skull, and pelvis

*Skull*

Skull—trait	Left	L/R	Right
Angle of the frontal		Sloped	
Frontal/parietal eminences		No	
Nuchal crest		3	
Mastoid process	U		5
Zygomatic bone	2		2
Orbital outline	3		3
Supraorbital margin	5		U
Glabella		4	
Gonial angle flare	U		2
Mental eminence		3	



Fig. 139. Skeleton no. 1371.



Fig. 140. Skeleton no. 1386.

*Pelvis*

Pelvis—trait	Left	Right
Subpubic concavity	U	U
Ventral arc	U	U
Ischiopubic ramus	U	U
Subpubic angle	U	U
Greater sciatic notch	S	U
Preauricularis sulcus	U	U

*Estimate of age at death: Young adult*

Criteria: Epiphyses, suture closure, and tooth eruption

*Epiphyses*

Skull (cranium + mandible)	U
Thorax (sternum + ribs)	U
Vertebral column	U
Shoulder girdle (clavicle + scapula)	24–29
Upper limbs	>20
Pelvis (coxae + sacrum + coccygis)	U
Lower limbs	>19

*Suture closure (ectocranial)*

Coronal	Open
Sagittal	Minimal–significant
Lambdoid	Open–minimal

*Tooth eruption, M3*

Maxilla	Mandible
Sin—U	Sin—erupted
Dx—erupted	Dx—U

*Stature: 163.75 cm (femur sin)*

*Pathology/Trauma*

Dental pathology: Left I1 and right I1, I2, maxilla, right C maxilla: LEH, 2 lines; blue discolouration on left and right I1, and right I2.

*Antemortem* trauma: U

Likely *perimortem* trauma: X

Possible *perimortem* trauma: X

**SKELETON NO. 1387—ROW 2 (FIGS. 76 & 141)**

*Taphonomy/Preservation*

The skeleton is placed on its left side in a N–S (with cranium to the S) direction. Hands are placed behind the back. The skull is crushed, probably damaged by excavation. The skeleton is almost complete; more than 2/3 of the skeletal parts are present, and they are well preserved.

Quantitative preservation: 3

Qualitative preservation: 3

*Position*

Skeleton: Lateral—on left side

Cranium: Lateral—on left side

Limbs: Left upper limb—U, Left hand—U, Left lower limb—U, Right upper limb—flexed, Right hand—U, Right lower limb—extended



Fig. 141. Skeleton no. 1387.



Fig. 142. Skeleton no. 1388.

*Relation to other skeletons*

Right elbow of 1388 close to/partly on, the right coxae.

*Finds*

Shackles: No

*Estimate of sex: Male?*

Criteria: Skull, and pelvis

*Skull*

Skull—trait	Left	L/R	Right
Angle of the frontal		U	
Frontal/parietal eminences		U	
Nuchal crest		3	
Mastoid process	U		3
Zygomatic bone	U		U
Orbital outline	U		U
Supraorbital margin	U		U
Glabella		U	
Gonial angle flare	U		3
Mental eminence		U	

*Pelvis*

Pelvis—trait	Left	Right
Subpubic concavity	U	U
Ventral arc	U	U
Ischiopubic ramus	U	U
Subpubic angle	U	U
Greater sciatic notch	U	4
Preauricularis sulcus	U	U

*Estimate of age at death: Adult*

Criteria: Epiphyses, and tooth eruption

*Epiphyses*

Skull (cranium + mandible)	U
Thorax (sternum + ribs)	U
Vertebral column	U
Shoulder girdle (clavicle + scapula)	>20
Upper limbs	>17
Pelvis (coxae + sacrum + coccygis)	U
Lower limbs	>20

*Tooth eruption, M3*

Maxilla	Mandible
Sin/dx—U	Sin/dx—erupted

*Stature: 161.37 cm (femur dx)*

*Pathology/Trauma*

*Antemortem* trauma: U

Likely *perimortem* trauma: U

Possible *perimortem* trauma: X

**SKELETON NO. 1388—ROW 2 (FIGS. 77–78 & 142)**

*Taphonomy/Preservation*

The skeleton is placed on its left side in a N–S (with cranium to the N) direction. Hands are placed behind the back; legs are bent. The skeleton is almost complete; more than 2/3 of the skeletal parts are present, and they are well preserved.

Quantitative preservation: 3

Qualitative preservation: 3

#### Position

Skeleton: Lateral—on left side

Cranium: Lateral—on left side

Limbs: Left upper limb—U, Left hand—U, Left lower limb—flexed, Right upper limb—flexed, Right hand—U, Right lower limb—flexed

#### Relation to other skeletons

The neck is resting under the legs of skeleton no. 1368; the knees on the head of skeleton no. 1397

#### Finds

Shackles: No

Estimate of sex: Male

Criteria: Skull, pelvis, and measurement

#### Skull

Skull—trait	Left	L/R	Right
Angle of the frontal		Sloped	
Frontal/parietal eminences		No	
Nuchal crest		U	
Mastoid process	U		4
Zygomatic bone	3		U
Orbital outline	U		U
Supraorbital margin	3		U
Glabella		4	
Gonial angle flare	U		U
Mental eminence		U	

#### Pelvis

Pelvis—trait	Left	Right
Subpubic concavity	3	U
Ventral arc	3	U
Ischiopubic ramus	3	U
Subpubic angle	U	U
Greater sciatic notch	U	U
Preauricularis sulcus	U	U

#### Measurement

55 cm (humerus dx, epicondylar breadth)

Estimate of age at death: Middle adult

Criteria: Epiphyses, suture closure, pubic symphysis, tooth eruption, and tooth wear

#### Epiphyses

Skull (cranium + mandible)	U
Thorax (sternum + ribs)	U
Vertebral column	U
Shoulder girdle (clavicle + scapula)	U
Upper limbs	>17
Pelvis (coxae + sacrum + coccygis)	>23
Lower limbs	>20

#### Suture closure (ectocranial)

Coronal	Significant
Sagittal	U
Lambdoid	U

#### Pubic symphysis

Left	Right
IV:1, 35.2	U

#### Tooth eruption, M3

Maxilla	Mandible
Sin /dx—erupted	Sin /dx—erupted

#### Tooth wear

Maxilla	Mandible
U	17–25

Stature: 166.13 cm (femur dx)

#### Pathology/Trauma

Dental pathology: Right mandible, C, PM1, PM2: slight linear enamel hypoplasia; Right maxilla M1: buccal caries, slight

Antemortem trauma: U

Likely perimortem trauma: U

Possible perimortem trauma: X

#### SKELETON NO. 1389—ROW 2 (FIGS. 34, 73, & 143)

#### Taphonomy/Preservation

The skeleton is placed on its left side in a 90 degrees angle in a SW–NE (upper body, with cranium to the SW) and an NW–SE direction (lower body). Hands are placed behind the back? The skeleton is almost complete; more than 2/3 of the skeletal parts are present, and they are well preserved.

Quantitative preservation: 3

Qualitative preservation: 3

#### Position

Skeleton: Lateral—on left side

Cranium: Lateral—on left side

Limbs: Left upper limb—U, Left hand—flexed, Left lower limb—flexed, Right upper limb—flexed, Right hand—flexed, Right lower limb—flexed

#### Relation to other skeletons

Left leg below the right leg of skeleton no. 1371

#### Finds

Shackles: No

Estimate of sex: Male?

Criteria: Skull, and pelvis

#### Skull

Skull—trait	Left	L/R	Right
Angle of the frontal		U	
Frontal/parietal eminences		U	
Nuchal crest		3	
Mastoid process	U		U
Zygomatic bone	2		U
Orbital outline	U		U
Supraorbital margin	U		U
Glabella		U	
Gonial angle flare	U		3
Mental eminence		U	

#### Pelvis

Pelvis—trait	Left	Right
Subpubic concavity	U	U
Ventral arc	U	U
Ischiopubic ramus	U	U
Subpubic angle	U	U
Greater sciatic notch	U	5
Preauricularis sulcus	U	U

Estimate of age at death: Adult

Criteria: Epiphyses, and suture closure

#### Epiphyses

Skull (cranium + mandible)	U
Thorax (sternum + ribs)	U
Vertebral column	U
Shoulder girdle (clavicle + scapula)	U
Upper limbs	>20
Pelvis (coxae + sacrum + coccygis)	>23
Lower limbs	>19

#### Suture closure (ectocranial)

Coronal	U
Sagittal	U
Lambdoid	Minimal

Stature: 158.99 cm (femur dx)



Fig. 143. Skeleton no. 1389.



Fig. 144. Skeleton no. 1397.

*Pathology/Trauma*

*Antemortem* trauma: U

Likely *perimortem* trauma: U

Possible *perimortem* trauma: X

**SKELETON NO. 1397—ROW 2  
(FIG. 144)**

*Taphonomy/Preservation*

The skeleton is placed on its right side in a N-S (upper body with cranium to the N), and E-W (lower body with feet to the W) direction; that is in an angle of 90 degrees. All phalanges of the left foot are missing. Hands are placed behind the back. Post-depositional processes significantly disturb several of the bones; left scaphoid is found on the right femur, right femur is rotated medially; right kneecap has slipped down; right radius

is not connected. The skeleton is almost complete; more than 2/3 of the skeletal parts are present, and they are well preserved.

Quantitative preservation: 3

Qualitative preservation: 3

*Position*

Skeleton: Lateral—on right side

Cranium: Lateral—on right side

Limbs: Left upper limb—flexed, Left hand—flexed, Left lower limb—extended, Right upper limb—flexed, Right hand—flexed, Right lower limb—extended

*Relation to other skeletons*

The left knee of skeleton no. 1388 is placed on skull

*Finds*

Shackles: No

*Estimate of sex: Undetermined*

Criteria: Skull, and pelvis

*Skull*

Skull—trait	Left	L/R	Right
Angle of the frontal		U	
Frontal/parietal eminences		U	
Nuchal crest		3	
Mastoid process	U		U
Zygomatic bone	U		U
Orbital outline	U		U
Supraorbital margin	U		U
Glabella		U	
Gonial angle flare	U		U
Mental eminence		U	

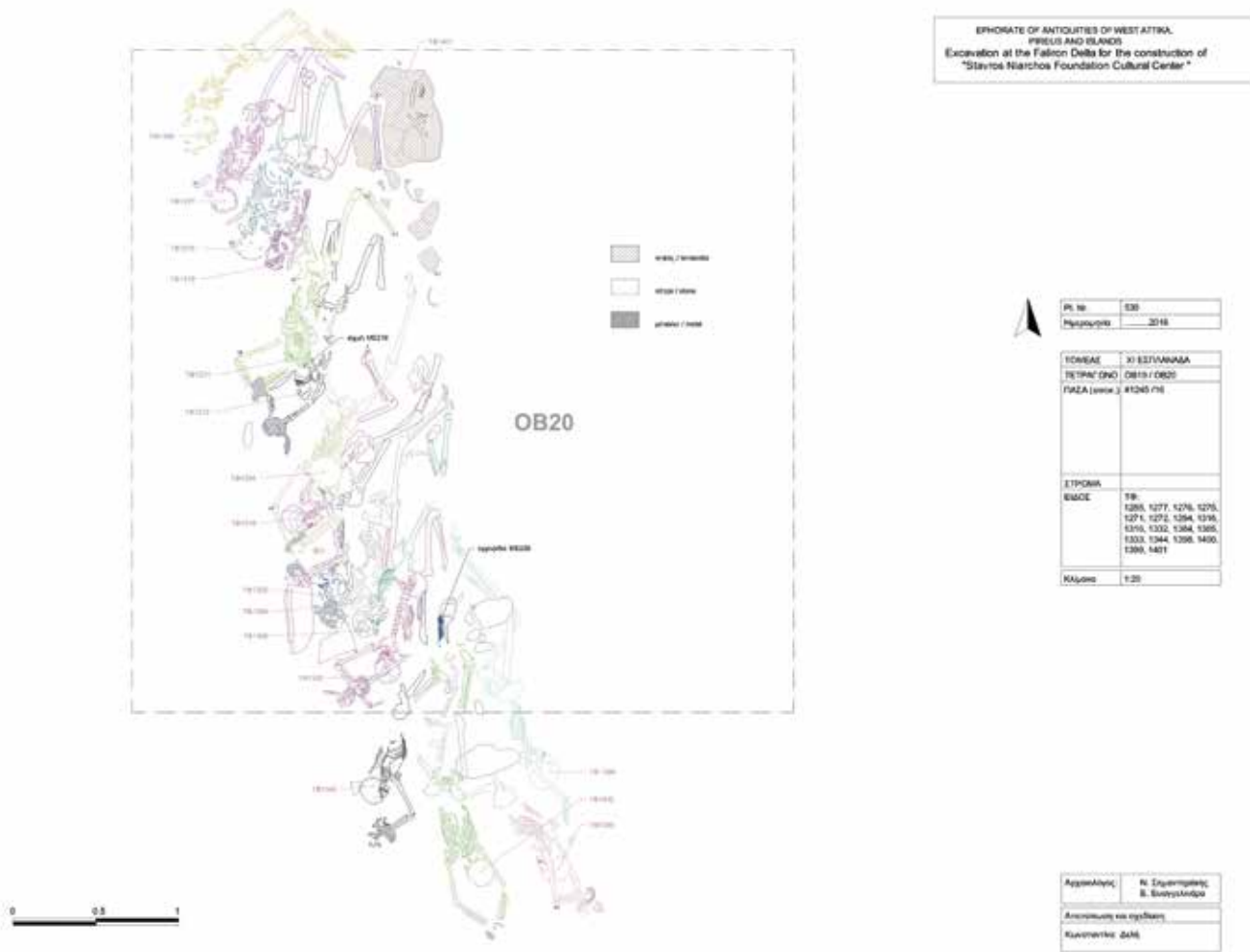


Fig. 145. Skeletons, Row 3.

*Pelvis*

Pelvis—trait	Left	Right
Subpubic concavity	U	U
Ventral arc	U	U
Ischiopubic ramus	U	U
Subpubic angle	U	U
Greater sciatic notch	4	U
Preauricularis sulcus	U	U

*Estimate of age at death: Adult*

Criteria: Epiphyses, and suture closure

*Epiphyses*

Skull (cranium + mandible)	U
Thorax (sternum + ribs)	U
Vertebral column	U
Shoulder girdle (clavicle + scapula)	U
Upper limbs	>17
Pelvis (coxae + sacrum + coccygis)	>23
Lower limbs	>20

*Suture closure (ectocranial)*

Coronal	U
Sagittal	Significant—complete
Lambdoid	Significant

*Pathology/Trauma*

*Antemortem* trauma: U

Likely *perimortem* trauma: U

Possible *perimortem* trauma: U

**Skeletons—Row 3  
(Fig. 145)**

**SKELETON NO. 1271—ROW 3  
(FIGS. 79 & 146)**

*Taphonomy/Preservation*

The skeleton is placed in a N–S direction (cranium to the S). The upper part of the body is in a supine position; the lower part is resting on its left side. Arms are slightly bent to the left above the head, with the hands in a shackle. The vertebral bodies are missing. The skeleton is almost complete; more than 2/3 of the skeletal parts are present, but the quality of the bones is



Fig. 146. Skeleton 1271.



Fig. 147. Skeleton no. 1272.

poor and more than 2/3 of the skeleton is fragmented and affected by erosion.

Quantitative preservation: 3

Qualitative preservation: 1

*Position*

Skeleton: Supine—postcranial skeleton on the left

Cranium: Supine

Limbs: Left upper limb—flexed, Left hand—U, Left lower limb—flexed?, Right upper limb—flexed, Right hand—extended, Right lower limb—flexed

*Relation to other skeletons*

The skeleton is placed below skeleton no. 1275, but above skeleton no. 1272; left tibia and fibula continue below skeleton no. 1275

*Finds*

Shackles: Yes—wrists

*Estimate of sex: Undetermined*

Criteria: Skull

*Skull*

Skull—trait	Left	L/R	Right
Angle of the frontal		Sloped	
Frontal/parietal eminences		Slight	
Nuchal crest		U	
Mastoid process	U		U
Zygomatic bone	2		U
Orbital outline	U		U
Supraorbital margin	2		U
Glabella		2	
Gonial angle flare	3		U
Mental eminence		4	

*Estimate of age at death: Adult*

Criteria: Epiphyses, and tooth eruption

*Epiphyses*

Skull (cranium + mandible)	U
Thorax (sternum + ribs)	U
Vertebral column	U
Shoulder girdle (clavicle + scapula)	U
Upper limbs	>15
Pelvis (coxae + sacrum + coccygis)	U
Lower limbs	>18

*Tooth eruption, M3*

Maxilla	Mandible
Sin—erupted	Sin—A
Dx—U	Dx—U

*Stature: 163.75 cm (femur sin)*

*Pathology/Trauma*

*Antemortem* trauma: U

Likely *perimortem* trauma: U

Possible *perimortem* trauma: X

**SKELETON NO. 1272—ROW 3**  
(FIGS. 21–22, 49, & 147)*Taphonomy/Preservation*

The skeleton is placed in a supine position in a SSW–NNE direction (cranium to the SSW). Head is resting on its left side. Arms are slightly bent to the left above the head, and hands are placed in a shackle. Both legs are extremely flexed. The skeleton is almost complete. The quality of the bones is intermediate, and around 1/3–2/3 of the bones have a pronounced degree of erosion of surfaces and fragmentation.

Quantitative preservation: 3

Qualitative preservation: 2

*Position*

Skeleton: Supine

Cranium: Lateral—on left side

Limbs: Left upper limb—flexed, Left hand—U, Left lower limb—extremely flexed, Right upper limb—flexed, Right hand—U, Right lower limb—flexed

**Relation to other skeletons**

The pelvis is above the right knee of skeleton no. 1294; the left leg is below the right leg of skeleton no. 1271

*Finds*

Arrowhead, left thorax, near to the shoulder.

Shackles: Yes—wrists

*Estimate of sex: Male?*

Criteria: Skull, and pelvis

*Skull*

Skull—trait	Left	L/R	Right
Angle of the frontal		U	
Frontal/parietal eminences		No	
Nuchal crest		U	
Mastoid process	U		U
Zygomatic bone	U		U
Orbital outline	U		U
Supraorbital margin	U		U
Glabella		U	
Gonial angle flare	U		U
Mental eminence		U	

*Pelvis*

Pelvis—trait	Left	Right
Subpubic concavity	U	U
Ventral arc	U	U
Ischiopubic ramus	U	U
Subpubic angle	U	U
Greater sciatic notch	U	4
Preauricularis sulcus	U	U

*Estimate of age at death: Juvenile*

Criteria: Suture closure, tooth eruption, and tooth wear

*Suture closure (ectocranial)*

Coronal	Open
Sagittal	minimal

*Tooth eruption, M3*

Maxilla	Mandible
Sin—U	Sin/dx—U
Dx—not erupted	

*Tooth wear*

Maxilla	Mandible
17–25	U

Stature: 163.75 cm (*femur sin*)*Pathology/Trauma*

Antemortem trauma: U

Likely *perimortem* trauma: XPossible *perimortem* trauma: U**SKELETON NO. 1275—ROW 3**  
(FIG. 148)*Taphonomy/Preservation*

The skeleton is placed in a supine position in a SSW–NNE direction (with cranium to the SSW); its upper body on a higher level. Head is slightly resting on the left side. Arms are probably placed above the head. Legs are flexed. The skeleton is almost complete; more than 2/3 of the skeletal parts are present, but the quality of the bones is poor and more than 2/3 of the skeleton is fragmented and affected by erosion.

Quantitative preservation: 3

Qualitative preservation: 1

*Position*

Skeleton: Supine

Cranium: Supine—cranium slightly on left side

Limbs: Left upper limb—U, Left hand—A, Left lower limb—flexed, Right upper

limb—extended, Right hand—A, Right lower limb—flexed

*Relation to other skeletons*

Left pelvis is placed below the pelvic girdle of skeleton no. 1276

*Finds*

Shackles: No

*Estimate of sex: Undetermined*

Criteria: Skull

*Skull*

Skull—trait	Left	L/R	Right
Angle of the frontal		U	
Frontal/parietal eminences		U	
Nuchal crest		U	
Mastoid process	U		U
Zygomatic bone	U		2
Orbital outline	U		U
Supraorbital margin	U		3
Glabella		3	
Gonial angle flare	U		3
Mental eminence		3	

*Estimate of age at death: Adult*

Criteria: Tooth eruption

*Tooth eruption, M3*

Maxilla	Mandible
Sin—U	Sin—U
Dx—erupted	Dx—erupted

Stature: 163.75 cm (*femur sin*)*Pathology/Trauma*

Antemortem trauma: U

Likely *perimortem* trauma: UPossible *perimortem* trauma: U**SKELETON NO. 1276—ROW 3**  
(FIG. 149)*Taphonomy/Preservation*

The skeleton is placed on its left side in a SSW–NNE (with cranium to the SSW) direction. The right leg is extremely flexed (left leg is more or less unobservable). The skull is crushed. Arms and hands are more or less missing, but seem to be stretched above the head. Approximately half of the skeleton is preserved, but the quality of the bones is poor and more than 2/3 of the skeleton is fragmented and affected by erosion.

Quantitative preservation: 2

Qualitative preservation: 1



Fig. 148. Skeleton no. 1275.



Fig. 149. Skeleton no. 1276.

*Position*

Skeleton: Lateral—on left side  
 Cranium: Lateral—on left side  
 Limbs: Left upper limb—U, Left hand—A, Left lower limb—flexed, Right upper limb—U, Right hand—A, Right lower limb—flexed

*Relation to other skeletons*

Partly below skeleton no. 1277, and partly above skeleton no. 1275

*Finds*

Shackles: No  
 Estimate of sex: Male?  
 Criteria: Pelvis

*Pelvis*

Pelvis—trait	Left	Right
Subpubic concavity	U	3
Ventral arc	U	3
Ischiopubic ramus	U	2
Subpubic angle	U	U
Greater sciatic notch	U	U
Preauricularis sulcus	U	U

*Estimate of age at death: Young adult*

Criteria: Epiphyses, and pubic symphysis

*Epiphyses*

Skull (cranium + mandible)	U
Thorax (sternum + ribs)	U
Vertebral column	U
Shoulder girdle (clavicle + scapula)	U
Upper limbs	>20
Pelvis (coxae + sacrum + coccygis)	>23
Lower limbs	>20

*Pubic symphysis*

Left	Right
III:1, 28.7	U

*Stature: 163.75 cm (femur sin)*

*Pathology/Trauma*

*Antemortem* trauma: U  
 Likely *perimortem* trauma: U  
 Possible *perimortem* trauma: U

**SKELETON NO. 1277—ROW 3 (FIG. 150)**

*Taphonomy/Preservation*

The skeleton is placed on its left side in a SW–NE (with cranium to the SW) direction. Legs are bent. The skull is crushed; most of the mandible is missing. Arms and hands are more or less missing, but the right arm seems to be



Fig. 150. Skeleton no. 1277.



Fig. 151. Skeleton no. 1285.

stretched above the head. Left lower legs are covered by soil. Approximately half of the skeleton is preserved, but the quality of the bones is bad and more than 2/3 of the skeleton is fragmented and affected by erosion.

Quantitative preservation: 2

Qualitative preservation: 1

*Position*

Skeleton: Lateral—on left side

Cranium: Lateral—on left side

Limbs: Left upper limb—U, Left hand—U, Left lower limb—flexed, Right upper limb—U, Right hand—U, Right lower limb—flexed

*Relation to other skeletons*

Between skeleton no.1285 and skeleton no. 1276.

*Finds*

Shackles: No

*Estimate of sex: Undetermined*

Criteria: Neither skull, pelvis nor measurement are sufficiently preserved

*Estimate of age at death: Adult*

Criteria: Epiphyses

*Epiphyses*

Skull (cranium + mandible)	U
Thorax (sternum + ribs)	U
Vertebral column	U
Shoulder girdle (clavicle + scapula)	>18
Upper limbs	U
Pelvis (coxae + sacrum + coccygis)	U
Lower limbs	>18

*Stature: 163.75 cm (femur sin)*

*Pathology/Trauma*

*Antemortem* trauma: U

Likely *perimortem* trauma: U

Possible *perimortem* trauma: U

**SKELETON NO. 1285—ROW 3 (FIG. 151)**

*Taphonomy/Preservation*

The skeleton is probably placed on its left side in a SW–NE (with cranium to the SW) direction. Legs are bent. The skull is crushed; left mandible missing. Both arms and hands are missing. Approximately half of the skeleton is preserved, but the quality of the bones is poor and more than 2/3 of the skeleton is fragmented and affected by erosion.

Quantitative preservation: 2

Qualitative preservation: 1

*Position*

Skeleton: Lateral—on the left side (probably)

Cranium: U

Limbs: Left upper limb—A, Left hand—A, Left lower limb—A, Right upper limb—A, Right hand—A, Right lower limb—flexed

*Relation to other skeletons*

North of skeleton no. 1277

*Finds*

Shackles: No

*Estimate of sex: Undetermined*

Criteria: Skull

*Skull*

Skull—trait	Left	L/R	Right
Angle of the frontal		U	
Frontal/parietal eminences		U	
Nuchal crest		U	
Mastoid process	U		4
Zygomatic bone	U		U
Orbital outline	U		U
Supraorbital margin	U		U
Glabella		U	
Gonial angle flare	U		U
Mental eminence		U	

*Estimate of age at death: Adult*

Criteria: Epiphyses, and tooth eruption

*Epiphyses*

Skull (cranium + mandible)	U
Thorax (sternum + ribs)	U
Vertebral column	U
Shoulder girdle (clavicle + scapula)	U
Upper limbs	U
Pelvis (coxae + sacrum + coccygis)	>23
Lower limbs	>18

*Tooth eruption, M3*

Maxilla	Mandible
U	Sin—erupted Dx—U

*Stature: 163.75 cm (femur sin)*

*Pathology/Trauma*

*Antemortem* trauma: U

Likely *perimortem* trauma: U

Possible *perimortem* trauma: U

**SKELETON NO. 1294—ROW 3 (FIG. 152)**

*Taphonomy/Preservation*

The skeleton is placed in a prone position with outstretched legs in a NNE—SSW direction (cranium to the SSW), with hands in a shackle above the head.

The left elbow is dislocated, as is the left humerus. The skeleton is almost complete; more than 2/3 of the skeletal parts are present, and they are well preserved.

Quantitative preservation: 3

Qualitative preservation: 3

*Position*

Skeleton: Prone

Cranium: Prone—but bent backwards

Limbs: Left upper limb—flexed, Left hand—U, Left lower limb—slightly flexed, Right upper limb—flexed, Right hand—U, Right lower limb—slightly flexed

*Relation to other skeletons*

The skeleton is placed above the skeletons nos. 1316 and 1332; the right tibia and fibula are placed below skeleton no. 1272

*Finds*

Shackles: Yes—wrists

*Estimate of sex: Undetermined*

Criteria: Skull, and pelvis

*Skull*

Skull—trait	Left	L/R	Right
Angle of the frontal		U	
Frontal/parietal eminences		U	
Nuchal crest		U	
Mastoid process	U		U
Zygomatic bone	U		3
Orbital outline	U		U
Supraorbital margin	U		3
Glabella		3–4	
Gonial angle flare	2		U
Mental eminence		U	

*Pelvis*

Pelvis—trait	Left	Right
Subpubic concavity	U	U
Ventral arc	U	U
Ischiopubic ramus	U	U
Subpubic angle	U	U
Greater sciatic notch	U	3
Preauricularis sulcus	U	U

*Estimate of age at death: Adult*

Criteria: Epiphyses, suture closure, and tooth eruption

*Epiphyses*

Skull (cranium + mandible)	U
Thorax (sternum + ribs)	U
Vertebral column	U
Shoulder girdle (clavicle + scapula)	>23
Upper limbs	>17
Pelvis (coxae + sacrum + coccygis)	>23
Lower limbs	>18

*Suture closure (ectocranial)*

Coronal	U
Sagittal	U
Lambdoid	Significant

*Tooth eruption, M3*

Maxilla	Mandible
Sin—U Dx—erupted	Sin/dx—U

*Stature: 163.75 cm (femur sin)*

*Pathology/Trauma*

*Antemortem* trauma: U

Likely *perimortem* trauma: U

Possible *perimortem* trauma: U (crust covers large part of the cranium)

**SKELETON NO. 1316—ROW 3 (FIGS. 50 & 153)**

*Taphonomy/Preservation*

The skeleton is placed on its right side in a NE—SW direction (cranium to the SW), with hands in a shackle above the head. Legs are bent to the right. A small tabular piece of limestone is found directly to the S of the hands. Approximately half of the skeleton is preserved. The quality of the bones is intermediate, and around 1/3–2/3 of the bones have a pronounced degree of erosion of surfaces and fragmentation.

Quantitative preservation: 2

Qualitative preservation: 2

*Position*

Skeleton: Lateral—on right side

Cranium: Lateral—on right side

Limbs: Left upper limb—flexed, Left hand—U, Left lower limb—flexed, Right upper limb—flexed, Right hand—U/A, Right lower limb—flexed

*Relation to other skeletons*

Thorax below the skull of skeleton no. 1294



Fig. 152. Skeleton no. 1294.

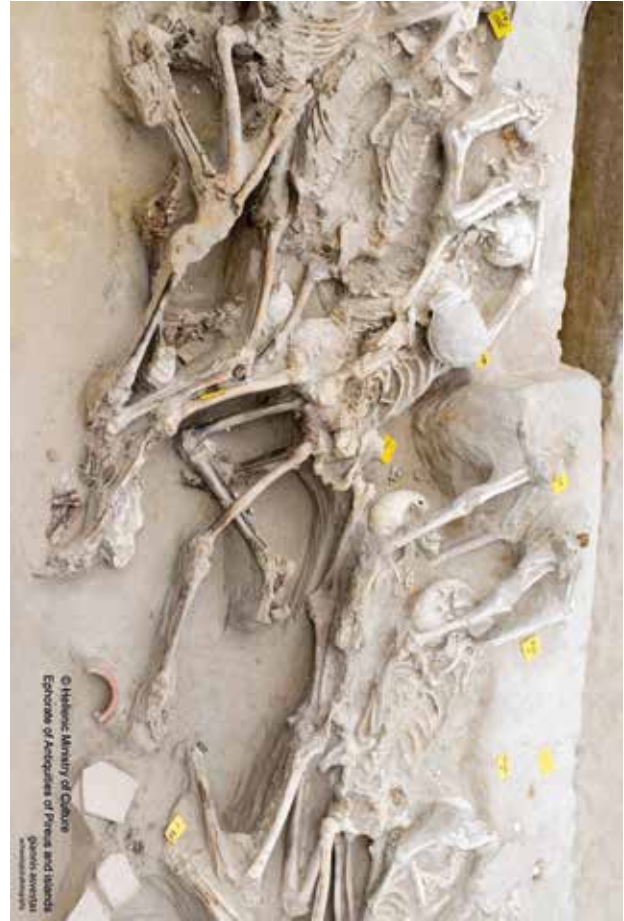

Fig. 153. Skeleton no. 1316.

*Finds*

Shackles: Yes—wrists

*Estimate of sex: Undetermined*

Criteria: Skull

*Skull*

Skull—trait	Left	L/R	Right
Angle of the frontal		U	
Frontal/parietal eminences		U	
Nuchal crest		4	
Mastoid process	U		U
Zygomatic bone	2		U
Orbital outline	U		U
Supraorbital margin	U		U
Glabella		U	
Gonial angle flare	U		U
Mental eminence		U	

*Estimate of age at death: Adult*

Criteria: Epiphyses, suture closure, and tooth wear

*Epiphyses*

Skull (cranium + mandible)	U
Thorax (sternum + ribs)	U
Vertebral column	U
Shoulder girdle (clavicle + scapula)	U
Upper limbs	>17
Pelvis (coxae + sacrum + coccygis)	U
Lower limbs	>18

*Suture closure (ectocranial)*

Coronal	Significant
Sagittal	Significant
Lambdoid	Significant

*Tooth wear*

Maxilla	Mandible
M2 sin wear	U

*Pathology/Trauma*

Dental pathology: No?

*Antemortem* trauma: U

Likely  *perimortem* trauma: X

Possible  *perimortem* trauma: U

**SKELETON NO. 1332—ROW 3 (FIG. 154)**

*Taphonomy/Preservation*

Skeleton is placed in a supine position in an approximate N–S direction (cranium to the S, and bent to the left), with hands in a shackle above the head. A piece of limestone is found directly to the SW of the skull. A right tibia, not belonging to this individual, was found above the right arm. The skeleton is almost complete; more than 2/3 of the skeletal parts are present, and they are well preserved.

Quantitative preservation: 3

Qualitative preservation: 3

*Position*

Skeleton: Supine

Cranium: Supine—cranium on left side

*Limbs: Left upper limb—unobservable,*

*Left hand—on top of left rib cage, Left*

*lower limb—absent, Right upper limb—*

*flexed, Right hand—palm upwards,*

*Right lower limb—flexed Relation to other skeletons*

The skeleton is partly below skeleton no. 1316

*Finds*

Shackles: Yes—wrists

*Estimate of sex: Undetermined*

Criteria: Skull

*Skull*

Skull—trait	Left	L/R	Right
Angle of the frontal		U	
Frontal/parietal eminences		U	
Nuchal crest		5	
Mastoid process	U		3
Zygomatic bone	U		2
Orbital outline	U		U
Supraorbital margin	U		U
Glabella		U	
Gonial angle flare	U		2
Mental eminence		U	

*Estimate of age at death: Young adult*

Criteria: Epiphyses, pubic symphysis, tooth eruption, and tooth wear

*Epiphyses*

Skull (cranium + mandible)	U
Thorax (sternum + ribs)	U
Vertebral column	U
Shoulder girdle (clavicle + scapula)	U
Upper limbs	>15
Pelvis (coxae + sacrum + coccygis)	>23
Lower limbs	>17

*Pubic symphysis*

Left	Right
II:1, c. 23.4	U

*Tooth eruption, M3*

Maxilla	Mandible
Sin—U	Sin—U
Dx—erupted	Dx—erupted

*Tooth wear*

Maxilla	Mandible
17–25	U

*Pathology/Trauma*

*Antemortem* trauma: U

Likely *perimortem* trauma: U

Possible *perimortem* trauma: U

**SKELETON NO. 1333—ROW 3 (FIGS. 51, 80, & 155)**

*Taphonomy/Preservation*

The skeleton is placed in a supine position in a N–S direction (cranium to the S), with hands in a shackle above the head. Right legs is flexed. Feet are unobservable. The skeleton is almost complete. The quality of the bones is intermediate, and around 1/3–2/3 of the bones have a pronounced degree of erosion of surfaces and fragmentation.

Quantitative preservation: 3

Qualitative preservation: 2

*Position*

Skeleton: Supine

Cranium: Supine—cranium slightly on left side

*Limbs: Left upper limb—flexed, Left*

*hand—extended, Left lower limb—very*

*flexed, Right upper limb—flexed, Right*

*hand—flexed, Right lower limb—flexed*

*Relation to other skeletons*

Partly below skeleton no. 1385

*Finds*

Shackles: Yes

*Estimate of sex: Male?*

Criteria: Skull, and pelvis

*Skull*

Skull—trait	Left	L/R	Right
Angle of the frontal		U	
Frontal/parietal eminences		U	
Nuchal crest		U	
Mastoid process	4		U
Zygomatic bone	2		U
Orbital outline	2		U
Supraorbital margin	2		2
Glabella		3	
Gonial angle flare	U		U
Mental eminence		4	

*Pelvis*

Pelvis—trait	Left	Right
Subpubic concavity	U	U
Ventral arc	U	U
Ischiopubic ramus	U	U
Subpubic angle	U	U
Greater sciatic notch	U	4
Preauricularis sulcus	U	U

*Estimate of age at death: Young adult*

Criteria: Epiphyses, suture closure, and tooth eruption

*Epiphyses*

Skull (cranium + mandible)	U
Thorax (sternum + ribs)	U
Vertebral column	U
Shoulder girdle (clavicle + scapula)	16–21
Upper limbs	>17
Pelvis (coxae + sacrum + coccygis)	<27
Lower limbs	>20

*Suture closure (ectocranial)*

Coronal	U
Sagittal	Minimal
Lambdoid	U

*Tooth eruption, M3*

Maxilla	Mandible
Sin/dx—erupted	Sin/dx—erupted

*Pathology/Trauma*

Dental pathology: Large caries buccal on left M1 mandible

*Antemortem* trauma: U

Likely *perimortem* trauma: X

Possible *perimortem* trauma: X

**SKELETON NO. 1344—ROW 3 (FIGS. 20, 35, & 156)**

*Taphonomy/Preservation*

Skeleton is placed in a prone position in a NE–SW direction (cranium to the SW, resting slightly on the right side), with hands in a shackle above the head. Right arm is unobservable, probably below the skull covered by soil. The skeleton is almost complete; more than 2/3 of the skeletal parts are present, and they are well preserved.

Quantitative preservation: 3

Qualitative preservation: 3

*Position*

Skeleton: Prone



Fig. 154. Skeleton no. 1332.



Fig. 155. Skeleton no. 1333.

Cranium: Prone—cranium slightly on the right

Limbs: Left upper limb—flexed, Left hand—extended, Left lower limb—flexed, Right upper limb—U, Right hand—flexed, Right lower limb—U

*Relation to other skeletons*

Partly below skeleton no. 1333

*Finds*

Knife, medial of the left tibia

Shackles: Yes—wrists

*Estimate of sex: Male?*

Criteria: Skull, and pelvis

*Skull*

Skull—trait	Left	L/R	Right
Angle of the frontal		U	
Frontal/parietal eminences		No	
Nuchal crest		U	
Mastoid process	U		U
Zygomatic bone	3		U
Orbital outline	U		U
Supraorbital margin	U		U
Glabella		U	
Gonial angle flare	3		U
Mental eminence		U	

*Pelvis*

Pelvis—trait	Left	Right
Subpubic concavity	U	U
Ventral arc	U	U
Ischiopubic ramus	U	U
Subpubic angle	U	U
Greater sciatic notch	5	U
Preauricularis sulcus	U	U

*Estimate of age at death: Adult*

Criteria: Epiphyses, and suture closure

*Epiphyses*

Skull (cranium + mandible)	U
Thorax (sternum + ribs)	U
Vertebral column	U
Shoulder girdle (clavicle + scapula)	U
Upper limbs	U
Pelvis (coxae + sacrum + coccygis)	>20
Lower limbs	U



Fig. 156. Skeleton no. 1344.



Fig. 157. Skeleton no. 1384.

*Suture closure (ectocranial)*

Coronal	Significant
Sagittal	Significant
Lambdoid	Significant

*Pathology/Trauma*

Cribrra and PH: left and right parietals with porosity, enlarged parietal foramina

*Antemortem* trauma: U

Likely *perimortem* trauma: U

Possible *perimortem* trauma: U

**SKELETON NO. 1384—ROW 3 (FIG. 157)**

*Taphonomy/Preservation*

The skeleton is placed in a supine position in an approximate N–S direction (cranium to the S, and bent to the left), with hands in a shackle above the head. The skeleton is almost complete; more

than 2/3 of the skeletal parts are present, and they are well preserved.

Quantitative preservation: 3

Qualitative preservation: 3

*Position*

Skeleton: Supine

Cranium: Lateral—on left side

Limbs: Left upper limb—flexed, Left hand—U, Left lower limb—extremely flexed, Right upper limb—flexed, Right hand—U, Right lower limb—flexed

*Relation to other skeletons*

Knee partly below skeleton no. 1332 and skeleton no. 1316

*Finds*

Ceramics under the right knee.

Shackles: Yes—wrists. Possibly right arm tied with left arm of skeleton no. 1385, same clamp?

*Estimate of sex: Male?*

Criteria: Skull, and pelvis

*Skull*

Skull—trait	Left	L/R	Right
Angle of the frontal		U	
Frontal/parietal eminences		U	
Nuchal crest		U	
Mastoid process	U		4
Zygomatic bone	U		U
Orbital outline	U		U
Supraorbital margin	U		U
Glabella		U	
Gonial angle flare	3		U
Mental eminence		4–5	

*Pelvis*

Pelvis—trait	Left	Right
Subpubic concavity	U	U
Ventral arc	U	3
Ischiopubic ramus	U	U
Subpubic angle	U	U
Greater sciatic notch	U	U
Preauricularis sulcus	U	U

*Estimate of age at death: Middle adult*

Criteria: Epiphyses, suture closure, pubic symphysis, tooth eruption, and tooth wear

*Epiphyses*

Skull (cranium + mandible)	U
Thorax (sternum + ribs)	U
Vertebral column	U
Shoulder girdle (clavicle + scapula)	U
Upper limbs	>17
Pelvis (coxae + sacrum + coccygis)	>23
Lower limbs	U

*Suture closure (ectocranial)*

Coronal	Significant
Sagittal	U
Lambdoid	U

*Pubic symphysis*

Left	Right
U	V:1, 45.6

*Tooth eruption, M3*

Maxilla	Mandible
Sin—U	Sin—U
Dx—erupted	Dx—erupted

*Tooth wear*

Maxilla	Mandible
35–45	35–45

*Pathology/Trauma*

*Antemortem* trauma: U

Likely *perimortem* trauma: U

Possible *perimortem* trauma: U

**SKELETON NO. 1385—ROW 3 (FIG. 158)**

*Taphonomy/Preservation*

The skeleton is placed on its right side in an approximate N–S direction (cranium to the S), with hands in a shackle above the head. The lower arms are covered by a limestone slab. The skeleton is almost complete; more than 2/3 of the skeletal

parts are present, and they are well preserved.

Quantitative preservation: 3

Qualitative preservation: 3

*Position*

Skeleton: Lateral—on right side

Cranium: Lateral—on right side, almost prone

Limbs: Left upper limb—flexed, Left hand—U, Left lower limb—extended, Right upper limb—U, Right hand—U, Right lower limb—flexed

*Relation to other skeletons*

Partly below skeleton no. 1384; left femur slightly above skeleton no. 1333

*Finds*

Shackles: Yes—wrists. Possibly left arm tied with left arm of skeleton no. 1384, same clamp?

*Estimate of sex: Undetermined*

Criteria: Skull

*Skull*

Skull—trait	Left	L/R	Right
Angle of the frontal		U	
Frontal/parietal eminences		U	
Nuchal crest		U	
Mastoid process	4		U
Zygomatic bone	1		U
Orbital outline	U		U
Supraorbital margin	1		U
Glabella		U	
Gonial angle flare	U		U
Mental eminence		U	

*Estimate of age at death: Juvenile*

Criteria: Epiphyses, suture closure, tooth eruption, and tooth wear

*Epiphyses*

Skull (cranium + mandible)	U
Thorax (sternum + ribs)	U
Vertebral column	U
Shoulder girdle (clavicle + scapula)	U
Upper limbs	U
Pelvis (coxae + sacrum + coccygis)	U
Lower limbs	<18

*Suture closure (ectocranial)*

Coronal	U
Sagittal	U
Lambdoid	Open

*Tooth eruption, M3*

Maxilla	Mandible
Sin—not erupted	Sin/dx—U
Dx—U	

*Tooth wear*

Maxilla	Mandible
U	No wear

*Pathology/Trauma*

*Antemortem* trauma: U

Likely *perimortem* trauma: U

Possible *perimortem* trauma: X

**SKELETON NO. 1398—ROW 3 (FIG. 159)**

*Taphonomy/Preservation*

The skeleton is placed on its right side in a NNW–SSE direction (cranium to the SSE), with hands above the head. A limestone slab was placed on top of the knees. The skeleton is almost complete; more than 2/3 of the skeletal parts are present, and they are well preserved.

Quantitative preservation: 3

Qualitative preservation: 3

*Position*

Skeleton: Lateral—on right side

Cranium: Lateral—on right side

Limbs: Left upper limb—flexed, Left hand—U, Left lower limb—slightly flexed, Right upper limb—U, Right hand—extended, Right lower limb—slightly flexed

*Relation to other skeletons*

Arms close to and east to the back of skeleton no. 1399.

*Finds*

Shackles: Yes

*Estimate of sex: Undetermined*

Criteria: Skull, and pelvis



Fig. 158. Skeleton no. 1385.



Fig. 159. Skeleton no. 1398.

*Skull*

Skull—trait	Left	L/R	Right
Angle of the frontal		Straight	
Frontal/parietal eminences		Ambiguous	
Nuchal crest		4	
Mastoid process	2		U
Zygomatic bone	1		U
Orbital outline	U		U
Supraorbital margin	2		U
Glabella		3	
Gonial angle flare	3		U
Mental eminence		4	

*Pelvis*

Pelvis—trait	Left	Right
Subpubic concavity	U	U
Ventral arc	U	U
Ischiopubic ramus	U	U
Subpubic angle	U	U
Greater sciatic notch	3	U
Preauricularis sulcus	U	U

*Estimate of age at death: Young adult*

Criteria: Epiphyses, suture closure, and tooth eruption

*Epiphyses*

Skull (cranium + mandible)	U
Thorax (sternum + ribs)	U
Vertebral column	U
Shoulder girdle (clavicle + scapula)	16–21
Upper limbs	>17
Pelvis (coxae + sacrum + coccygis)	c. 20–23
Lower limbs	U

*Suture closure (ectocranial)*

Coronal	Open—significant
Sagittal	Significant
Lambdoid	Significant

*Tooth eruption, M3*

Maxilla	Mandible
Sin—erupted	Sin—erupted
Dx—U	Dx—U

*Pathology/Trauma*

*Antemortem* trauma: X

Likely *perimortem* trauma: U

Possible *perimortem* trauma: U

*Nonmetric skeletal traits*

Coronal ossicle



Fig. 160. Skeleton no. 1399.

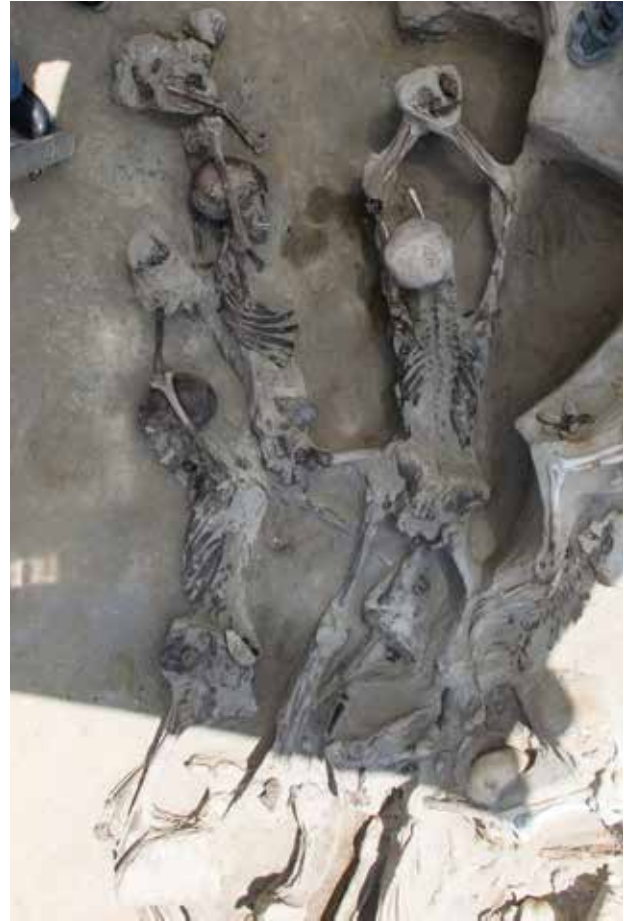

Fig. 161. Skeleton no. 1400.

**SKELETON NO. 1399—ROW 3  
(FIG. 160)**

*Taphonomy/Preservation*

The skeleton is placed on its left side in a NW–SE direction (cranium to the SE), with hands connected to a shackle above the head, and bent legs. The skeleton is almost complete; more than 2/3 of the skeletal parts are present, and they are well preserved.

Quantitative preservation: 3

Qualitative preservation: 3

*Position*

Skeleton: Lateral—on left side

Cranium: Lateral—on left side

Limbs: Left upper limb—extended, Left hand—flexed, Left lower limb—flexed, Right upper limb—flexed, Right hand—flexed, Right lower limb—flexed

*Relation to other skeletons*

Legs under the pelvis of skeleton no. 1400

*Finds*

Shackles: Yes—wrists

*Estimate of sex: Male*

Criteria: Skull, pelvis, and measurement

*Skull*

Skull—trait	Left	L/R	Right
Angle of the frontal		Straight	
Frontal/parietal eminences		No	
Nuchal crest		4	
Mastoid process	U		2
Zygomatic bone	U		U
Orbital outline	U		3
Supraorbital margin	U		4
Glabella		4	
Gonial angle flare	U		U
Mental eminence		U	

*Pelvis*

Pelvis—trait	Left	Right
Subpubic concavity	U	U
Ventral arc	U	U
Ischiopubic ramus	U	U
Subpubic angle	U	U
Greater sciatic notch	4	U
Preauricular sulcus	U	U

*Measurement*

47 cm (humerus dx, vertical diameter of head)

*Estimate of age at death: Young adult*

Criteria: Epiphyses, suture closure, and tooth eruption

*Epiphyses*

Skull (cranium + mandible)	U
Thorax (sternum + ribs)	U
Vertebral column	U
Shoulder girdle (clavicle + scapula)	>20
Upper limbs	>17
Pelvis (coxae + sacrum + coccygis)	>23
Lower limbs	>18

*Suture closure (ectocranial)*

Coronal	Open—minimal.
Sagittal	Significant
Lambdoid	Significant

*Tooth eruption, M3*

Maxilla	Mandible
Sin/dx—U	Sin—U Dx—erupting

*Stature: 170.55 cm (humerus dx)*

*Pathology/Trauma*

Dental pathology: Slight calculus on right I2, C, and M1, mandible

*Antemortem* trauma: U

Likely *perimortem* trauma: U

Possible *perimortem* trauma: X

**SKELETON NO. 1400—ROW 3  
(FIGS. 25 & 161)**

*Taphonomy/Preservation*

Skeleton is placed in a prone position in an approximate N–S direction (cranium to the S), with hands in a shackle above the head. The skeleton is almost com-

plete; more than 2/3 of the skeletal parts are present, and they are well preserved.

Quantitative preservation: 3

Qualitative preservation: 3

*Position*

Skeleton: Prone

Cranium: Prone

Limbs: Left upper limb—flexed, Left hand—U, Left lower limb—extended, Right upper limb—flexed, Right hand—U, Right lower limb—flexed

*Relation to other skeletons*

Below skeleton no. 1344 and c. 30 cm above the thorax of skeleton no. 1400—a white and weathered humerus was found.

*Finds*

Shackles: Yes

*Estimate of sex: Male?*

Criteria: Skull, and pelvis

*Skull*

Skull—trait	Left	L/R	Right
Angle of the frontal		U	
Frontal/parietal eminences		No	
Nuchal crest		U	
Mastoid process	U		U
Zygomatic bone	U		U
Orbital outline	U		U
Supraorbital margin	U		U
Glabella		U	
Gonial angle flare	U		U
Mental eminence		U	

*Pelvis*

Pelvis—trait	Left	Right
Subpubic concavity	U	U
Ventral arc	U	U
Ischiopubic ramus	U	U
Subpubic angle	U	U
Greater sciatic notch	4	U
Preauricularis sulcus	U	U

*Estimate of age at death: Adult*

Criteria: Epiphyses, and suture closure

*Epiphyses*

Skull (cranium + mandible)	U
Thorax (sternum + ribs)	U
Vertebral column	U
Shoulder girdle (clavicle + scapula)	>18
Upper limbs	>20
Pelvis (coxae + sacrum + coccygis)	>23
Lower limbs	>20

*Suture closure (ectocranial)*

Coronal	Significant
Sagittal	Significant
Lambdoid	Significant

*Pathology/Trauma*

*Antemortem* trauma: U

Likely *perimortem* trauma: U

Possible *perimortem* trauma: U

*Nonmetric skeletal traits*

Metopic suture; lambdoid ossicles

## Appendix 2

### Results of aDNA analyses of 63 individuals from Phaleron, Greece

By Anna Linderholm, Anna Kjellström, Vendela Kempe Lagerholm, and Maja Krzewińska

DNA analyses of 63 individuals (i.e. samples from teeth) from Phaleron, with the aim of whole genome sequencing, was undertaken at the Archaeological Research Laboratory (AFL), Stockholm University. All individuals were sub-sampled in March 2017 directly at the excavation site at Phaleron, near Athens, Greece. The genetic analyses were performed in a dedicated ancient DNA Laboratory (AFL). The adopted methodology consisted of DNA extraction<sup>104</sup> followed by blunt-end DNA library preparation<sup>105</sup> and whole genome sequencing on Illumina HiSeq X platform (150bp, pair-end) at Science for Life Laboratory in Stockholm.

The generated raw sequencing data was analysed following previously published procedures.<sup>106</sup> Sequencing reads were demultiplexed based on index sequences<sup>107</sup>, followed by pair-end-read merging, trimming, and mapping to the human reference genome build 37, with BWA v. 0.7.13.<sup>108</sup> Finally the PCR duplicates were removed with FilterUniqueSAMCons.py.<sup>109</sup> The presence of 3' and 5' cytosine deamination patterns characteristic of ancient DNA<sup>110</sup> was estimated using PMDtools.<sup>111</sup>

The DNA preservation in the material from Phaleron was very poor. All individuals were tested at least once and in 21

cases two independent DNA extractions were performed, followed by preparation and sequencing of two independent DNA libraries.

On average 24,401,881 sequencing reads were obtained from each of the individually sequenced DNA libraries, but only 7,012 mapped to the human genome, and the average proportion of human DNA was around 0.3% (Table 26). The mapped sequences were shown to have relatively high clonality (number of repeated sequences) reaching >20% and very poor damage patterns, probably resulting from very low endogenous DNA content. The endogenous DNA content was so low that in a number of individuals not a single DNA sequence mapping to mitochondrial DNA (mtDNA) was identified. In others, the numbers did not allow for mtDNA haplogroup identification which usually calls for at least 1x coverage of mtDNA genome for accurate estimation.<sup>112</sup> Overall poor preservation did not even allow for sex identification of the individuals, which calls for at least 100,000 endogenous sequences to allow for reliable identification.<sup>113</sup>

In conclusion, DNA preservation was too poor to allow for any successful DNA analyses.

<sup>104</sup> Malmström *et al.* 2009; Svensson *et al.* 2007; Yang *et al.* 1998.

<sup>105</sup> Meyer & Kircher 2010.

<sup>106</sup> Günther *et al.* 2018; 2015.

<sup>107</sup> Meyer & Kircher 2010.

<sup>108</sup> Li & Durbin 2010.

<sup>109</sup> Kircher 2012.

<sup>110</sup> Briggs *et al.* 2007; Hansen *et al.* 2001; Hofreiter *et al.* 2001; Orlando *et al.* 2011; Sawyer *et al.* 2012.

<sup>111</sup> Skoglund *et al.* 2014.

<sup>112</sup> Vianello *et al.* 2013.

<sup>113</sup> Skoglund *et al.* 2013.

Table 26. Summary of sequencing statistics.

No.	Library ID	Sample	Human sequences	Proportion human DNA	Genome coverage	Mt genome coverage
1	flr201-b1e11p1	Sk. 1201	2,357	0.0011	0.00002	0.0000
2	flr202-b1e11p1	Sk. 1202	4,380	0.0016	0.00011	0.0159
3	flr215-b1e11p1	Sk. 1215	313	0.0021	0.00001	0.0000
4	flr215-b2e11p1	Sk. 1215	4,706	0.0015	0.00012	0.0363
5	flr228-b1e11p1	Sk. 1228	2,492	0.0021	0.00006	0.0062
6	flr245-b1e11p1	Sk. 1245	4,657	0.0064	0.00013	0.0311
7	flr247-b1e11p1	Sk. 1247	595	0.0007	0.00001	0.0000
8	flr253-b1e11p1	Sk. 1253	1,383	0.0008	0.00001	0.0053
9	flr266-b1e11p1	Sk. 1266	5,077	0.0023	0.00021	0.0184
10	flr267-b1e11p1	Sk. 1267	118,152	0.0076	0.00474	0.0977
11	flr268-b1e11p1	Sk. 1268	7,649	0.0144	0.00017	0.0000
12	flr269-b1e11p1	Sk. 1269	2,403	0.0020	0.00007	0.0164
13	flr271-b2e11p1	Sk. 1271	1,667	0.0016	0.00004	0.0061
14	flr271-b1e11p1	Sk. 1271	5,978	0.0035	0.00018	0.0560
15	flr272-b1e11p1	Sk. 1272	1,801	0.0112	0.00003	0.0000
16	flr276-b1e11p1	Sk. 1276	6,265	0.0016	0.00008	0.0082
17	flr281-b1e11p1	Sk. 1281	1,658	0.0046	0.00005	0.0000
18	flr285-b1e11p1	Sk. 1285	1,564	0.0070	0.00001	0.0120
19	flr285-b2e11p1	Sk. 1285	6,289	0.0006	0.00017	0.0443
20	flr289-b1e11p1	Sk. 1289	2,515	0.0024	0.00008	0.0000
21	flr294-b1e11p1	Sk. 1294	2,201	0.0017	0.00003	0.0000
22	flr296-b1e11p1	Sk. 1296	2,673	0.0008	0.00006	0.0148
23	flr297-b1e11p1	Sk. 1297	323	0.0015	0.00001	0.0000
24	flr297-b2e11p1	Sk. 1297	6,708	0.0008	0.00019	0.0581
25	flr298-b2e11p1	Sk. 1298	1,776	0.0009	0.00005	0.0106
26	flr298-b1e11p1	Sk. 1298	4,316	0.0060	0.00009	0.0047
27	flr316-b1e11p1	Sk. 1316	35,346	0.0073	0.00150	0.2037
28	flr316-b2e11p1	Sk. 1316	11,624	0.0029	0.00031	0.0310
29	flr324-b1e11p1	Sk. 1324	2,055	0.0013	0.00006	0.0000
30	flr324-b2e11p1	Sk. 1324	7,751	0.0009	0.00020	0.0343
31	flr325-b1e11p1	Sk. 1325	1,996	0.0011	0.00002	0.0000
32	flr328-b1e11p1	Sk. 1328	10,761	0.0016	0.00033	0.0499
33	flr332-b1e11p1	Sk. 1332	4,859	0.0027	0.00014	0.0059
34	flr333-b1e11p1	Sk. 1333	6,041	0.0045	0.00022	0.0247
35	flr336-b1e11p1	Sk. 1336	3,083	0.0135	0.00008	0.0028
36	flr339-b1e11p1	Sk. 1339	308	0.0018	0.00001	0.0000
37	flr340-b1e11p1	Sk. 1340	1,374	0.0018	0.00004	0.0000
38	flr342-b1e11p1	Sk. 1342	3,095	0.0023	0.00008	0.0043
39	flr343-b1e11p1	Sk. 1343	2,535	0.0038	0.00009	0.0000
40	flr344-b1e11p1	Sk. 1344	6,399	0.0012	0.00017	0.0328

Table 26 continued.

No.	Library ID	Sample	Human sequences	Proportion human DNA	Genome coverage	Mt genome coverage
41	flr348-b1e11p1	Sk. 1348	815	0.0019	0.00002	0.0000
42	flr349-b1e11p1	Sk. 1349	7,250	0.0042	0.00031	0.0056
43	flr350-b1e11p1	Sk. 1350	7,340	0.0097	0.00030	0.0287
44	flr351-b1e11p1	Sk. 1353	1,675	0.0012	0.00003	0.0000
45	flr353-b2e11p1	Sk. 1354	7,648	0.0009	0.00024	0.0343
46	flr353-b1e11p1	Sk. 1355	9,525	0.0059	0.00041	0.0892
47	flr354-b1e11p1	Sk. 1354	33,176	0.0058	0.00148	0.1719
48	flr355-b1e11p1	Sk. 1355	4,009	0.0063	0.00014	0.0000
49	flr355-b2e11p1	Sk. 1355	4,521	0.0049	0.00014	0.0241
50	flr356-b1e11p1	Sk. 1356	4,627	0.0026	0.00016	0.0000
51	flr357-b1e11p1	Sk. 1357	1,028	0.0025	0.00003	0.0000
52	flr357-b1e11p1	Sk. 1357	22,261	0.0033	0.00063	0.0328
53	flr358-b1e11p1	Sk. 1358	3,652	0.0020	0.00011	0.0068
54	flr359-b1e11p1	Sk. 1359	5,950	0.0032	0.00014	0.0247
55	flr360-b1e11p1	Sk. 1360	1,128	0.0019	0.00003	0.0114
56	flr361-b1e11p1	Sk. 1361	2,997	0.0014	0.00008	0.0000
57	flr363-b1e11p1	Sk. 1363	5,811	0.0010	0.00014	0.0182
58	flr364-b1e11p1	Sk. 1364	1,468	0.0017	0.00005	0.0218
59	flr365-b1e11p1	Sk. 1365	3,457	0.0057	0.00012	0.0000
60	flr366-b1e11p1	Sk. 1366	3,570	0.0028	0.00009	0.0278
61	flr366-b2e11p1	Sk. 1366	9,949	0.0015	0.00032	0.0501
62	flr368-b1e11p1	Sk. 1368	6,184	0.0099	0.00021	0.0000
63	flr369-b1e11p1	Sk. 1369	9,130	0.0019	0.00031	0.0312
64	flr370-b1e11p1	Sk. 1370	765	0.0018	0.00001	0.0091
65	flr370-b2e11p1	Sk. 1370	7,012	0.0013	0.00024	0.0643
66	flr371-b1e11p1	Sk. 1371	2,195	0.0029	0.00003	0.0075
67	flr371-b2e11p1	Sk. 1371	10,451	0.0013	0.00026	0.0570
68	flr373-b1e11p1	Sk. 1373	207	0.0007	0.00000	0.0000
69	flr373-b2e11p1	Sk. 1373	5,049	0.0009	0.00014	0.1700
70	flr374-b1e11p1	Sk. 1374	355	0.0018	0.00001	0.0000
71	flr374-b2e11p1	Sk. 1374	35,346	0.0032	0.00107	0.0200
72	flr375-b2e11p1	Sk. 1375	1,867	0.0014	0.00003	0.0070
73	flr375-b1e11p1	Sk. 1375	6,738	0.0019	0.00018	0.0066
74	flr376-b2e11p1	Sk. 1376	6,308	0.0029	0.00023	0.0502
75	flr376-b1e11p1	Sk. 1376	5,763	0.0062	0.00026	0.0275
76	flr379-b1e11p1	Sk. 1379	2,855	0.0117	0.00005	0.0000
77	flr379-b2e11p1	Sk. 1379	2,277	0.0020	0.00004	0.0172
78	flr380-b1e11p1	Sk. 1380	1,727	0.0017	0.00003	0.0000
79	flr380-b2e11p1	Sk. 1380	8,402	0.0007	0.00022	0.0305
80	flr381-b1e11p1	Sk. 1381	48,539	0.0064	0.00212	0.4799

Table 26 continued.

No.	Library ID	Sample	Human sequences	Proportion human DNA	Genome coverage	Mt genome coverage
81	f1r382-b1e111p1	Sk. 1382	2,945	0.0016	0.00006	0.0073
82	f1r382-b2e111p1	Sk. 1382	10,123	0.0018	0.00021	0.0660
83	f1r383-b1e111p1	Sk. 1383	1,167	0.0017	0.00001	0.0000
84	f1r384-b1e111p1	Sk. 1384	1,404	0.0088	0.00003	0.0000
85	f1r385-b1e111p1	Sk. 1385	4,390	0.0033	0.00012	0.0311
86	f1r386-b1e111p1	Sk. 1386	1,634	0.0065	0.00003	0.0000
87	f1r387-b1e111p1	Sk. 1387	3,976	0.0024	0.00006	0.0066
88	f1r388-b1e111p1	Sk. 1388	8,935	0.0054	0.00033	0.0275
89	f1r389-b1e111p1	Sk. 1389	12,233	0.0032	0.00044	0.0091
90	f1r390-b1e111p1	Sk. 1390	3,374	0.0094	0.00013	0.0221
91	f1r397-b1e111p1	Sk. 1397	10,225	0.0034	0.00034	0.0536
92	f1r397-b2e111p1	Sk. 1397	4,430	0.0025	0.00006	0.0000
93	f1r398-b2e111p1	Sk. 1398	3,927	0.0015	0.00002	0.2433
94	f1r398-b1e111p1	Sk. 1398	2,997	0.0014	0.00001	0.0599
95	f1r399-b1e111p1	Sk. 1399	6,961	0.0025	0.00001	0.0037
96	f1r400-b1e111p1	Sk. 1400	2,968	0.0042	0.00002	0.0000

## Bibliography

- Angel, J.L. 1975. 'Paleoecology, paleodemography and health', in *Population, ecology and social evolution*, ed. S. Polgar, The Hague, 167–190.  
<https://doi.org/10.1515/9783110815603.167>
- Arbour, L. 2008. 'Blunt force trauma', in *Skeletal trauma. Identification of injuries resulting from human rights abuse and armed conflict*, ed. E.H. Kimmerle & J.P. Baraybar, Boca Raton, Florida, 151–195.
- Aufderheide, A.C. & C. Rodríguez-Martin 1998. *The Cambridge encyclopedia of human paleopathology*, Cambridge.
- Boehlau, J. 1887. 'Frühattische Vasen', *Jdl* 2, 33–66.
- Borrini, M., P.P. Mariani, C. Murgia, C. Rodriguez & T.V. Tumbarello 2012. 'Contextual taphonomy. Superficial bone alterations as contextual indicators', *Journal of Biological Research* 85:1, 217–219.  
<https://doi.org/10.4081/jbr.2012.4115>
- Briggs, A.W., U. Stenzel, P.L.F. Johnson, R.E. Green, J. Kelso, K. Prüfer, M. Meyer, J. Krause, M.T. Ronan, M. Lachmann & S. Pääbo 2007. 'Patterns of damage in genomic DNA sequences from a Neandertal', *Proceedings of the National Academy of Sciences of the United States of America* 104, 14616–14621.  
<https://doi.org/10.1073/pnas.0704665104>
- Brothwell, D.R. 1972<sup>2</sup>. *Digging up bones. The excavation, treatment and study of human skeletal remains*, London.
- Buikstra, J.E. & D.H. Ubelaker, eds. 1994. *Standards for data collection from human skeletal remains. Proceedings of a seminar at the Field Museum of Natural History organized by Jonathan Haas* (Arkansas Archeological Survey Research Series, 44), Fayetteville, Arkansas.
- Burk, M.P. 2012. *Forensic pathology of fractures and mechanisms of injury. Postmortem CT scanning*, London.  
<https://doi.org/10.1201/b11494>
- Byers, S.N. 2008<sup>3</sup>. *Introduction to forensic anthropology*, Boston.  
<https://doi.org/10.4324/9781315642031>
- Calce, T. & T.L. Rogers 2007. 'Taphonomic changes of blunt force trauma. A preliminary study', *Journal of Forensic Science* 52:3, 519–527.  
<https://doi.org/10.1111/j.1556-4029.2007.00405.x>
- Chryssoulaki, S. forthcoming. 'The excavations of Phaleron cemetery 2012–2017. An introduction', in *Rethinking Athens. Interdisciplinary approaches to the polis before the Persian Wars. Internationalen Workshop für junge Wissenschaftler vom 23.–24. Februar 2017 an der Ludwig-Maximilians-Universität München*, eds. C. Graml, A. Doronzio & V. Capozzoli, Munich.
- Cole, G. & T. Waldron 2016. 'Purple staining of archaeological human bone. An investigation of probable cause and implications for other tissues and artifacts', *Journal of Anthropology* 2016, article ID 9479051.  
<https://doi.org/10.1155/2016/9479051>
- DiMaio V.J. & D. DiMaio 2001<sup>2</sup>. *Forensic pathology*, Boca Raton, Florida.
- Dimitriadou, E.M. 2012. Πρώιμη Αθήνα (1100–480 π.Χ.). Παρατηρήσεις στην οικιστική εξέλιξη και στα νεκροταφεία, Ph.D. thesis, National and Kapodistrian University of Athens.
- Dirkmaat, D.C., L.L. Cabo, S.D. Ousley & S.A. Symes 2008. 'New perspectives in forensic anthropology', *Yearbook of Physical Anthropology* 51, 33–52.  
<https://doi.org/10.1002/ajpa.20948>
- Duday, H. 2009. *The archaeology of the dead. Lectures in archaeoethnology* (Studies in Funerary Archaeology, 3), Oxford.
- Dufton, A. & C. Fenwick 2012. 'Beyond the grave. Developing new tools for medieval cemetery analysis at Villamagna, Italy', in *Thinking beyond the tool. Archaeological computing and the interpretive process* (BAR-IS, 2344), eds. A. Chrysanthi, P. Murrieta Flores & C. Papadopoulos, Oxford, 155–167.
- Dupras, T.L. & J.J. Schultz 2013. 'Taphonomic bone staining and color changes in forensic contexts', in *Manual of forensic taphonomy*, eds. J.T. Pokines & S.A. Symes, Boca Raton, Florida, 315–340.  
<https://doi.org/10.1201/b15424-13>
- Finegan, O. 2008. 'Case study. The interpretation of skeletal trauma resulting from injuries sustained prior to, and as a direct result of freefall', in *Skeletal trauma. Identification of injuries resulting from human rights abuse and armed conflict*, eds. E.H. Kimmerle & J.P. Baraybar, Boca Raton, Florida, 181–195.
- Galloway, A. & V.L. Wedel 2014<sup>2</sup>. 'Bones of the skull, the dentition and osseous structures of the throat', in *Broken bones. Anthropological analysis of blunt force trauma*, eds. V.L. Wedel & A. Galloway, Springfield, Illinois, 133–160.

- Galloway, A., L. Zephro & V.L. Wedel 2014<sup>2</sup>. 'Diagnostic criteria for the determination and classification of timing and fracture mechanism', in *Broken bones. Anthropological analysis of blunt force trauma*, eds. V.L. Wedel & A. Galloway, Springfield, Illinois, 47–58.
- Goodman, A.H. & J.C. Rose 1990. 'Assessment of systemic physiological perturbations from dental enamel hypoplasias and associated histological structures', *American Journal of Physical Anthropology* 33, 59–110. <https://doi.org/10.1002/ajpa.1330330506>
- Goodman, A., G. Armelagos & J. Rose 1980. 'Enamel hypoplasias as indicators of stress in three prehistoric populations from Illinois', *Human Biology* 52:3, 515–528.
- Günther, T., H. Malmström, E.M. Svensson, A. Omrak, F. Sánchez-Quinto, G.M. Kılınc, M. Krzewińska, G. Eriksson, M. Fraser, H. Edlund, A.R. Munters, A. Coutinho, L.G. Simões, M. Vicente, A. Sjölander, B. Jansen Sellevold, R. Jørgensen, P. Claes, M.D. Shriver, C. Valdiosera, M.G. Netea, J. Apel, K. Lidén, B. Skar, J. Storå, A. Götherström & M. Jakobsson 2018. 'Population genomics of Mesolithic Scandinavia. Investigating early postglacial migration routes and high-latitude adaptation', *PLOS Biology* 16, article ID e2003703. <https://doi.org/10.1371/journal.pbio.2003703>
- Günther, T., C. Valdiosera, H. Malmström, I. Ureña, R. Rodriguez-Varela, Ó.O. Sverrisdóttir, E.A. Daskalaki, P. Skoglund, T. Naidoo, E.M. Svensson, J.M. Bermúdez de Castro, E. Carbonell, M. Dunn, J. Storå, E. Iriarte, J.L. Arsuaga, J.-M. Carretero, A. Götherström & M. Jakobsson 2015. 'Ancient genomes link early farmers from Atapuerca in Spain to modern-day Basques', *Proceedings of the National Academy of Sciences* 112, 11917–11922. <https://doi.org/10.1073/pnas.1509851112>
- Guyomarc'h, P., M. Campagna-Vaillancourt, C. Kremer & A. Sauvageau 2010. 'Discrimination of falls and blows in blunt head trauma. A multi-criteria approach', *Journal of Forensic Sciences* 55:2, 423–427. <https://doi.org/10.1111/j.1556-4029.2009.01310.x>
- Hansen, A., E. Willerslev, C. Wiuf, T. Mourier, P. Arctander 2001. 'Statistical evidence for miscoding lesions in ancient DNA templates', *Molecular Biology and Evolution* 18:2, 262–265. <https://doi.org/10.1093/oxfordjournals.molbev.a003800>
- Hillson, S. 1996. *Dental anthropology*, Cambridge. <https://doi.org/10.1017/CBO9781139170697>
- Hofreiter, M., V. Jaenicke, D. Serre, A. von Haeseler, S. Pääbo 2001. 'DNA sequences from multiple amplifications reveal artifacts induced by cytosine deamination in ancient DNA', *Nucleic Acids Research* 29, 4793–4799. <https://doi.org/10.1093/nar/29.23.4793>
- Keramopoulos, A. 1923. *Αποτυμpanισμός. Συμβολή αρχαιολογική εις την ιστορίαν του Ποινικού Δικαίου και την Λαογραφία*, Athens.
- Kimmerle, E.H. & J.P. Baraybar, eds. 2008. *Skeletal trauma. Identification of injuries resulting from human rights abuse and armed conflict*, Boca Raton, Florida. <https://doi.org/10.1201/9781420009118>
- Kircher, M. 2012. 'Analysis of high-throughput ancient DNA sequencing data', in *Methods in molecular biology*, eds. B. Shapiro & M. Hofreiter, New York, 197–228. [https://doi.org/10.1007/978-1-61779-516-9\\_23](https://doi.org/10.1007/978-1-61779-516-9_23)
- Knüsel, C.J. 2014. 'Crouching in fear. Terms of engagement for funerary remains', *Journal of Social Archaeology* 14, 26–58. <https://doi.org/10.1177/1469605313518869>
- Knüsel, C.J. & J. Robb 2016. 'Funerary taphonomy. An overview of goals and methods', *JAS Reports* 10, 655–673. <https://doi.org/10.1016/j.jasrep.2016.05.031>
- Kourouniotis, K. 1911. 'Ἐξ Αττικῆς. Α' Ανασκαφαί Παλαιού Φαλήρου', *AEphem* 50, 246–251.
- Kranioti, E.F. 2015. 'Forensic investigation of cranial injuries due to blunt force trauma. Current best practice', *Research and Reports in Forensic Medical Science* 2015:5, 27–35. <https://doi.org/10.2147/rrfms.s70423>
- Kremer, C., S. Racette, C.-A. Dionne & A. Sauvageau 2008. 'Discrimination of falls and blows in blunt force head trauma. Systematic study of the hat brim line rule in relation to skull fractures', *Journal of Forensic Sciences* 53:3, 716–719. <https://doi.org/10.1111/j.1556-4029.2008.00725.x>
- Krogman, W.M. 1978. *The human skeleton in forensic medicine*, Springfield, Illinois.
- Krovitz, G.E. & P. Shipman 2007. 'Taphonomy of immature hominid skulls and the Taung, Mojokerto, and Herto specimens', in *Breathing life into fossils. Taphonomic studies in honor of C.K. (Bob) Brain* (Stone Age Institute Publication Series, 2), eds. T.R. Pickering, K. Schick & N. Toth, Gosport, Indiana, 207–232.
- Larsen, C.P. 1997<sup>1</sup>. *Bioarchaeology. Interpreting behavior from the human skeleton* (Cambridge Studies in Biological Anthropology, 21), Cambridge.

- Larsen, C.P. 2015<sup>2</sup>. *Bioarchaeology. Interpreting behavior from the human skeleton* (Cambridge Studies in Biological and Evolutionary Anthropology, 69), Cambridge.
- Li, H. & R. Durbin 2010. 'Fast and accurate long-read alignment with Burrows–Wheeler transform', *Bioinformatics* 26, 589–595.  
<https://doi.org/10.1093/bioinformatics/btp698>
- Lieverse, A.R. 1999. 'Diet and the aetiology of dental calculus', *International Journal of Osteoarchaeology* 9:4, 219–232.  
[https://doi.org/10.1002/\(sici\)1099-1212\(199907/08\)9:4<219::aid-oa475>3.0.co;2-v](https://doi.org/10.1002/(sici)1099-1212(199907/08)9:4<219::aid-oa475>3.0.co;2-v)
- Lillie, M.C. 1996. 'Mesolithic and Neolithic populations of Ukraine. Indications of diet from dental pathology', *CurrAnthr* 37:1, 135–142.  
<https://doi.org/10.1086/204479>
- Liston, M.A. & L.P. Day 2009. 'It does take a brain surgeon. A successful trepanation from Kavousi, Crete', in *New directions in the skeletal biology of Greece* (Occasional Wiener Laboratory Series, 1), eds. L.A. Schepartz, S.C. Fox & C. Bourbou, Princeton, New Jersey, 57–73.
- Lovell, N.C. 1997. 'Trauma analysis in paleopathology', *Yearbook of Physical Anthropology* 40, 139–170.  
[https://doi.org/10.1002/\(sici\)1096-8644\(1997\)25+<139::aid-ajpa6>3.0.co;2-#](https://doi.org/10.1002/(sici)1096-8644(1997)25+<139::aid-ajpa6>3.0.co;2-#)
- Lukacs, J.R. 2007. 'Dental trauma and antemortem tooth loss in prehistoric Canary Islanders. Prevalence and contributing factors', *International Journal of Osteoarchaeology* 17:2, 157–173.  
<https://doi.org/10.1002/oa.864>
- Lyman, L. 2010. 'What taphonomy is, what it isn't, and why taphonomists should care about the difference', *Journal of Taphonomy* 8:1, 1–16.
- Malmström, H., M.T. Gilbert, M.G. Thomas, M. Brandström, J. Storå, P. Molnar, P.K. Andersen, C. Bendixen, G. Holmlund, A. Götherström & E. Willerslev 2009. 'Ancient DNA reveals lack of continuity between Neolithic hunter-gatherers and contemporary Scandinavians', *Current Biology* 19, 1758–1762.  
<https://doi.org/10.1016/j.cub.2009.09.017>
- Mann, R.W. & D.R. Hunt 2005<sup>2</sup>. *Photographic regional atlas of bone disease. A guide to pathologic and normal variation in the human skeleton*, Springfield, Illinois.
- Maples, W.R. 1986. 'Trauma analysis by the forensic anthropologist', in *Forensic osteology. Advances in the identification of human remains*, ed. K.J. Reichs, Springfield, Illinois, 218–228.
- Meyer, M. & M. Kircher 2010. 'Illumina sequencing library preparation for highly multiplexed target capture and sequencing', *Cold Spring Harbor Protocols* 2010, article ID pdb.prot5448.  
<https://doi.org/10.1101/pdb.prot5448>
- Moritz, A.R. 1954<sup>2</sup>. *The pathology of trauma*, Philadelphia, Pennsylvania.
- Morris, I. 1989. 'Attitudes toward death in Archaic Greece', *CLAnt* 8:2, 296–320.  
<https://doi.org/10.2307/25010911>
- Morris, I. 1992. *Death-ritual and social structure in Classical Antiquity*, Cambridge.  
<https://doi.org/10.1017/CBO9780511611728>
- Nawrocki, S.P., J.E. Pless, D.A. Hawley & S.A. Wagner 1997. 'Fluvial transport of human crania', in *Forensic taphonomy. The postmortem fate of human remains*, eds. W.D. Haglund & M.H. Sorg, Boca Raton, Florida, 529–548.  
<https://doi.org/10.1201/9781439821923.sec5>
- Orlando, L., A. Ginolhac, M. Raghavan, J. Vilstrup, M. Rasmussen, K. Magnussen, K.E. Steinmann, P. Kapranov, J.F. Thompson, G. Zazula, D. Froese, I. Moltke, B. Shapiro, M. Hofreiter, K.A. Al-Rasheid, M.T. Gilbert & E. Willerslev 2011. 'True single-molecule DNA sequencing of a Pleistocene horse bone', *Genome Research* 21, 1705–1719.  
<https://doi.org/10.1101/gr.122747.111>
- Ortner, D.J. 2003<sup>2</sup>. *Identification of pathological conditions in human skeletal remains*, Amsterdam.  
<https://doi.org/10.1016/B978-0-12-528628-2.X5037-6>
- Ortner, D.J. & G.J. Putschar 1985<sup>1</sup>. *Identification of pathological conditions in human skeletal remains* (Smithsonian Contributions to Anthropology, 28), Washington.
- Parker, R. 1983. *Miasma. Pollution and purification in early Greek religion*, Oxford.
- Pelekidis, S. 1916. 'Ανασκαφή Παλαιού Φαλήρου', *ADelt* B2, 13–64.
- Philippson, A. & E. Kirsten 1952. *Die griechischen Landschaften 1:3. Attika und Megaris*, Frankfurt.
- Pink, C.M. 2016. 'Forensic ancestry assessment using cranial nonmetric traits traditionally applied to biological distance studies', in *Biological distance analysis. Forensic and bioarchaeological perspectives*, eds. M.A. Pilloud & J.T. Hefner, London, 213–230.  
<https://doi.org/10.1016/b978-0-12-801966-5.00011-1>

- Rodríguez-Martin, C. 2006. 'Identification and differential diagnosis of traumatic lesions of the skeleton', in *Forensic anthropology and medicine. Complementary sciences from recovery to cause of death*, eds. A. Schmitt, E. Cunha & J. Pinheiro, Totowa, New Jersey, 197–221. [https://doi.org/10.1007/978-1-59745-099-7\\_8](https://doi.org/10.1007/978-1-59745-099-7_8)
- Rogers, J. & T. Waldron 1995. *A field guide to joint disease in archaeology*, Chichester & New York.
- Rogers, J., L. Shepstone & P. Dieppe 1997. 'Bone formers. Osteophyte and enthesophyte formation are positively associated', *Annals of the Rheumatic Diseases* 56:2, 85–90. <https://doi.org/10.1136/ard.56.2.85>
- Sauer, N.J. 1998. 'The timing of injuries and manner of death. Distinguishing between antemortem, perimortem and postmortem trauma', in *Forensic osteology. Advances in the identification of human remains*, ed. K.J. Reichs, Springfield, Illinois, 321–332.
- Sawyer, S., J. Krause, K. Guschanski, V. Savolainen & S. Pääbo 2012. 'Temporal patterns of nucleotide misincorporations and DNA fragmentation in ancient DNA', *PLoS ONE* 7, article ID e34131. <https://doi.org/10.1371/journal.pone.0034131>
- Scheuer, L. & S.M. Black 2000. *Developmental juvenile osteology*, San Diego, California. <https://doi.org/10.1016/b978-0-12-624000-9.x5000-x>
- Schmitt, H., E. Dubljanin, S. Schneider & M. Schiltenswolf 2004. 'Radiographic changes in the lumbar spine in former elite athletes', *Spine* 29:22, 2554–2559.
- Skoglund, P., B.H. Northoff, M.V. Shunkov, A.P. Derevianko, S. Pääbo, J. Krause & M. Jakobsson 2014. 'Separating endogenous ancient DNA from modern-day contamination in a Siberian Neandertal', *Proceedings of the National Academy of Sciences of the United States of America* 111, 2229–2234. <https://doi.org/10.1073/pnas.1318934111>
- Skoglund, P., J. Storå, A. Götherström & M. Jakobsson 2013. 'Accurate sex identification of ancient human remains using DNA shotgun sequencing', *JAS* 40, 4477–4482. <https://dx.doi.org/10.1016/j.jas.2013.07.004>
- Smith, C. 1884. 'Pyxis. Herakles and Geryon', *JHS* 5, 176–184. <https://doi.org/10.2307/623702>
- Spitz, W.U. & D.J. Spitz, eds. 1993<sup>3</sup>. *Spitz and Fisher's medico-legal investigation of death. Guidelines for the application of pathology to crime investigation*, Springfield, Illinois.
- Spradley, M.K. & R.L. Jantz 2011. 'Sex estimations in forensic anthropology. Skull versus postcranial elements', *Journal of Forensic Sciences* 56:2, 289–296. <https://doi.org/10.1111/j.1556-4029.2010.01635.x>
- Stewart, T.D. 1979. *Essentials of forensic anthropology especially as developed in the United States*, Springfield, Illinois.
- Stuart-Macadam, P. 1992. 'Anemia in past human populations', in *Diet, demography and disease. Changing perspectives on anemia*, eds. P. Stuart-Macadam & S. Kent, New York, 151–170.
- Svensson, E.M., C. Anderung, J. Baubliene, P. Persson, H. Malmström, C. Smith, M. Vretemark, L. Daugnorra & A. Götherström 2007. 'Tracing genetic change over time using nuclear SNPs in ancient and modern cattle', *Animal Genetics* 38:4, 378–383. <https://doi.org/10.1111/j.1365-2052.2007.01620.x>
- Symes, S.A., E.N. L'Abbé, K.E. Stull, M. Lacroix & J.T. Pokines 2014. 'Taphonomy and the timing of bone fractures in trauma analysis', in *Manual of forensic taphonomy*, eds. J.T. Pokines & S.A. Symes, Boca Raton, Florida, 341–366. <https://doi.org/10.1201/b15424-14>
- Ta'Ala, S.C., G.E. Berg. & K. Haden 2006. 'Blunt force trauma in the Cambodian Killing Fields', *Journal of Forensic Sciences* 51:5, 996–1001. <https://doi.org/10.1111/j.1556-4029.2006.00219.x>
- Thapliyal, G.K., R. Sinha, P.S. Menon & A. Chakranarayan 2008. 'Management of mandibular fractures', *Medical Journal Armed Forces India* 64:3, 218–220. [https://doi.org/10.1016/s0377-1237\(08\)80096-2](https://doi.org/10.1016/s0377-1237(08)80096-2)
- Trotter, M. 1970. 'Estimation in stature from intact long limb bones', in *Personal identification in mass disasters. Report of a seminar held in Washington, D.C., 9–11 December 1968, by arrangement between the Support Services of the Department of the Army and the Smithsonian Institution*, ed. T.D. Stewart, Washington, 71–84.
- Ubelaker, D.H. 1989<sup>2</sup>. *Human skeletal remains. Excavation, analysis, interpretation* (Manuals on Archaeology, 2), Washington, D.C.
- Ubelaker, D.H. & K.M. Montaperto 2014. 'Trauma interpretation in the context of biological anthropology', in *The Routledge handbook of the bioarchaeology of human conflict*, eds. C. Knüsel & M.J. Smith, Oxford & New York, 25–38. <https://doi.org/10.4324/9781315883366.ch2>

- Unnewher, M., C. Homann, P.F. Schmidt, P. Sotony, G. Fischer, B. Brinkmann, T. Bajanowski & A. DuChesne 2003. 'Fracture properties of the human mandible', *International Journal of Legal Medicine* 117:6, 326–330.
- Valavanis, P. 2010. 'Αθήνα', in *Αρχαία Αθήνα και Αττική. Ιστορική Τοπογραφία του Αστεως και της Χώρας*, ed. A.I. Vlachopoulos, Athens, 40–61.
- Vianello, D., F. Sevini, G. Castellani, L. Lomartire, M. Capri & C. Franceschi 2013. 'HAPLOFIND. A new method for high-throughput mtDNA haplogroup assignment', *Human Mutation* 34, 1189–1194. <https://doi.org/10.1002/humu.22356>
- Walker, P.L. 1995. 'Problems of preservation and sexism in sexing. Some lessons from historical collections for palaeodemographers', in *Grave reflections. Portraying the past through cemetery studies*, eds. S.R. Saunders & A. Herring, Toronto, 31–47.
- Walker, P.L., R.R. Bathurst, R. Richman, T. Gjerdrum & V.A. Andrushko 2009. 'The causes of porotic hyperostosis and cribra orbitalia. A reappraisal of the iron-deficiency-anemia hypothesis', *American Journal of Physical Anthropology* 139:2, 109–125. <https://doi.org/10.1002/ajpa.21031>
- Weiss, E. 2006. 'Osteoarthritis and body mass', *JAS* 33:5, 690–695. <https://doi.org/10.1016/j.jas.2005.10.003>
- Weiss, E. & R. Jurmain 2007. 'Osteoarthritis revisited. A contemporary review of aetiology', *International Journal of Osteoarchaeology* 17:5, 437–450. <https://doi.org/10.1002/oa.889>
- Weston, D.A. 2012. 'Nonspecific infections in palaeopathology. Interpreting periosteal reactions', in *A companion to paleopathology* (Blackwell Companions to Anthropology, 14), ed. A.L. Grauer, Chichester, West Sussex & Malden, Massachusetts, 492–512. <https://doi.org/10.1002/9781444345940.ch27>
- White, T.D. 1991. *Human osteology*, San Diego.
- White, T.D., M.T. Black & P.A. Folkens 2012<sup>3</sup>. *Human osteology*, Amsterdam & London. <https://doi.org/10.1016/C2009-0-03221-8>
- Yang, D.Y., B. Eng, J.S. Waye, J.C. Dudar & S.R. Saunders 1998. 'Technical note. Improved DNA extraction from ancient bones using silica-based spin columns', *American Journal of Physical Anthropology* 105:4, 539–543. [https://doi.org/10.1002/\(sici\)1096-8644\(199804\)105:4<539::aid-ajpa10>3.3.co;2-2](https://doi.org/10.1002/(sici)1096-8644(199804)105:4<539::aid-ajpa10>3.3.co;2-2)